

Thorax dissection visual manual

By Enam ul Haq Moneeb, MD.

داکتر انعام الحق "منیب"

Kabul Medical University, Dept. of Anatomy, Afghanistan
Leiden University Medical Center (LUMC), Dept. Anatomy & Embryology,
Netherlands

in collaboration with

Paul Gobée, MD, LUMC, Dept. Anatomy & Embryology

Egbert Lakke, MD, PhD, LUMC, Dept. Anatomy & Embryology

Prof. Marco de Ruiter, PhD, LUMC, Dept. Anatomy & Embryology

Last update 11 May 2018, by Paul Gobée

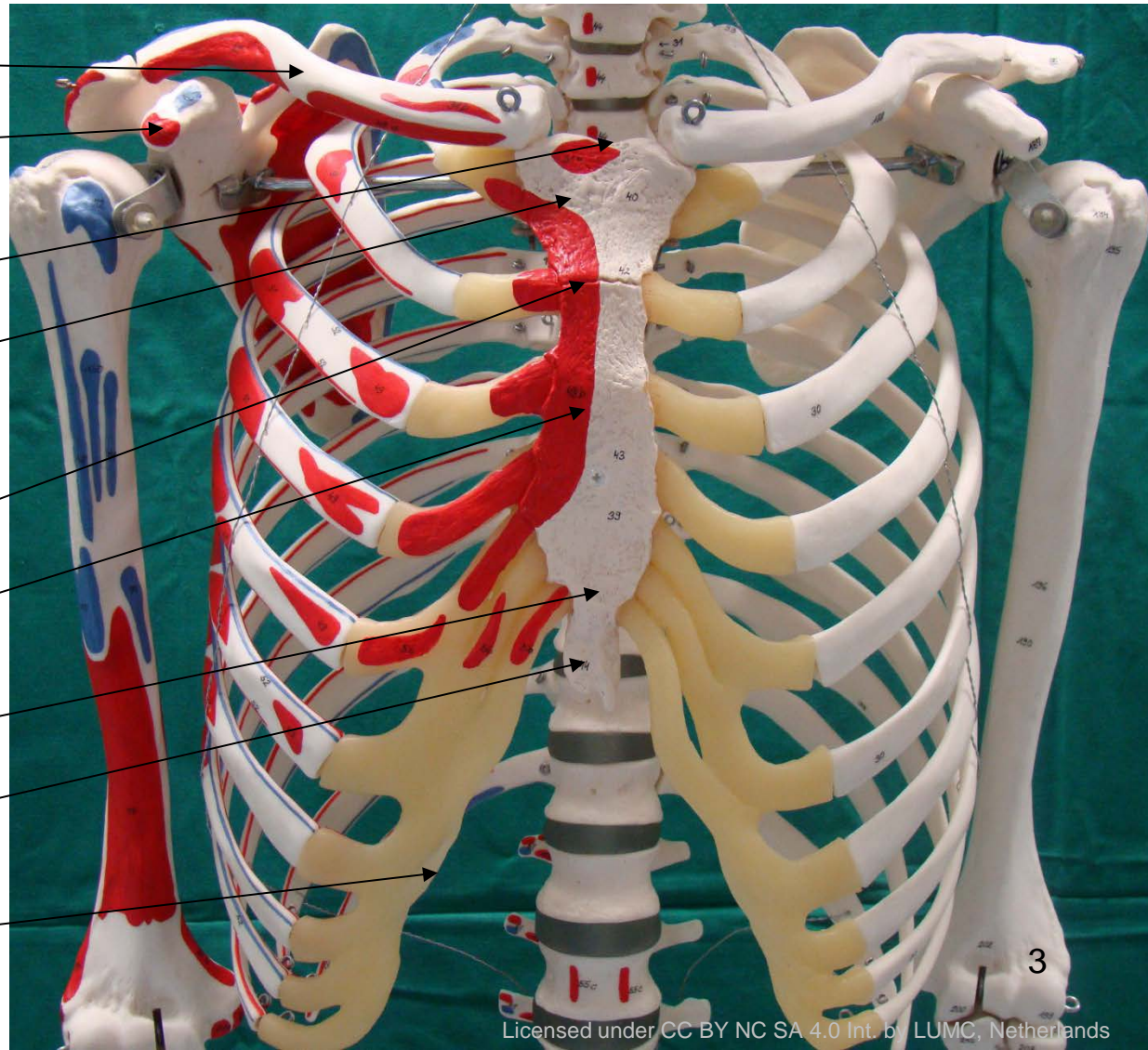


This presentation is licensed under Creative Commons Attribution-NonCommercial-ShareAlike 4.0 International by LUMC, Netherlands

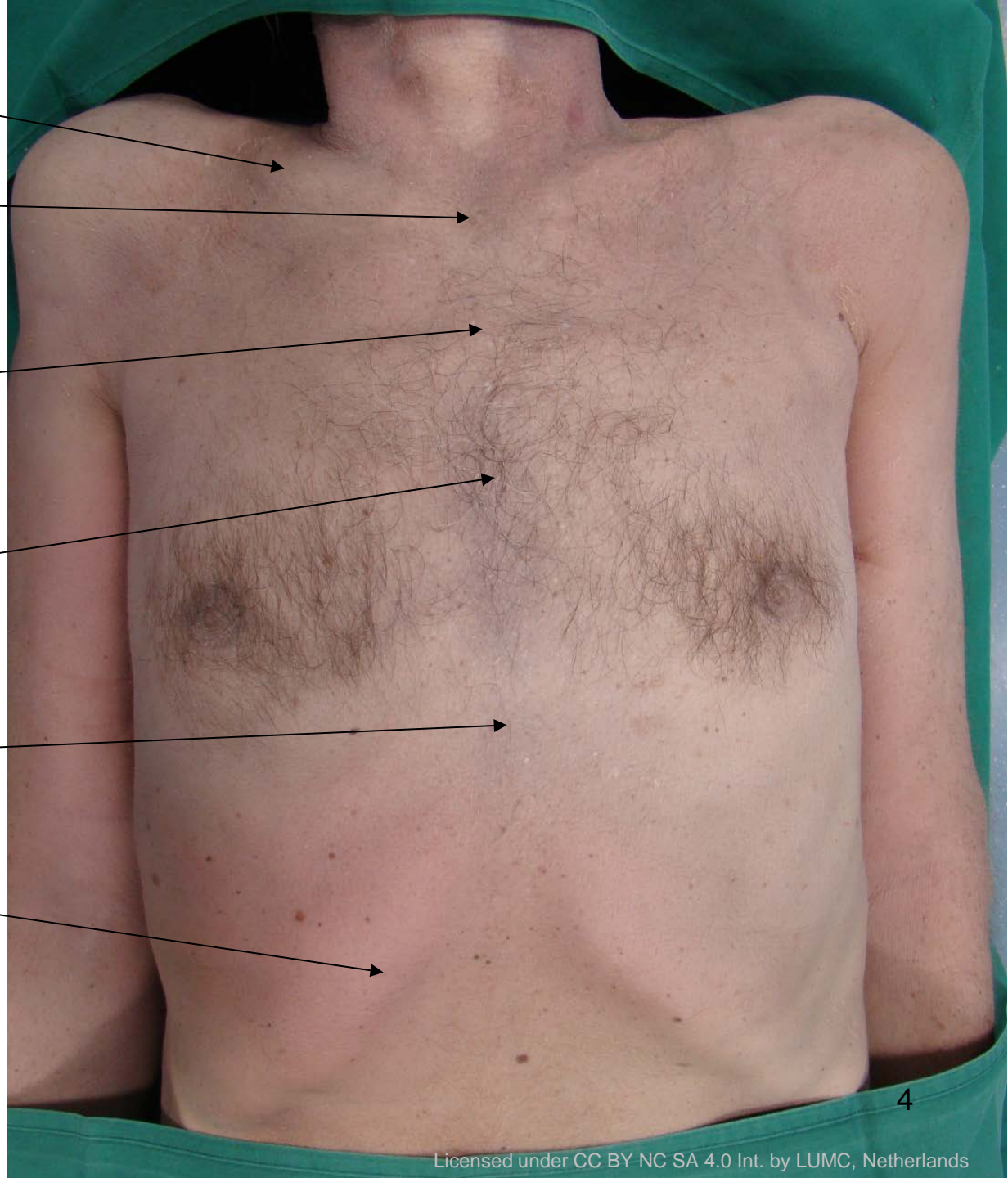

Dissection and opening anterior thoracic wall

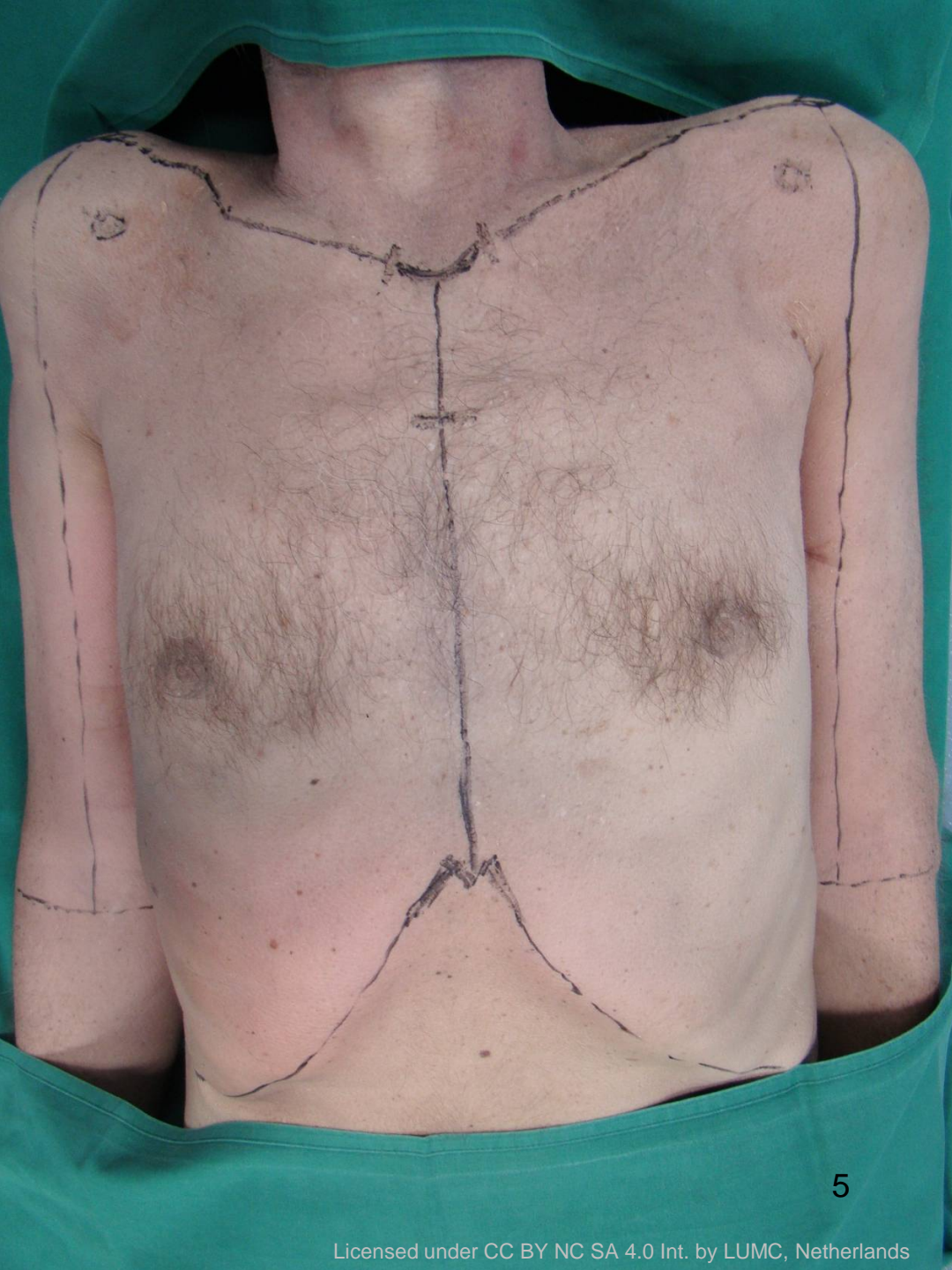
- Clavicle
- Coracoid
- Jugular or (supra)sternal notch
- Manubrium
- Sternal angle (Ludovicii)
- Body of the sternum
- Xiphisternal junction
- Xiphoid process
- Costal margin



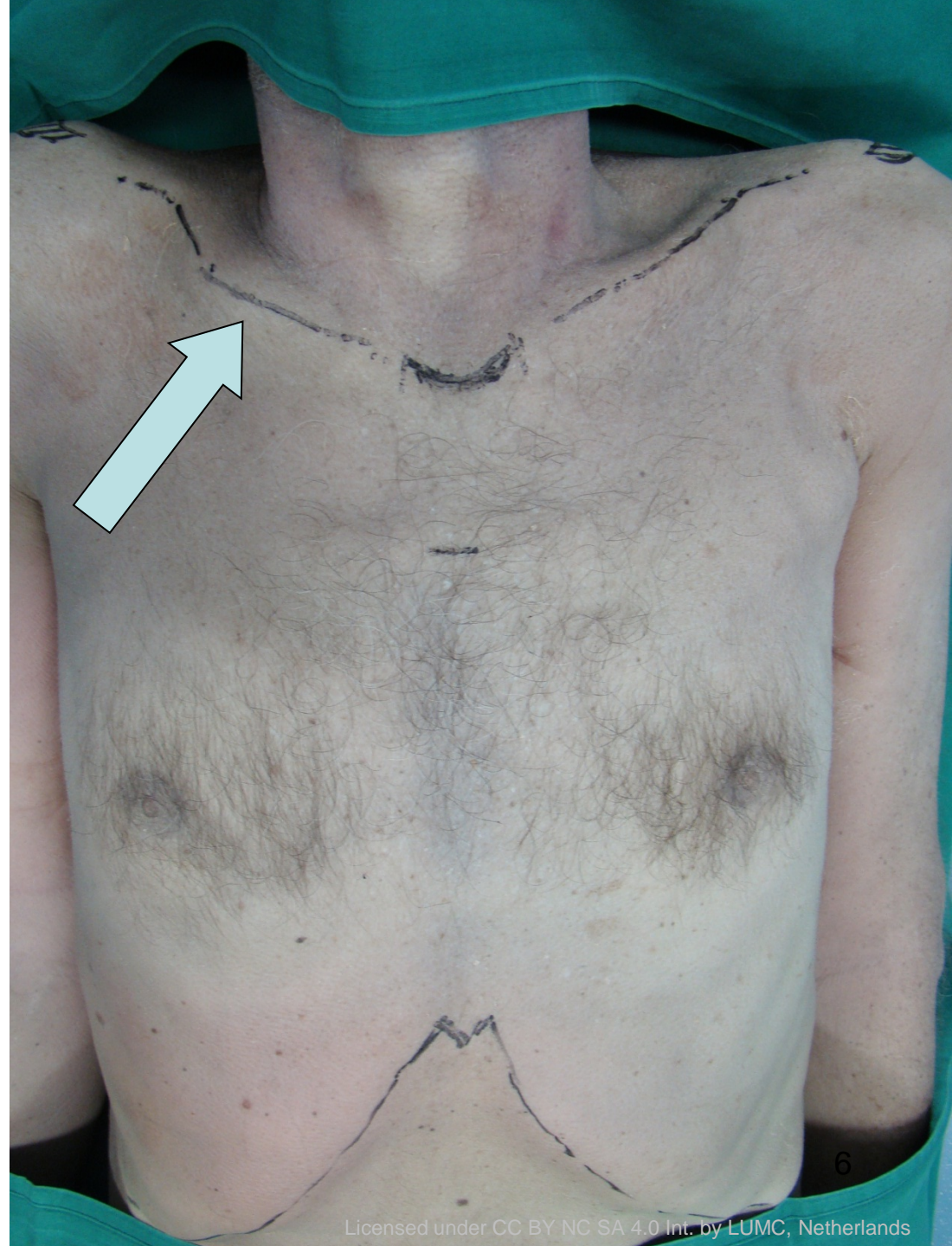
- Clavicle
- Jugular or (supra) sternal notch
- Sternal angle or Louis angle
- Body of sternum
- Xiphoid process
- Costal margin



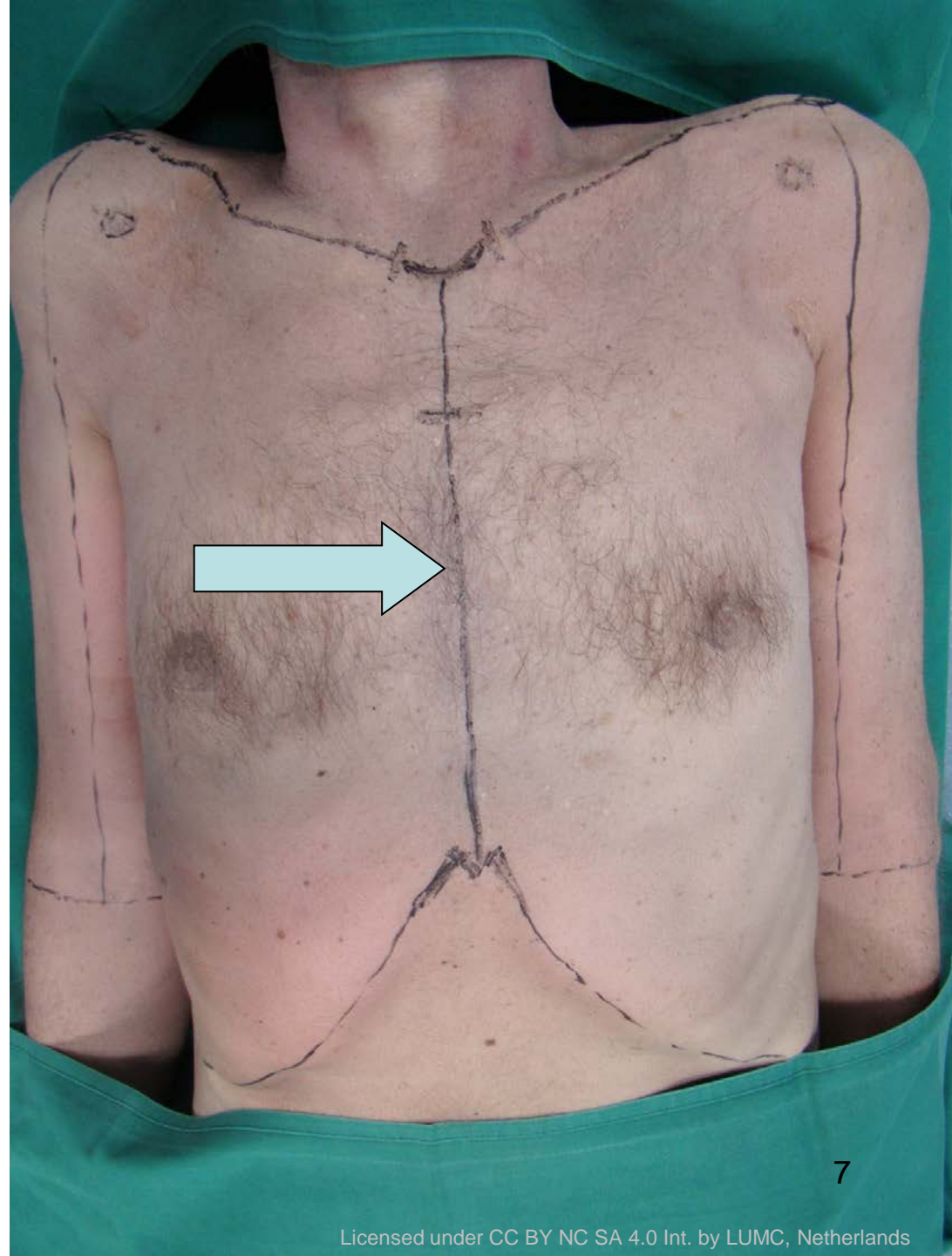
The picture shows the landmarks for the skin incision



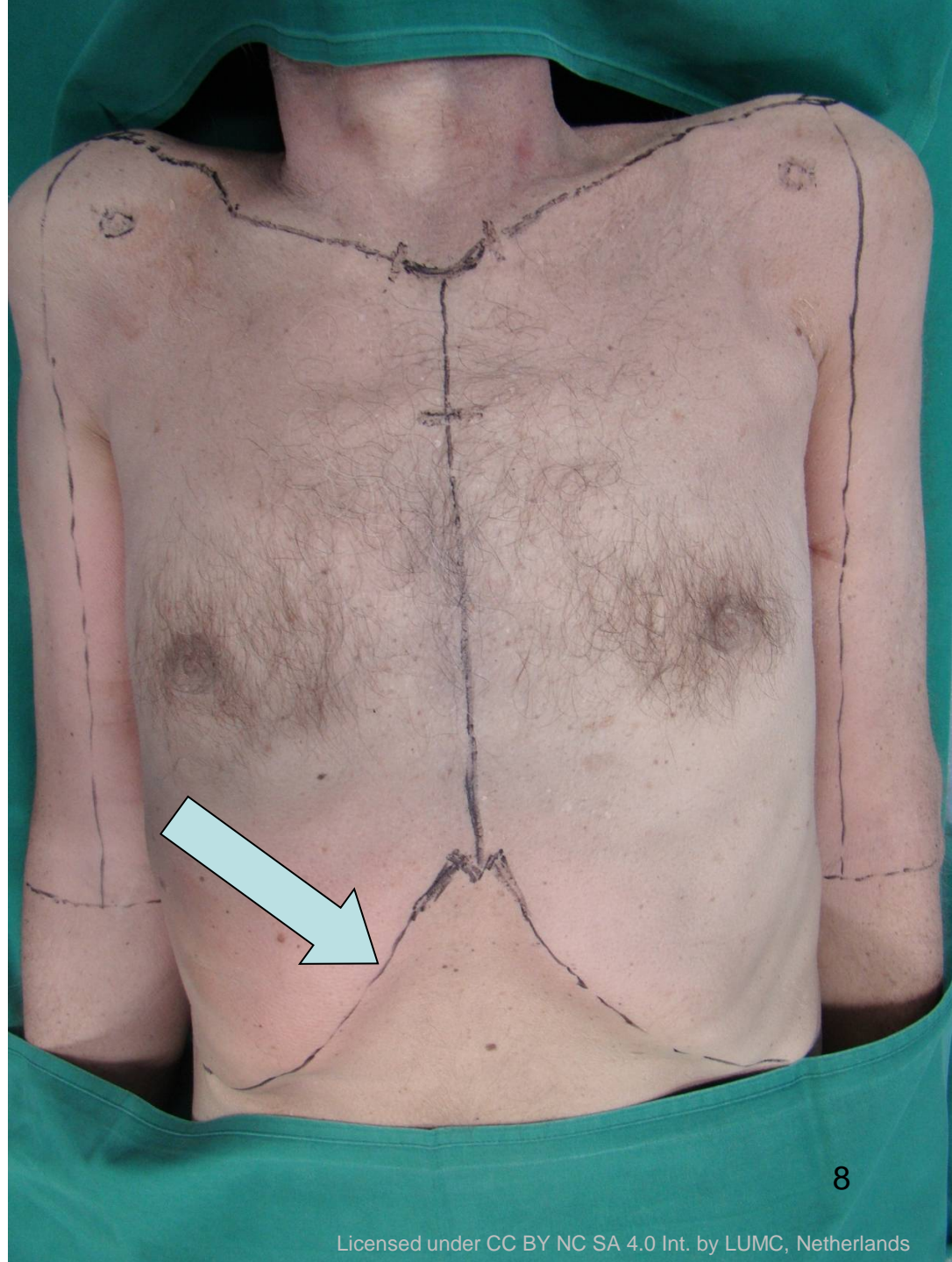
incision from jugular
(suprasternal) notch to
acromion over the
clavicle



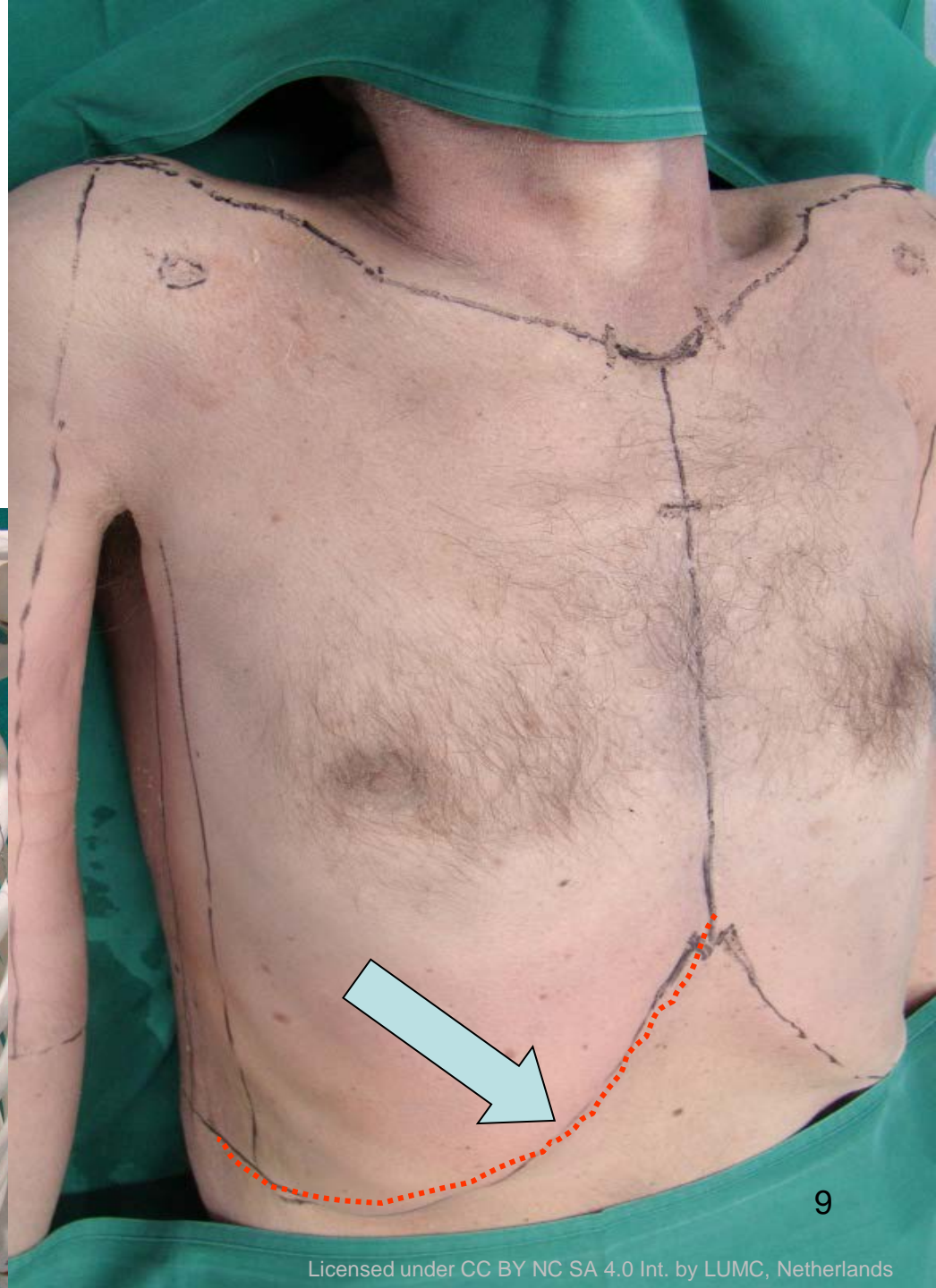
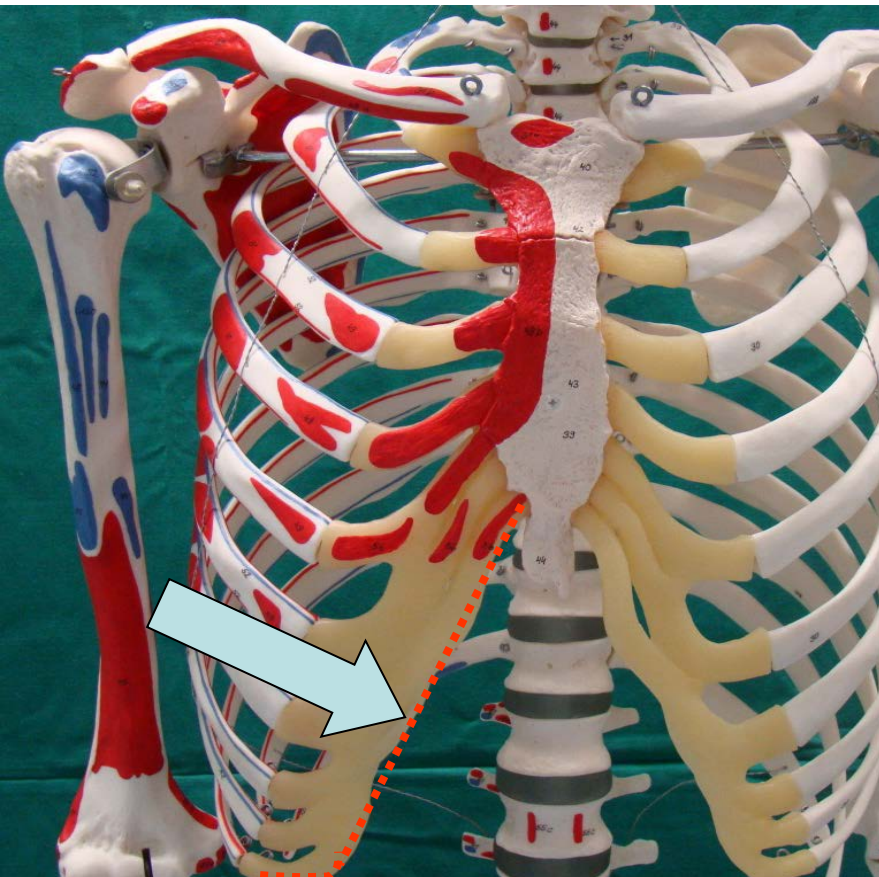
incision line from jugular
(suprasternal) notch to
xiphoid process



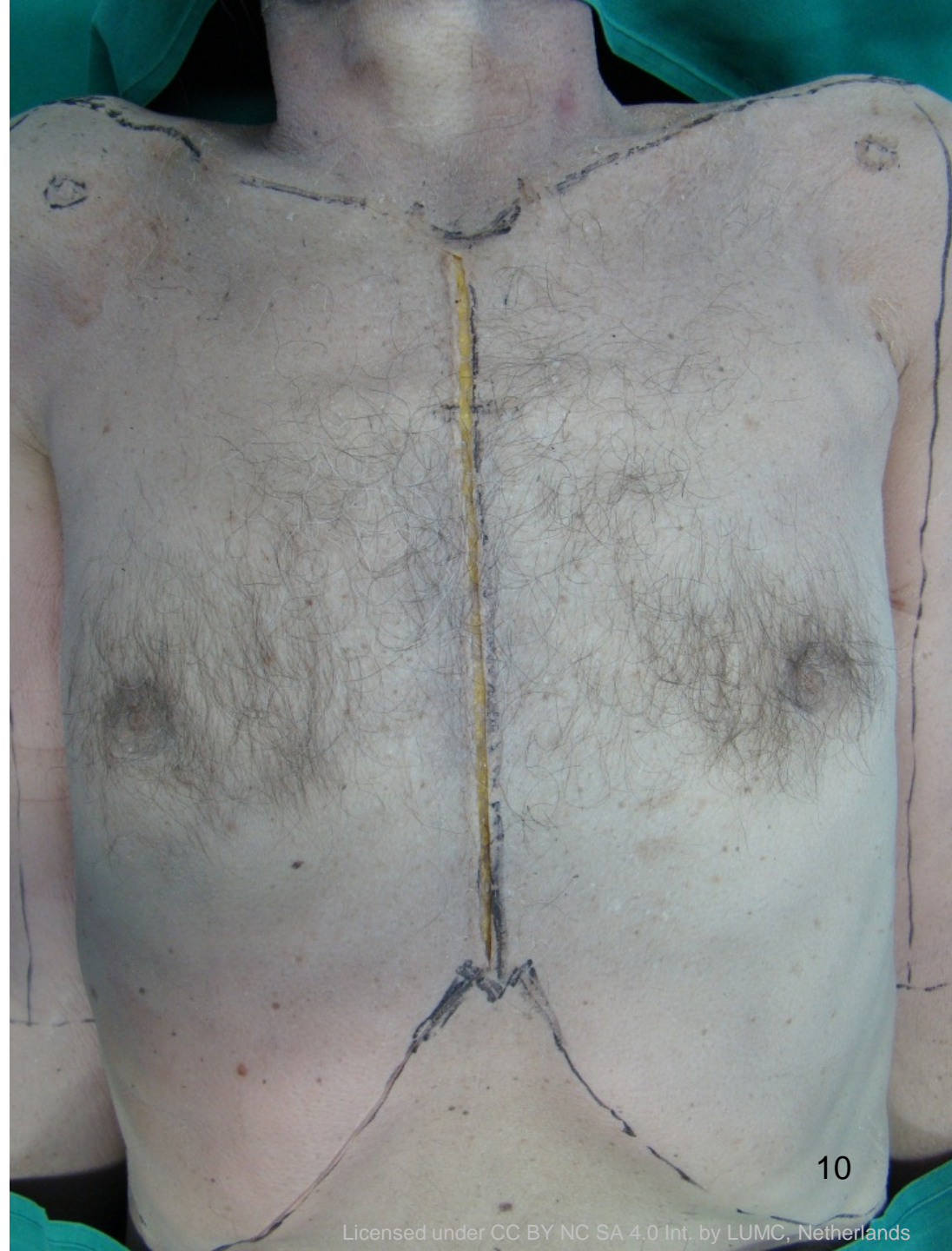
incision line from xiphoid process along the costal margin to mid-axillary line



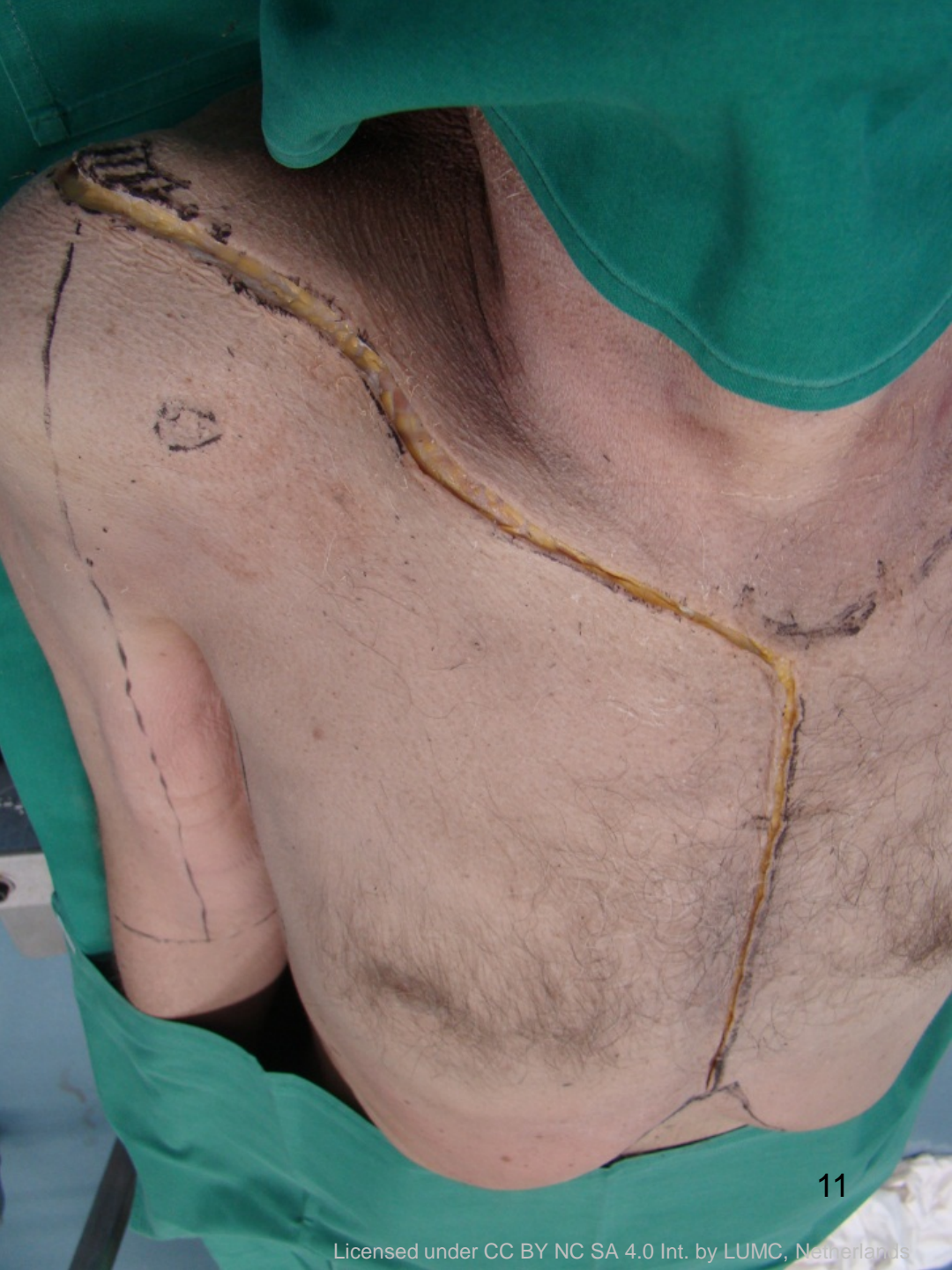The costal margin



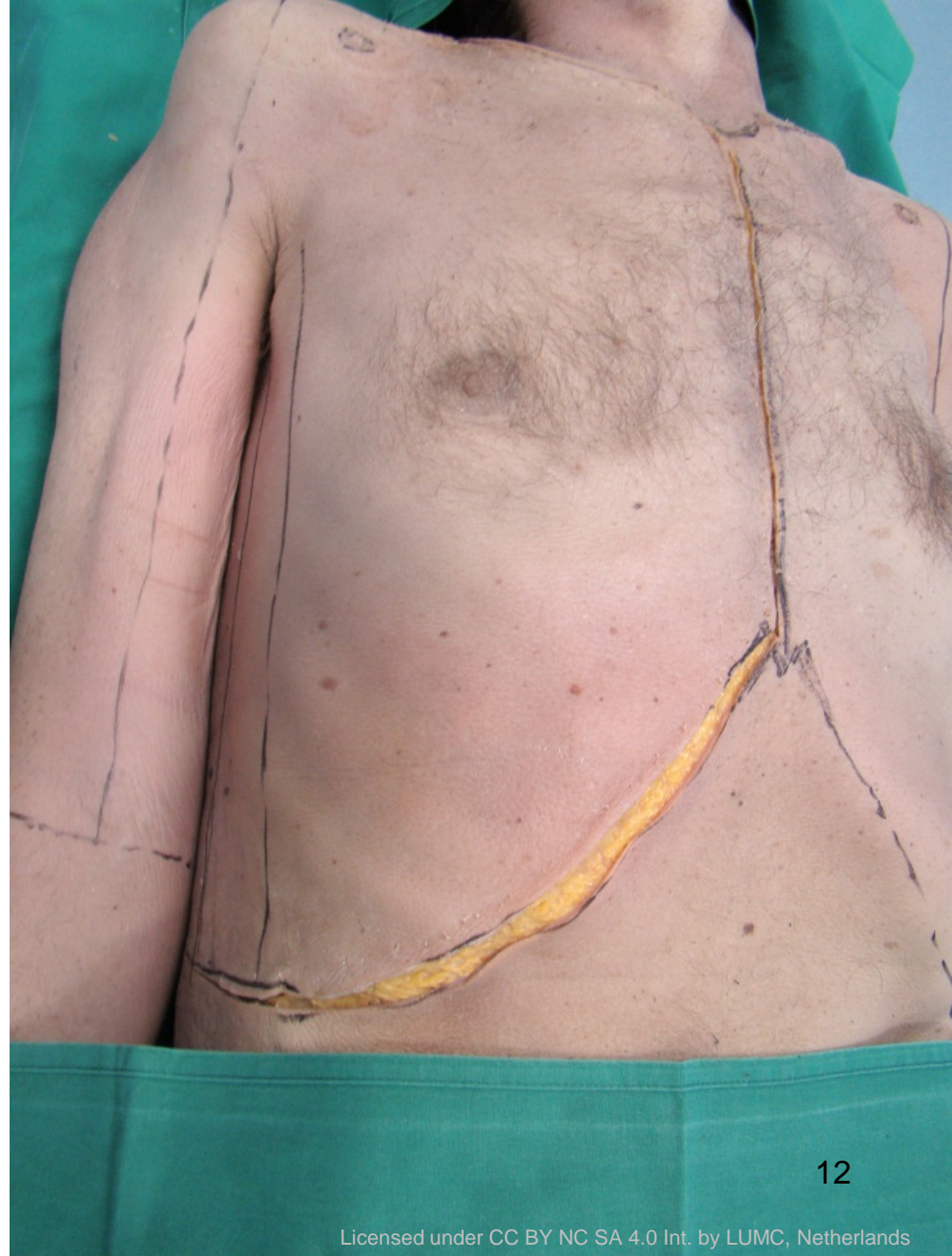
vertical incision over
the sternum



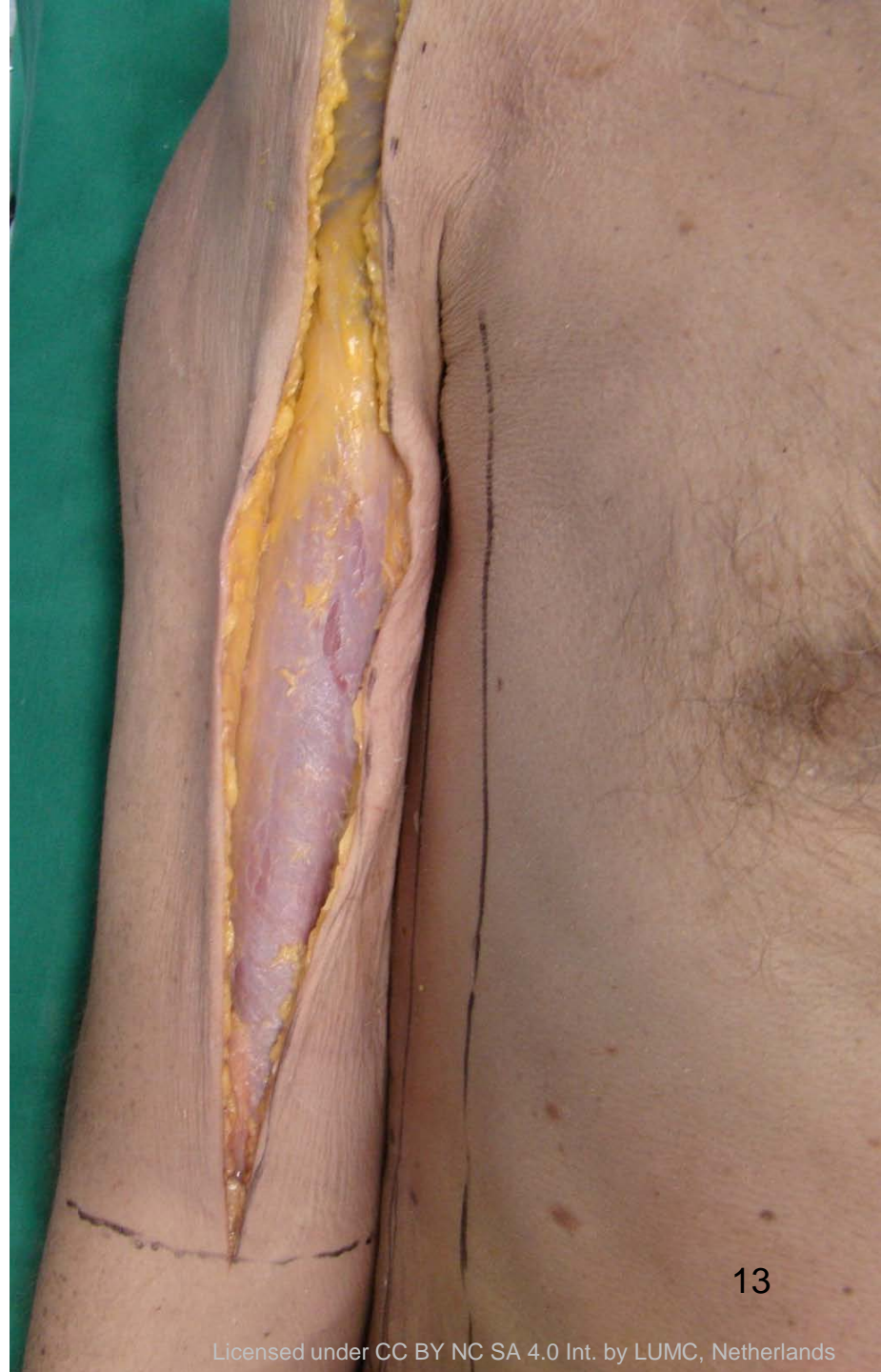horizontal incision over
the clavicle



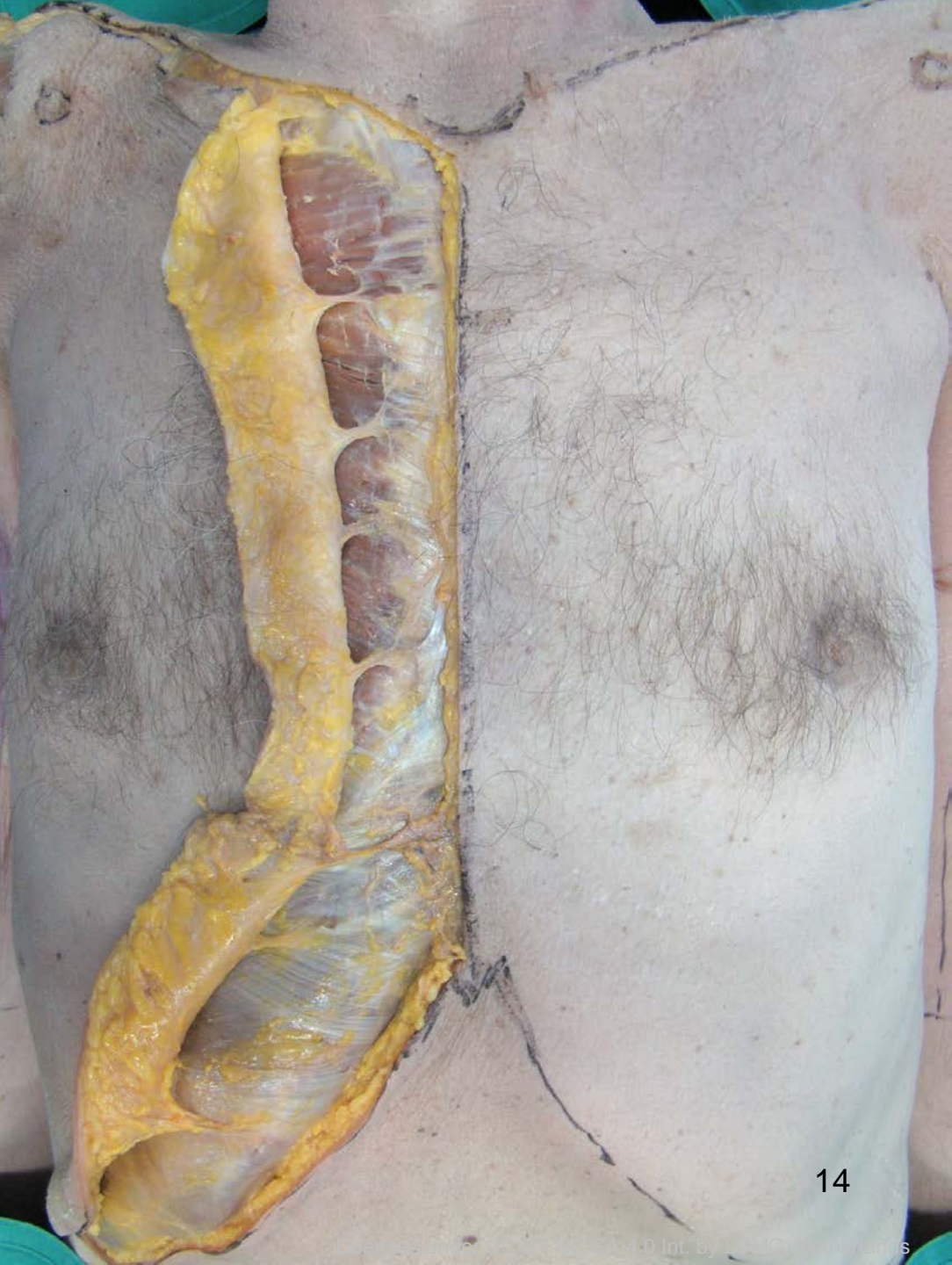an incision along
the costal arch
(arcus costalis)



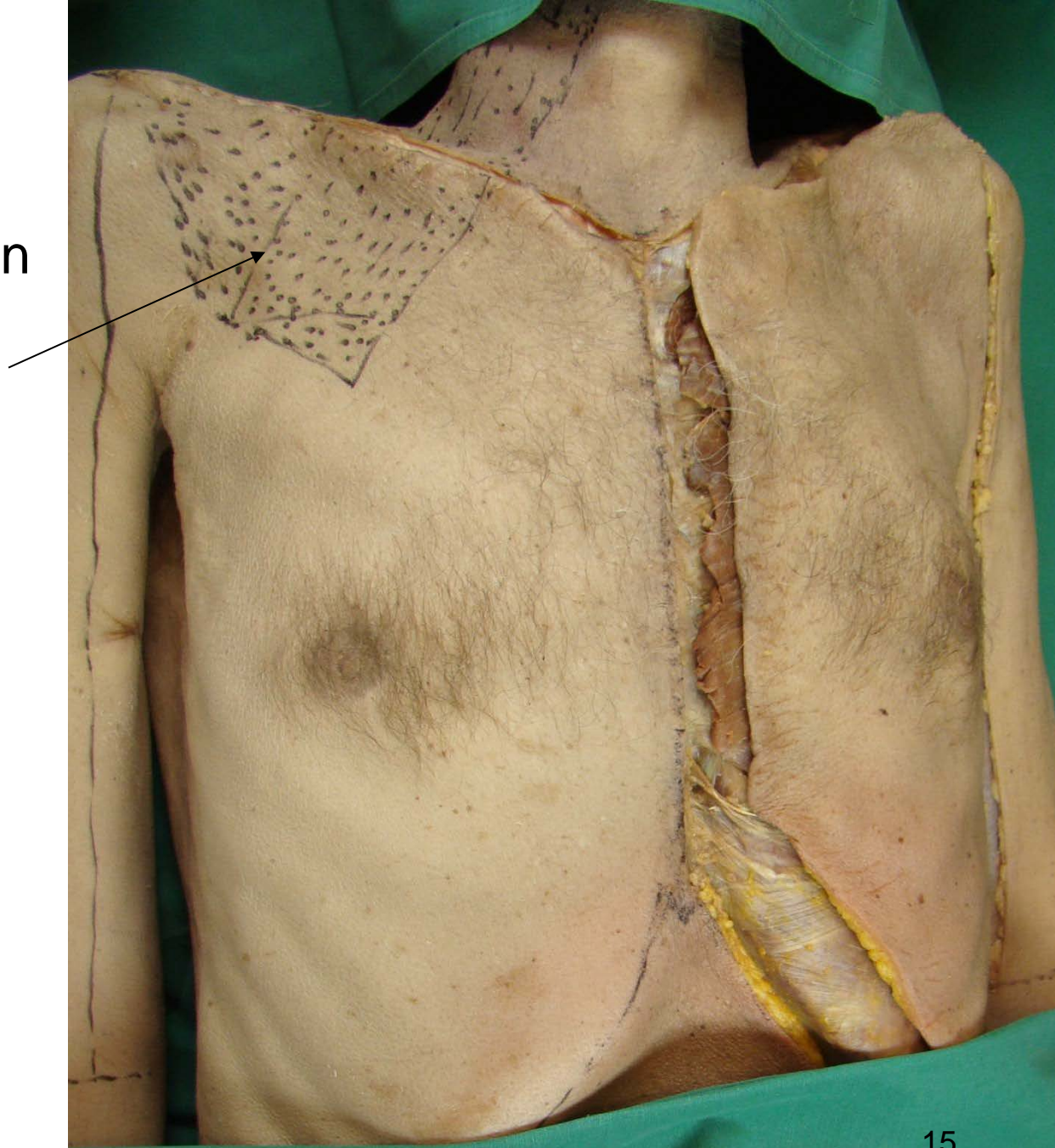
vertical incision from
the acromion over the
arm



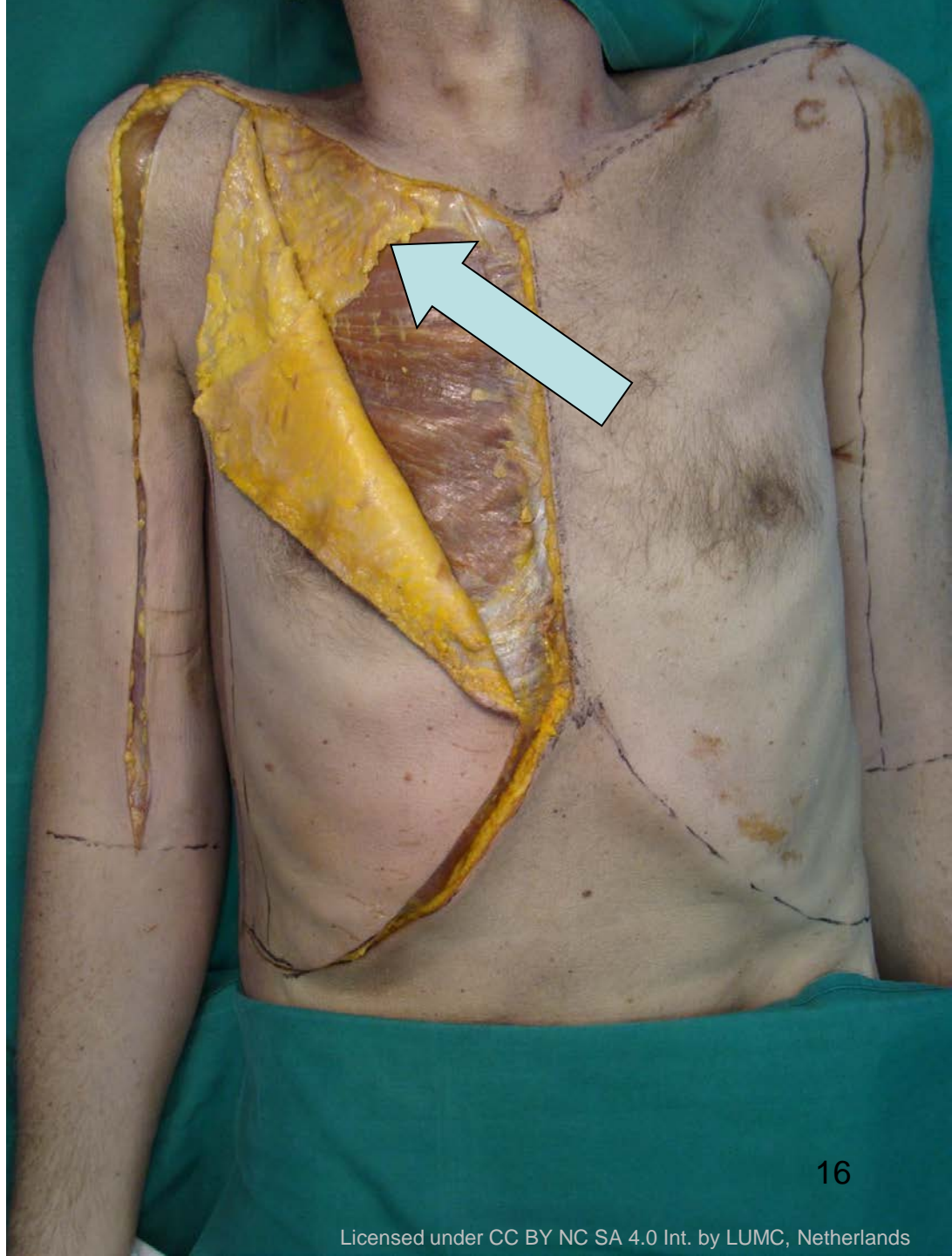anterior intercostal
cutaneous nerves



Platysma muscle
location indicated on
the skin

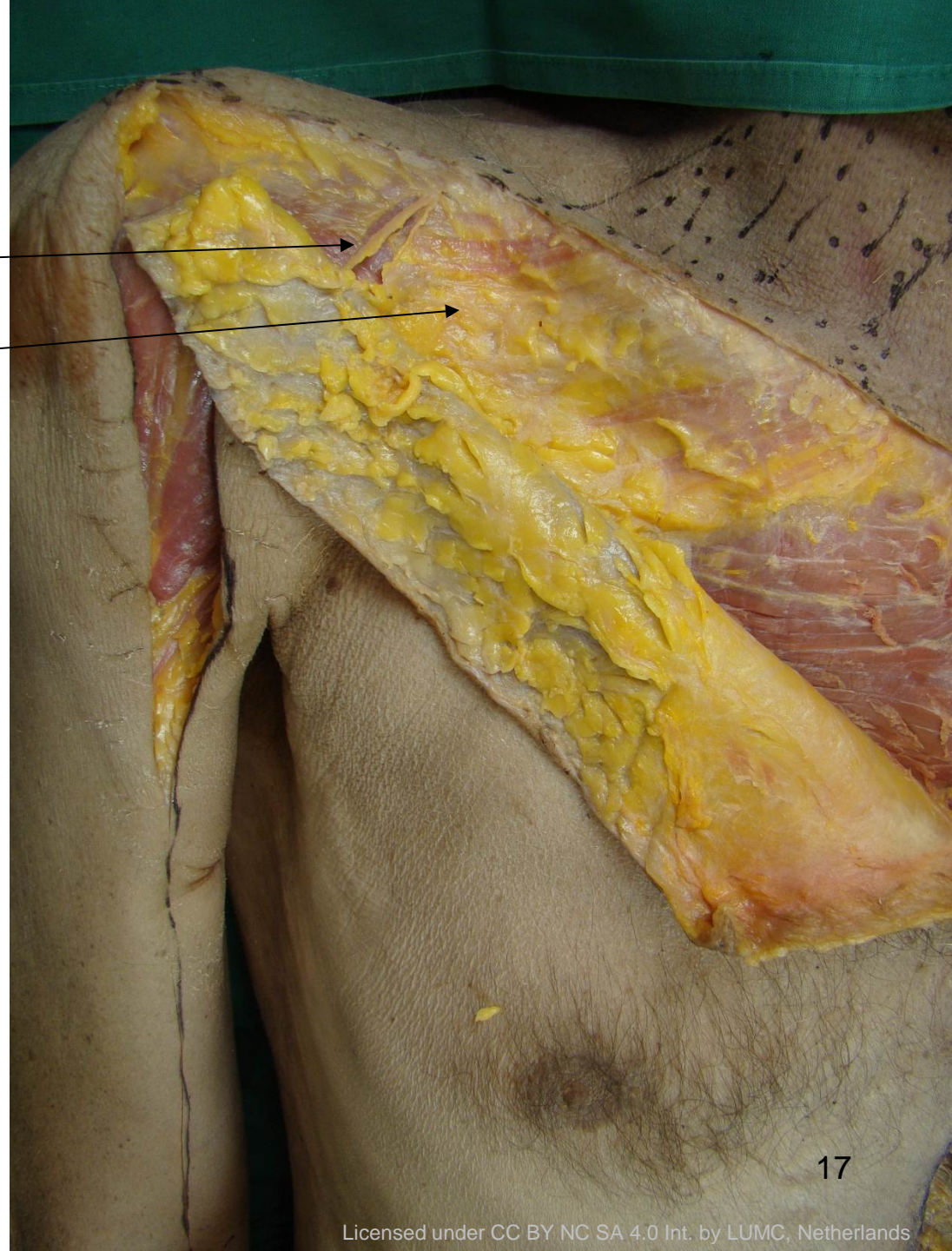

Platysma muscle in the superficial fascia

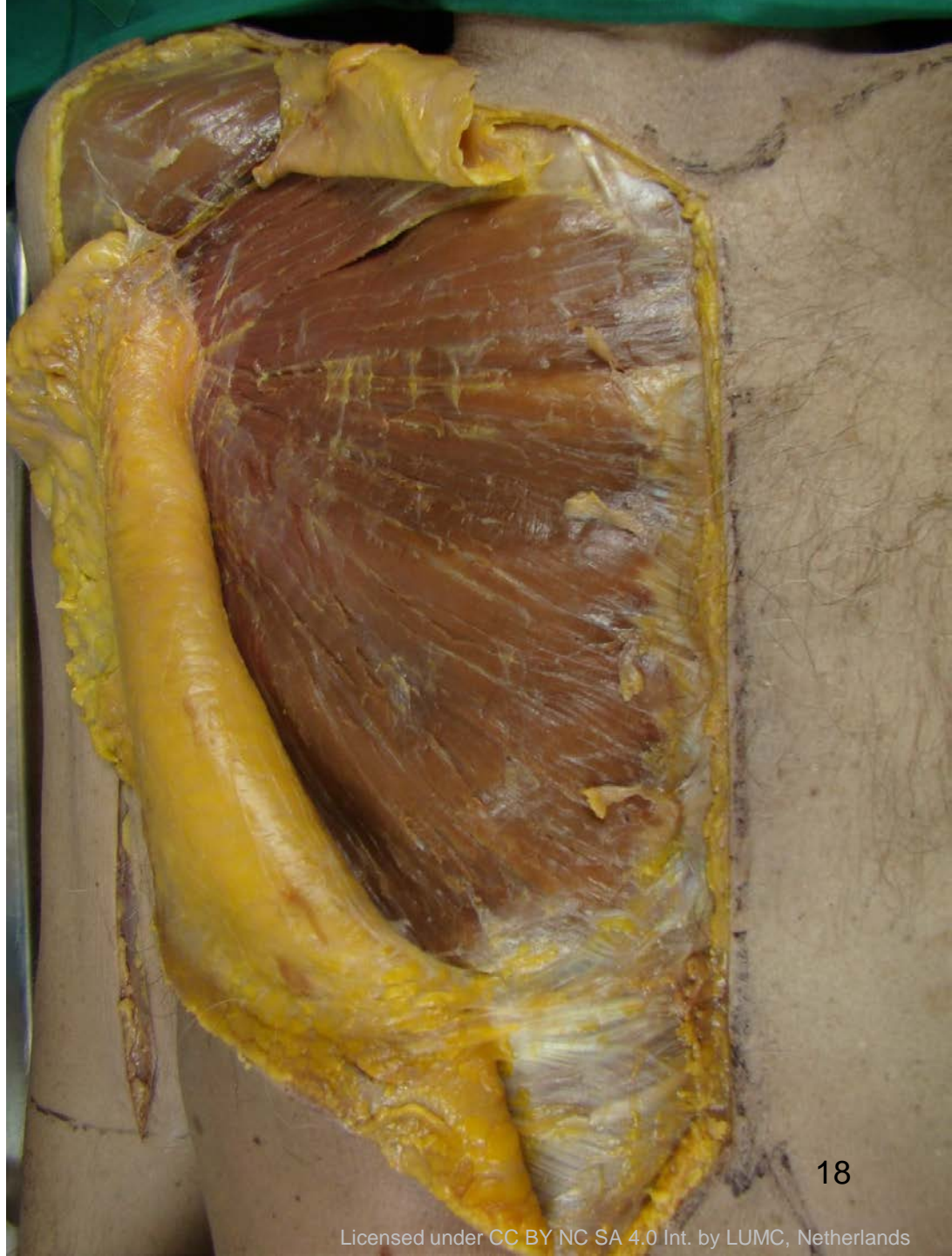

Supraclavicular nerve

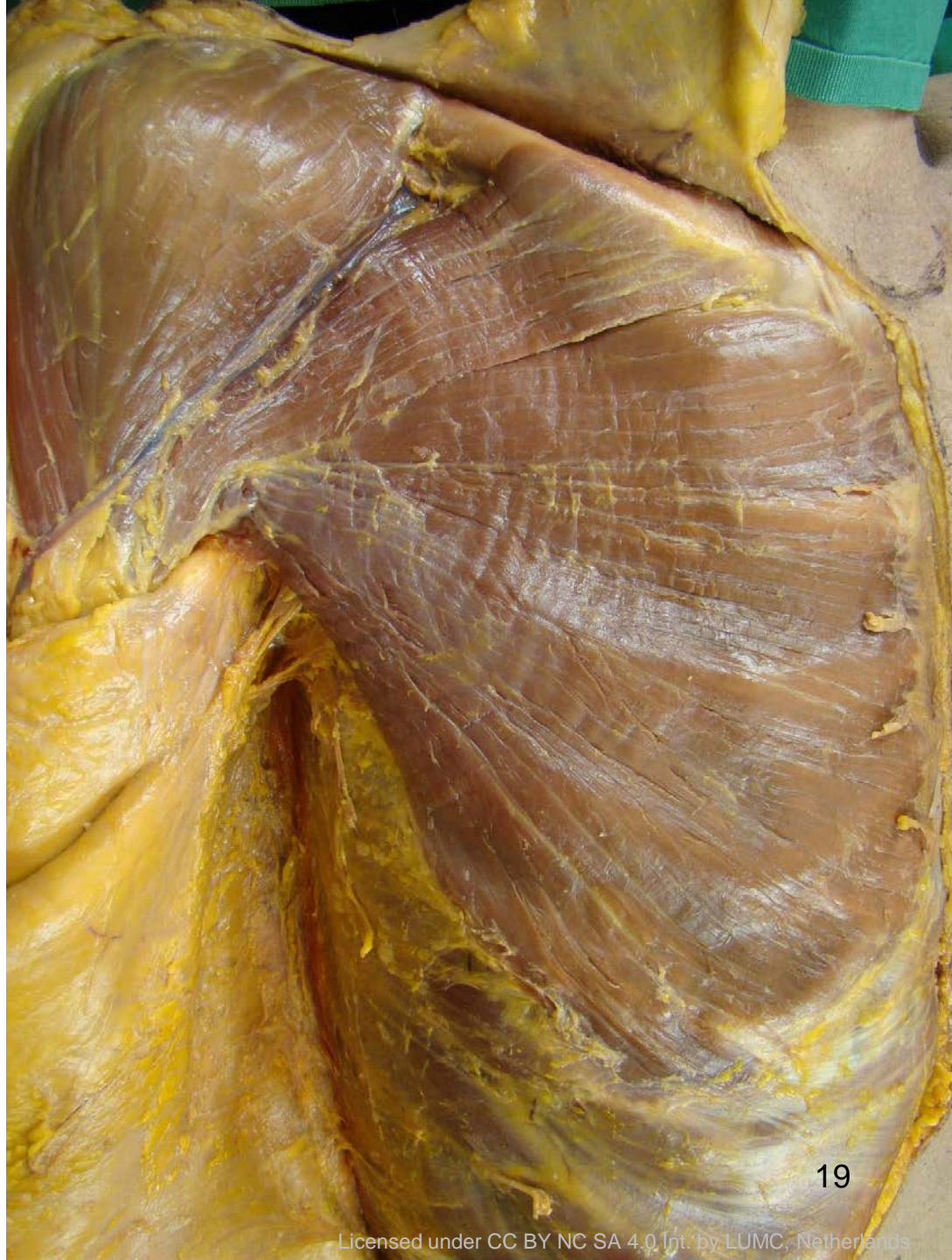Platysma muscle



Skin and superficial fascia
including platysma
muscle are removed



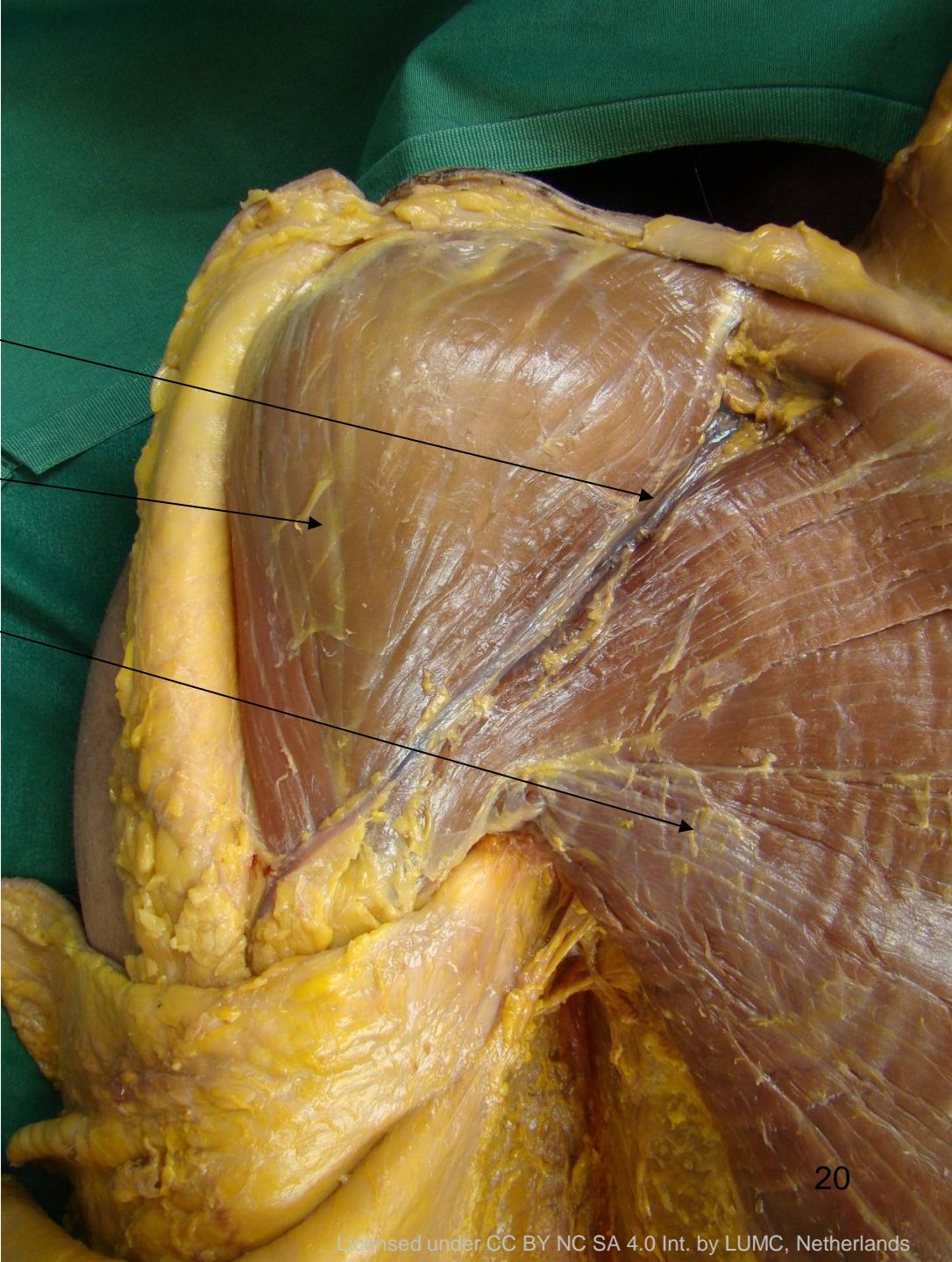
Pectoralis major muscle and its borders



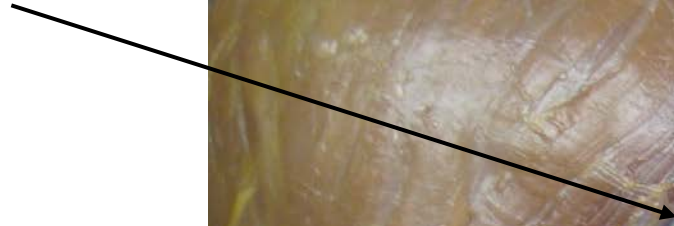Deltopectoral sulcus

Deltoid muscle

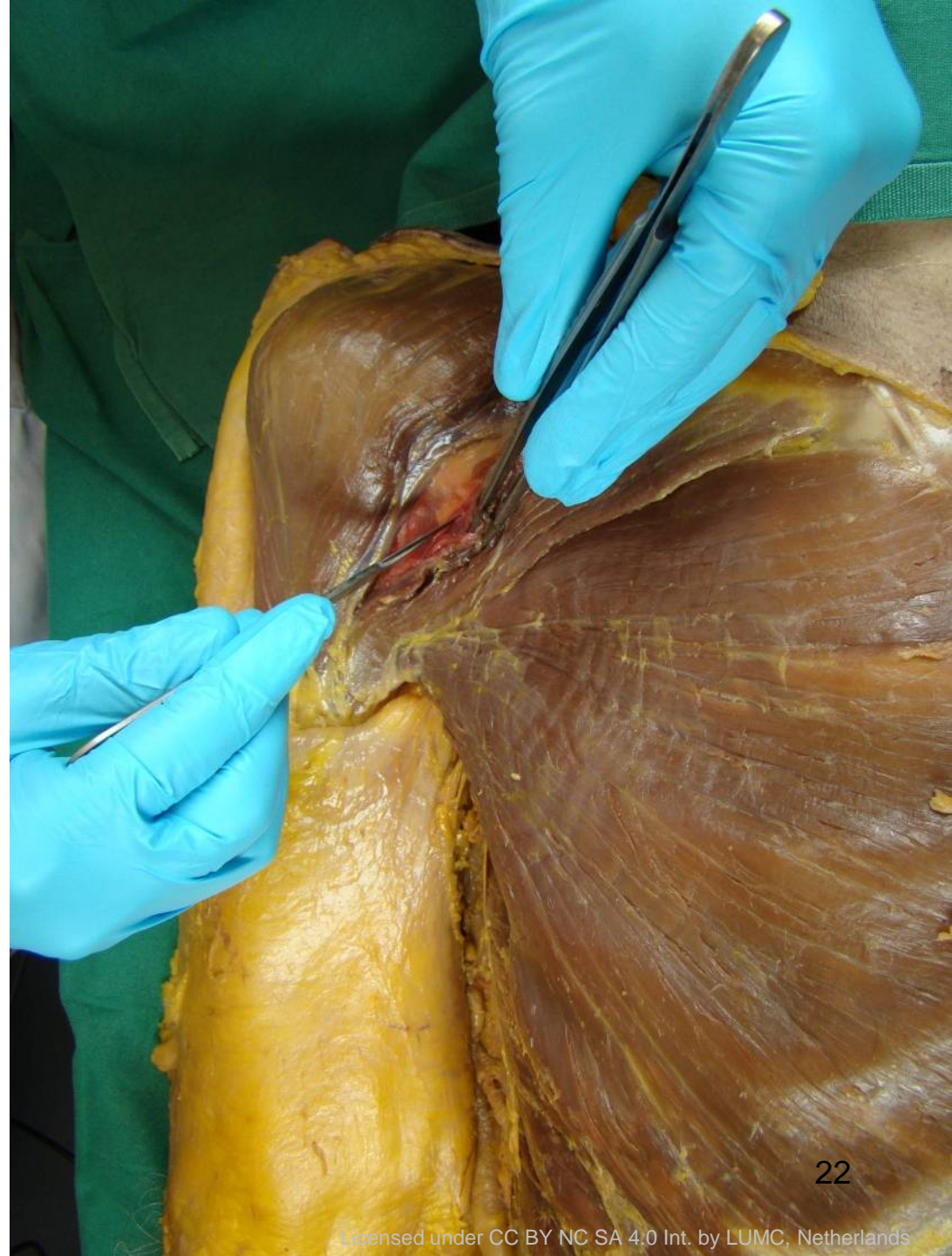Pectoralis major muscle



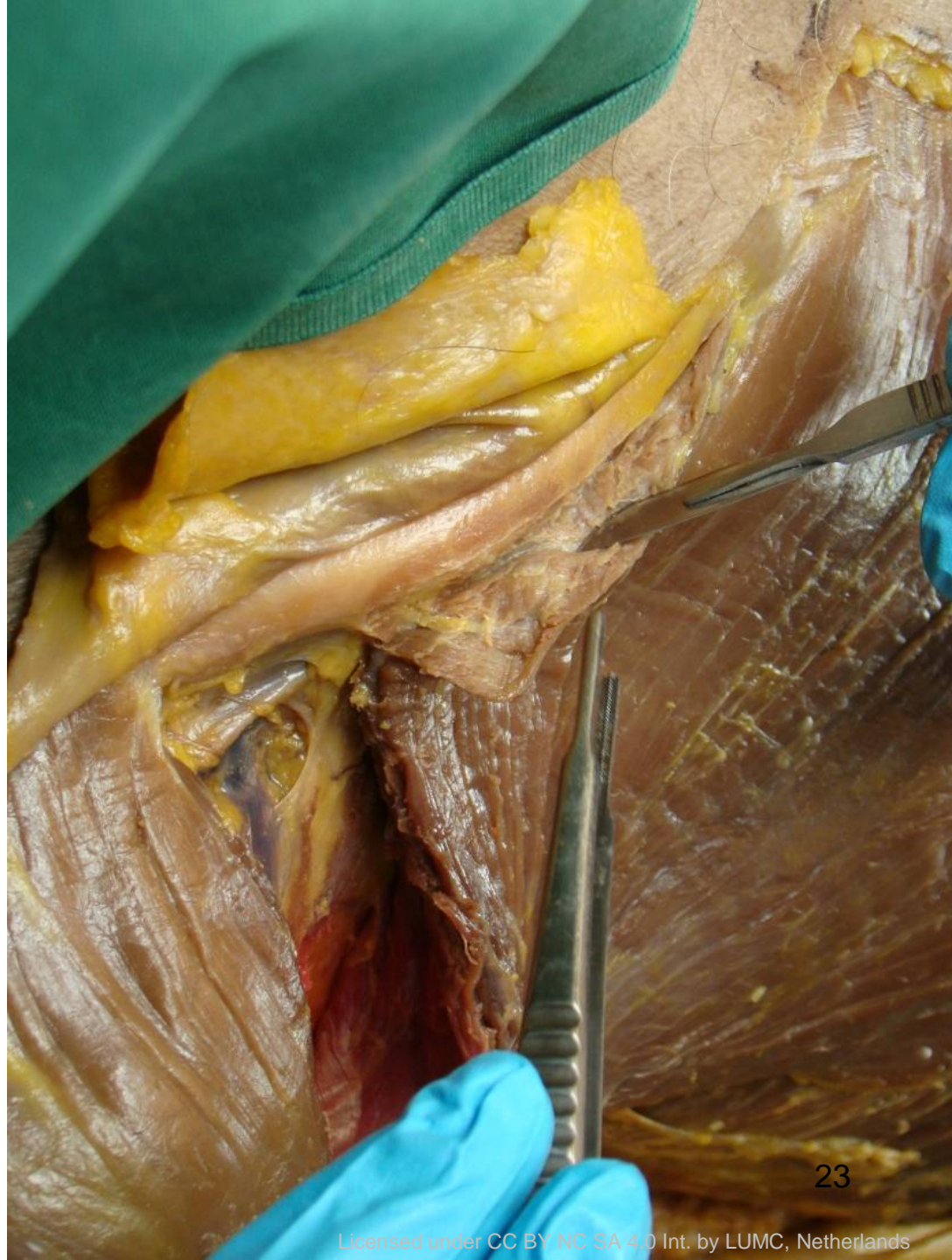
Cephalic vein



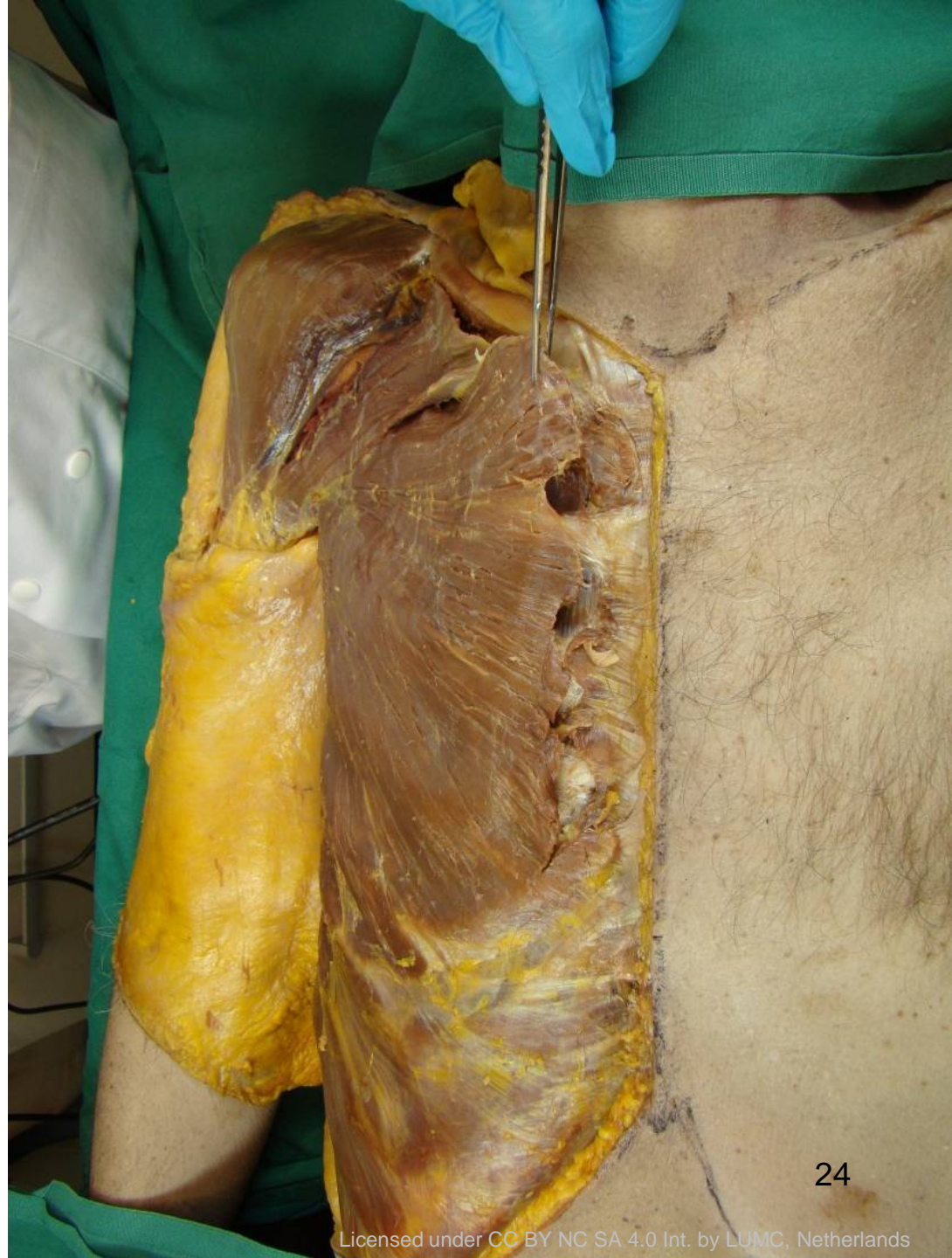Dissecting pectoralis
major muscle from
deltopectoralis sulcus



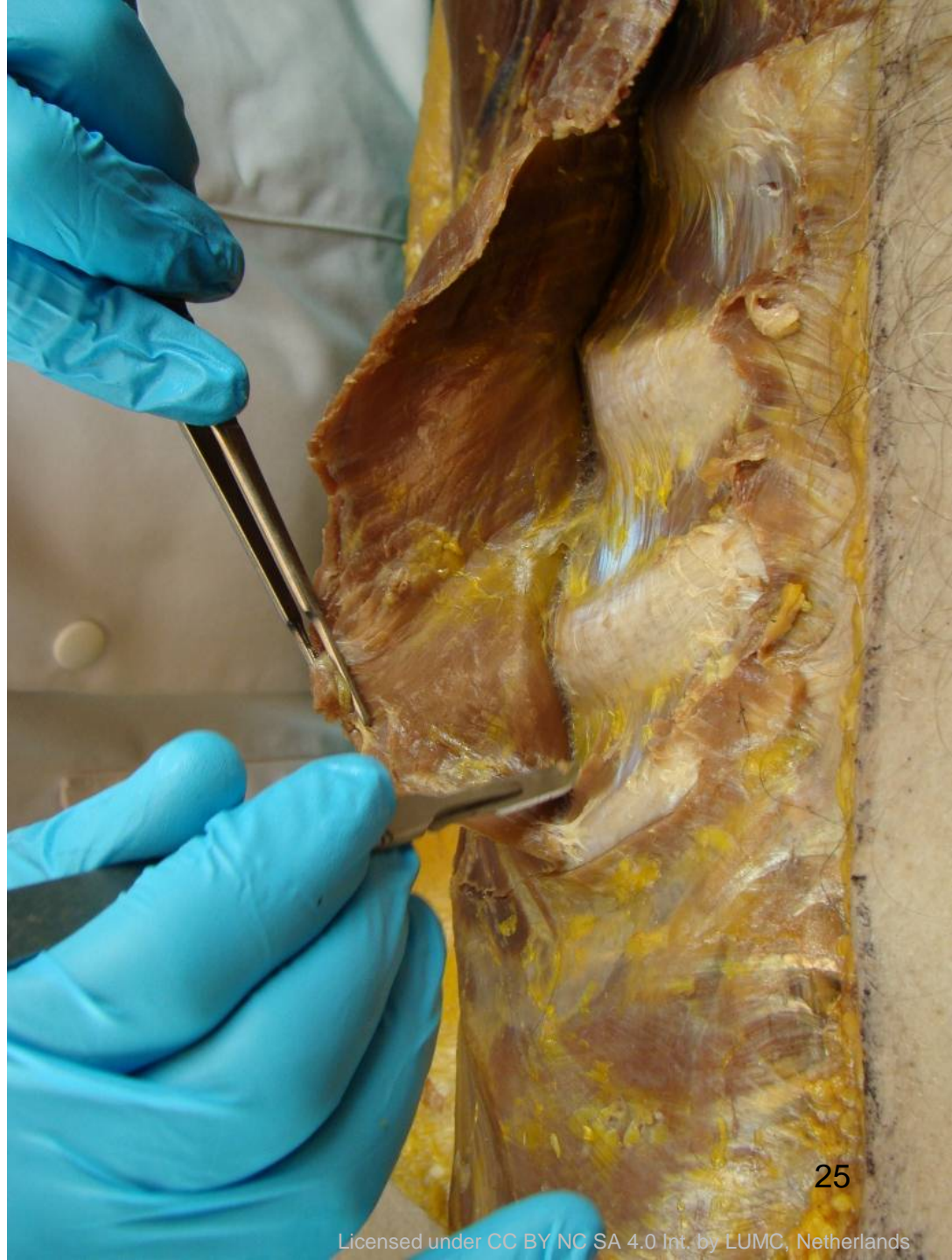Dissecting pectoralis major muscle attachment from clavicle



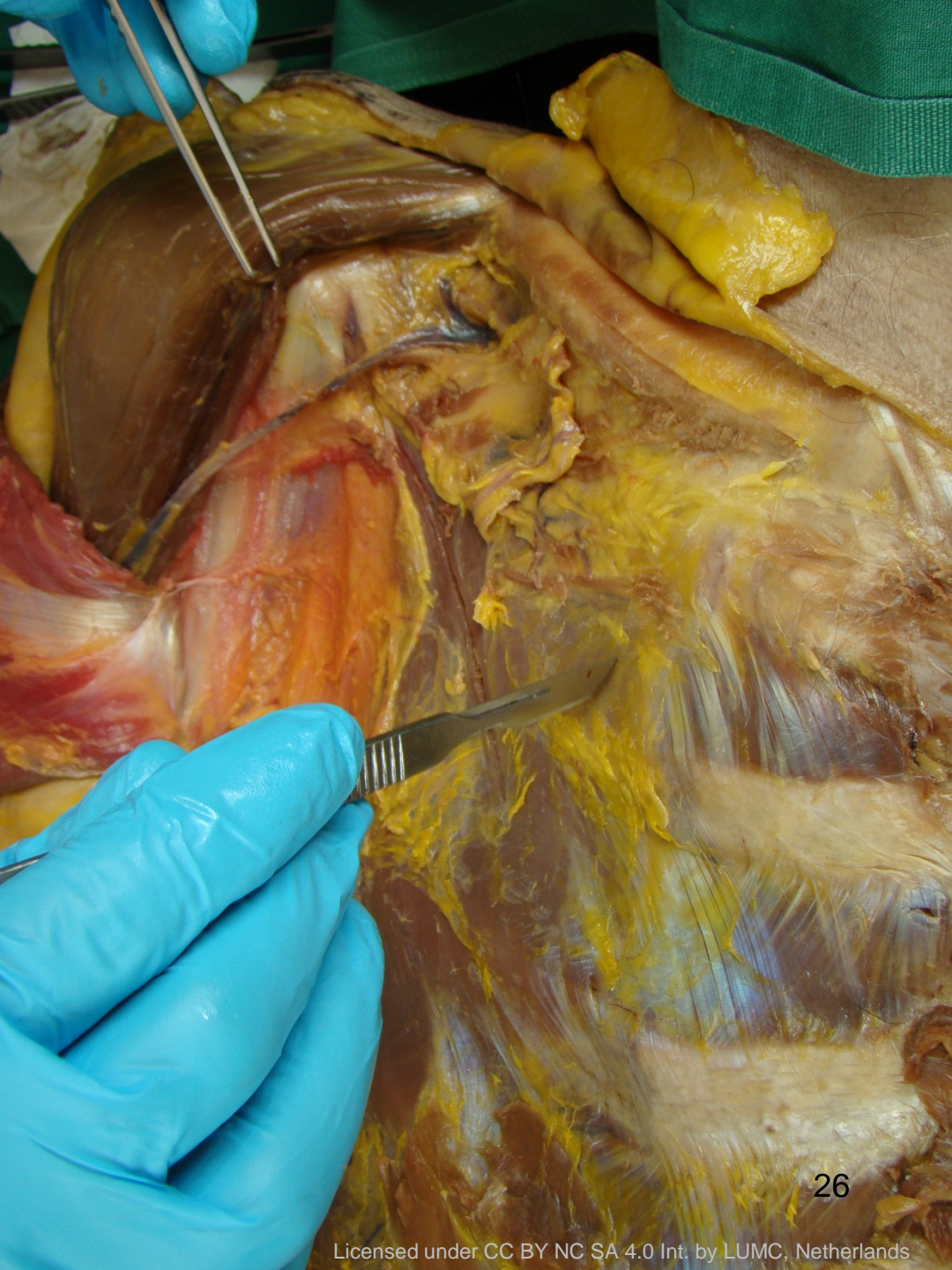Dissecting pectoralis major muscle from the ribs



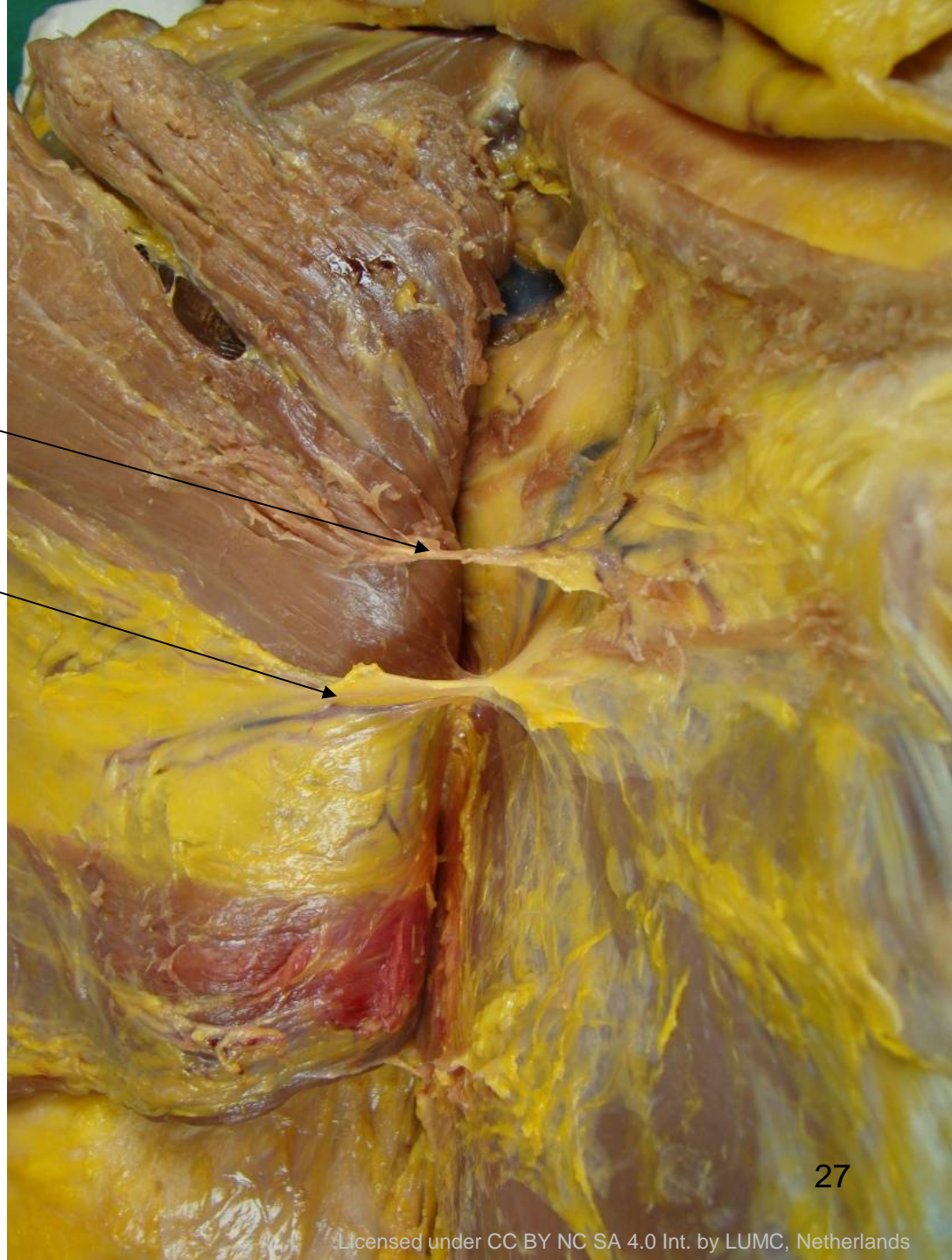Detaching
pectoralis major
muscle from the
ribs



Clavipectoral fascia opening



- Lateral pectoral nerve
- Medial pectoral nerve



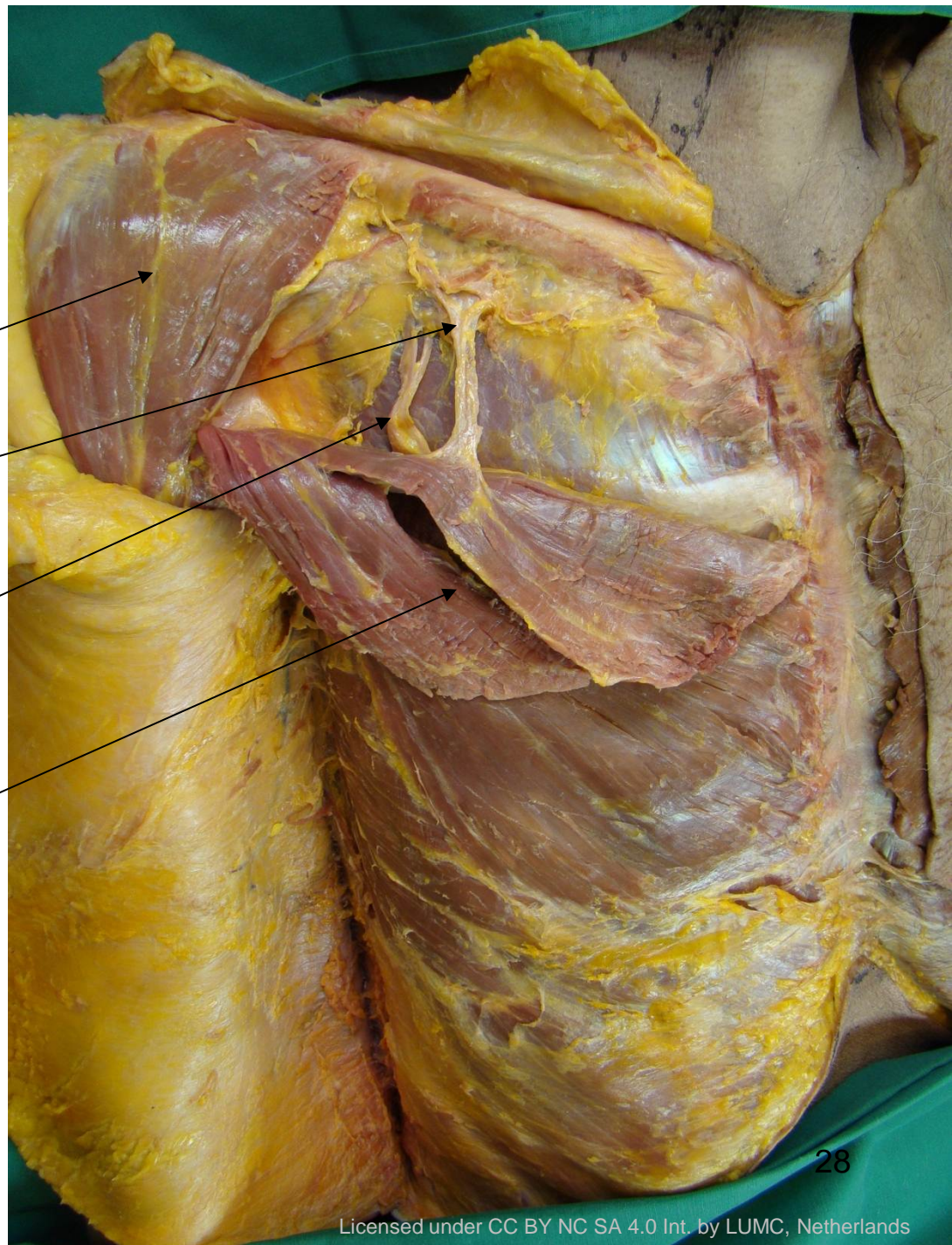Deltoid muscle

Lateral* pectoral
nerve

Medial* pectoral
nerve

Pectoralis major
muscle

* Note! Confusing! The medial pectoral nerve is named so because it arises from the medial cord, but it is lateral to the lateral pectoral nerve.

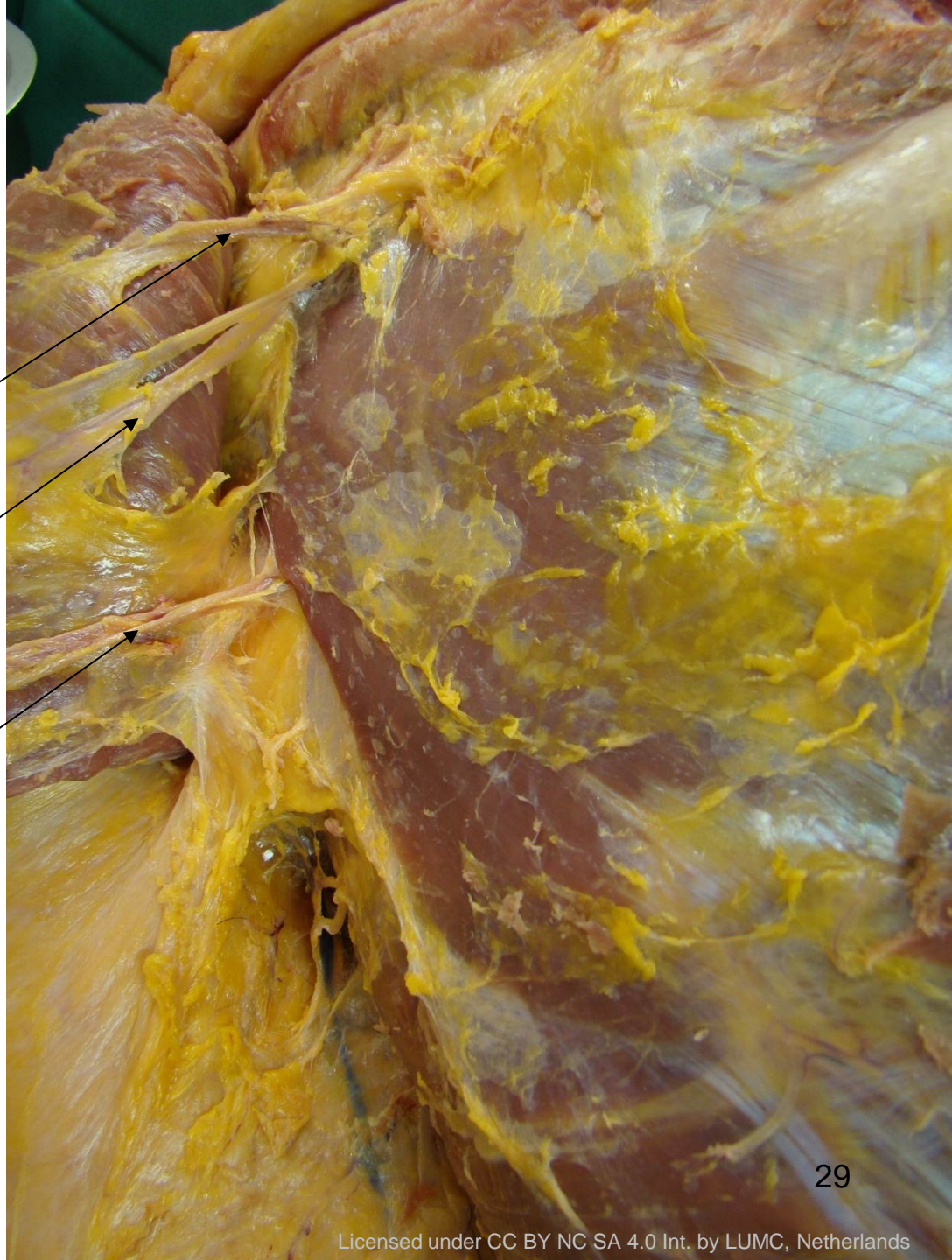

Pectoralis major
muscle folded
laterally

Lateral pectoral
nerve

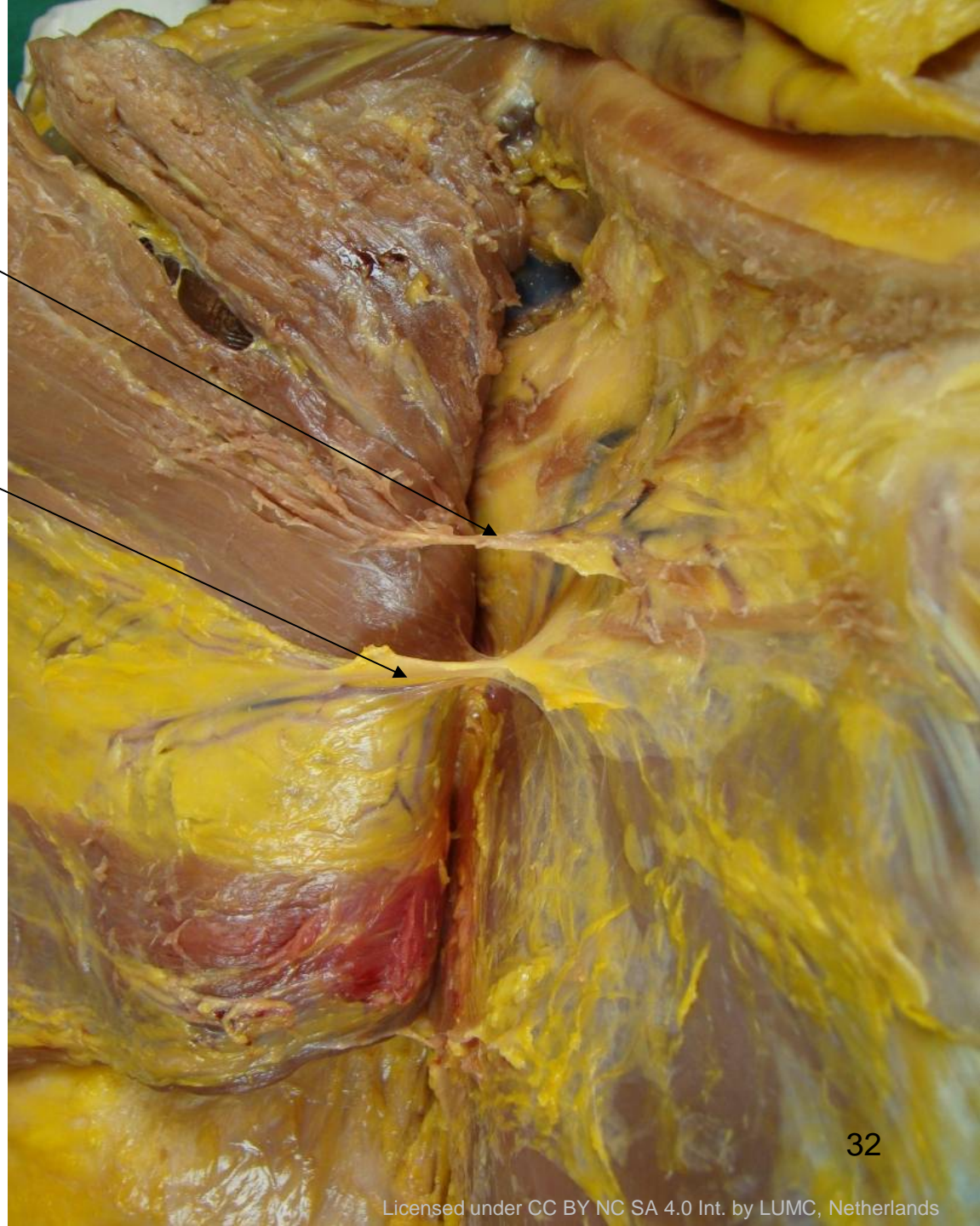Medial pectoral
nerve

Variant, accessory
nerve

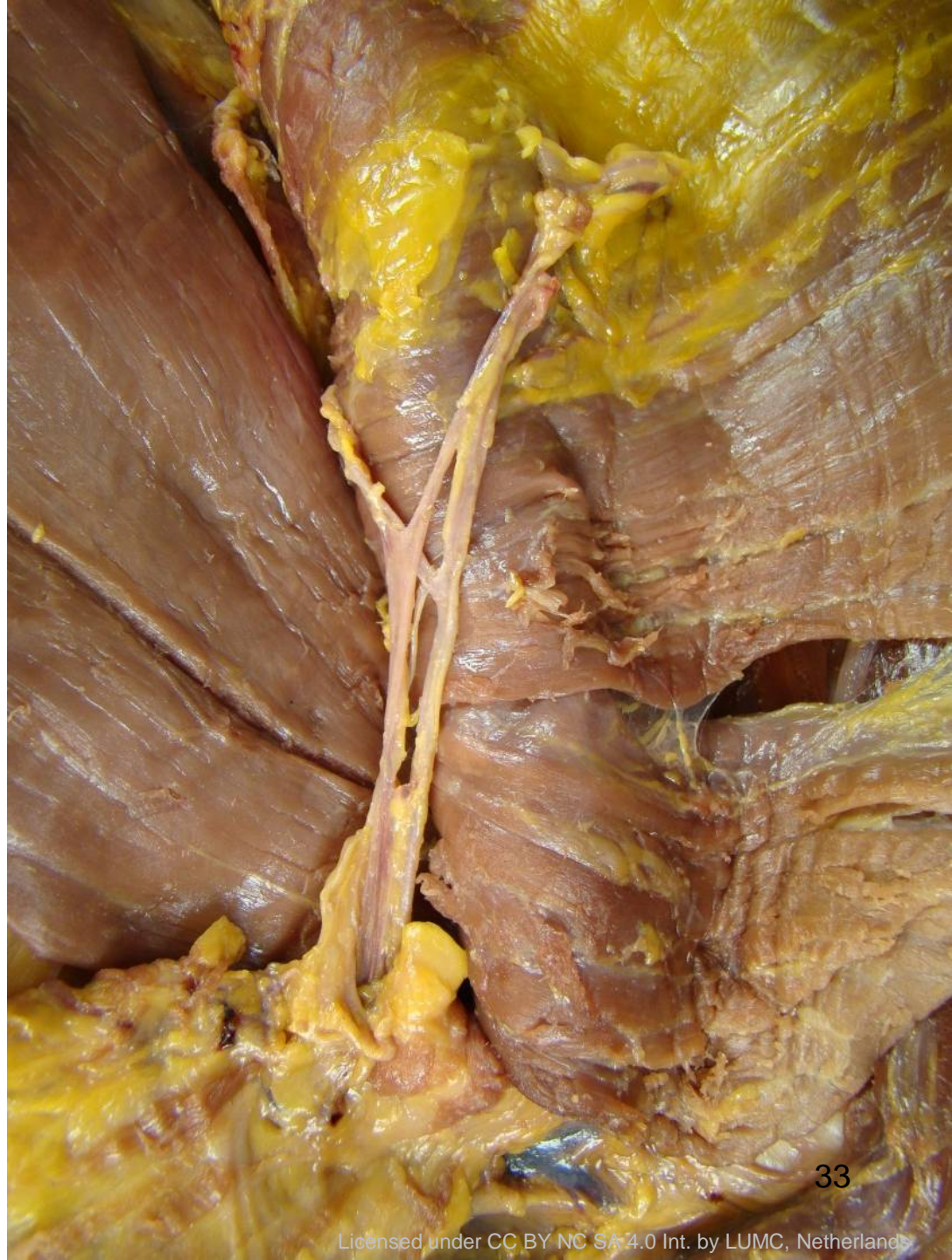

Lateral pectoral
nerves and vessels

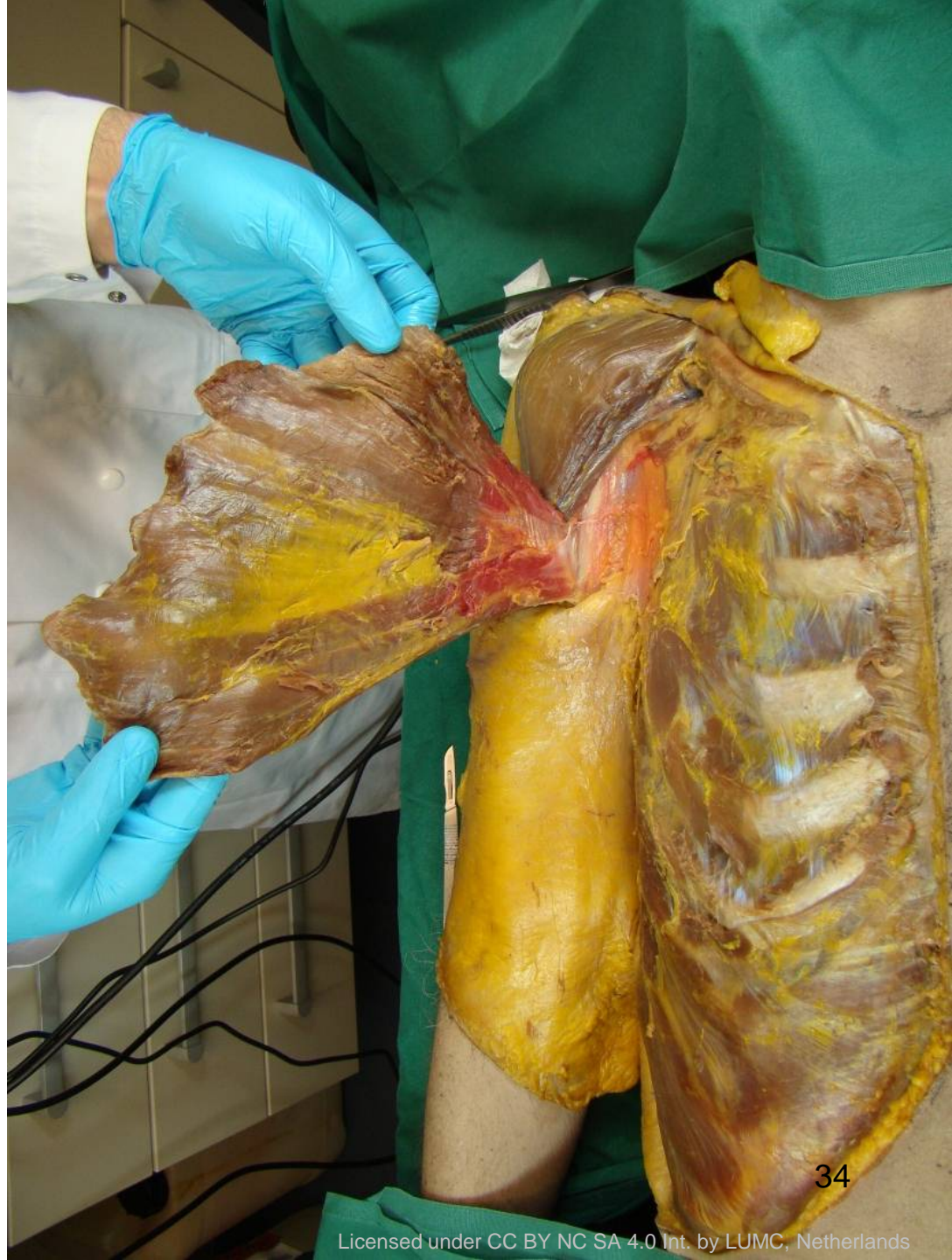Medial pectoral
nerves and vessels



Medial pectoral nerves and vessels



- Pectoralis major folded laterally



Deltoid muscle

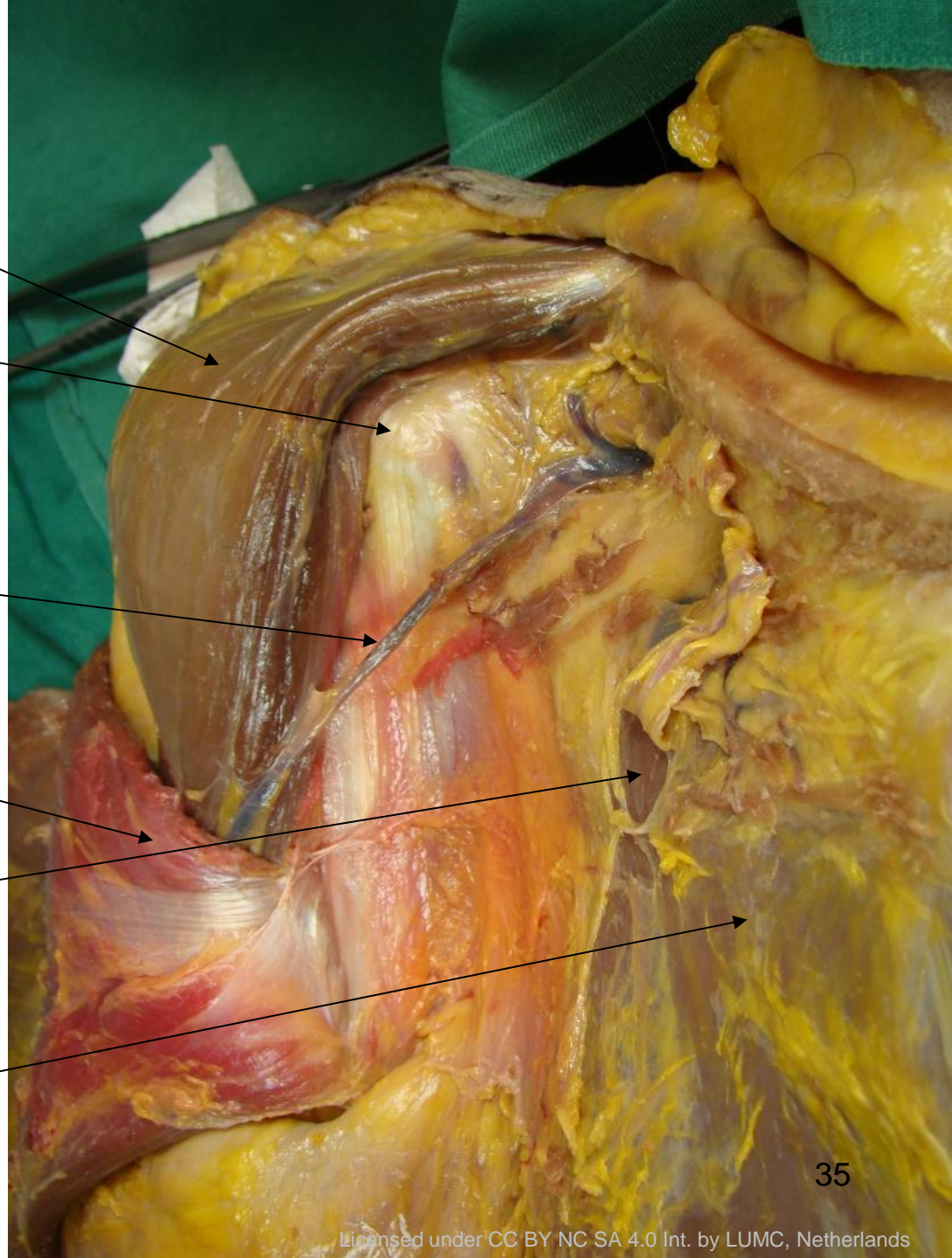
Coracoid process

Cephalic vein

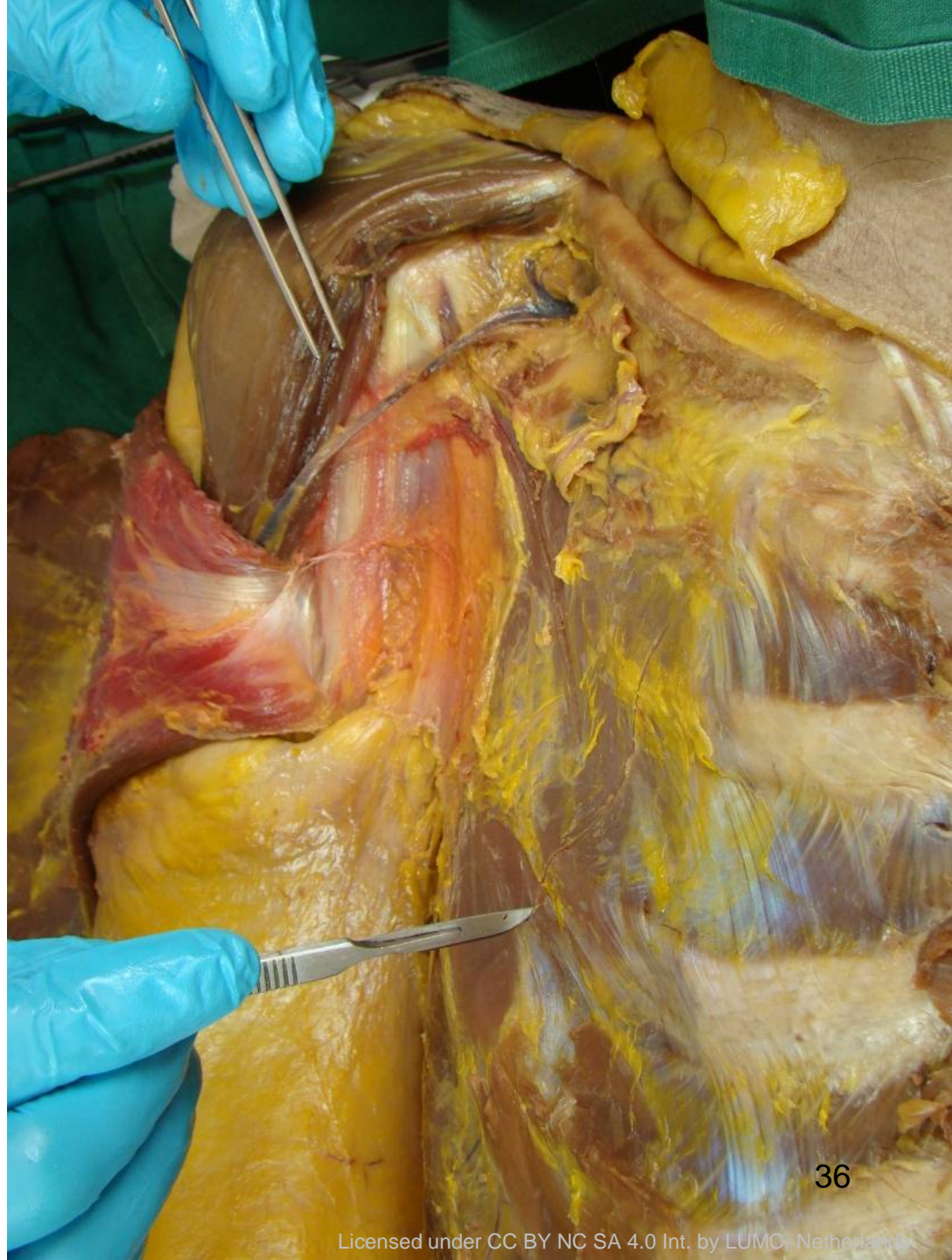Pectoralis major

Pectoralis minor

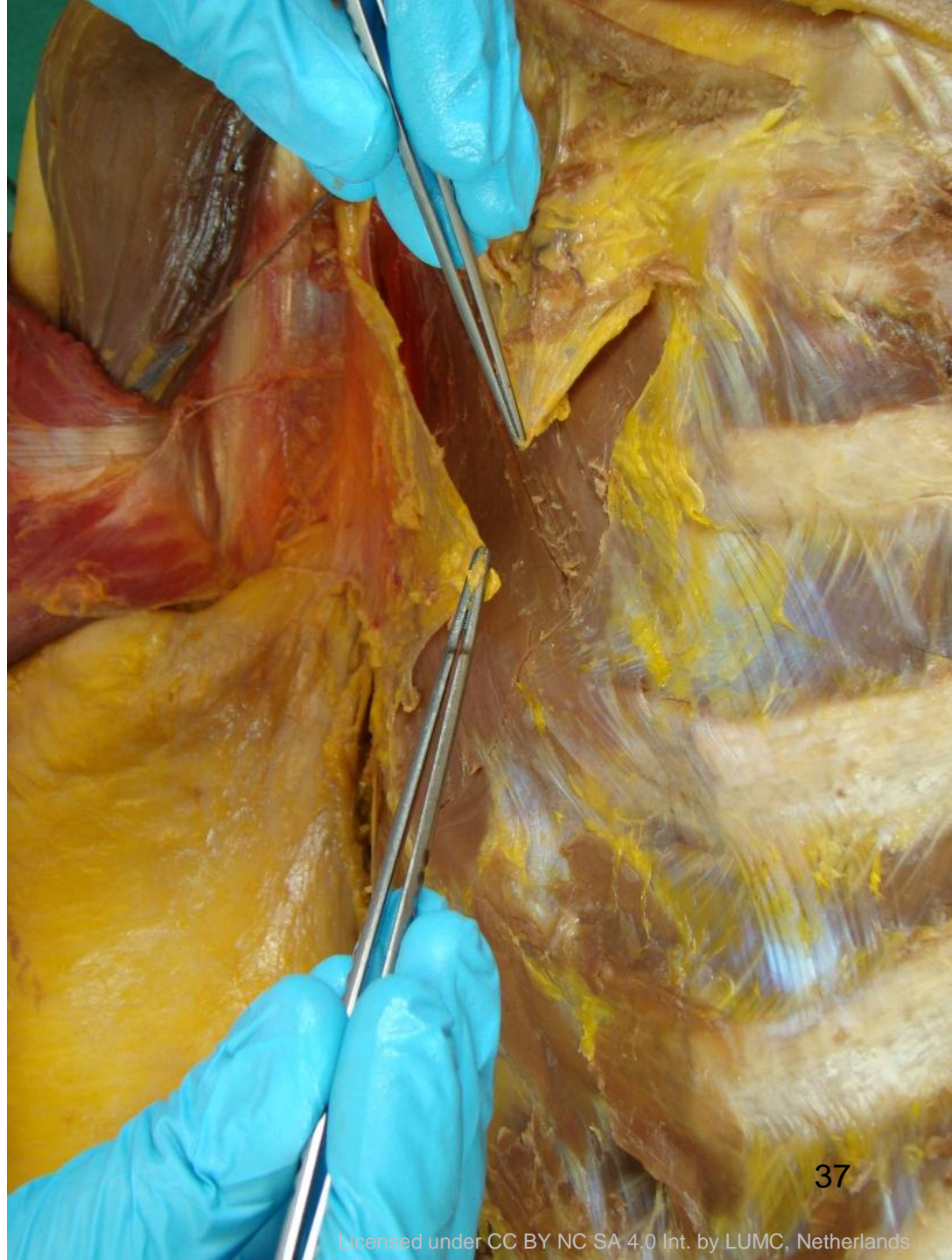Clavipectoral fascia



Opening clavipectoral fascia

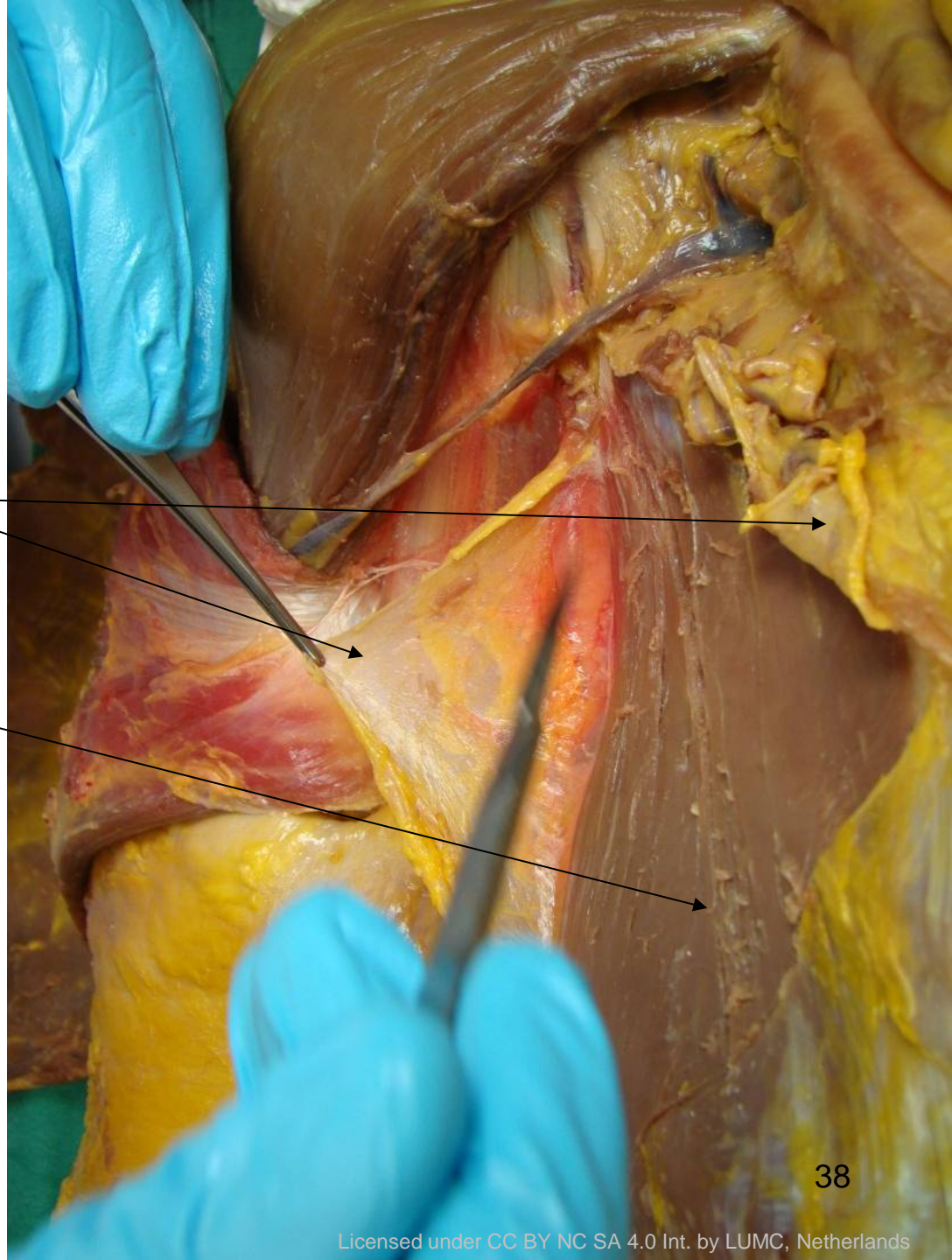


Opening clavipectoral fascia

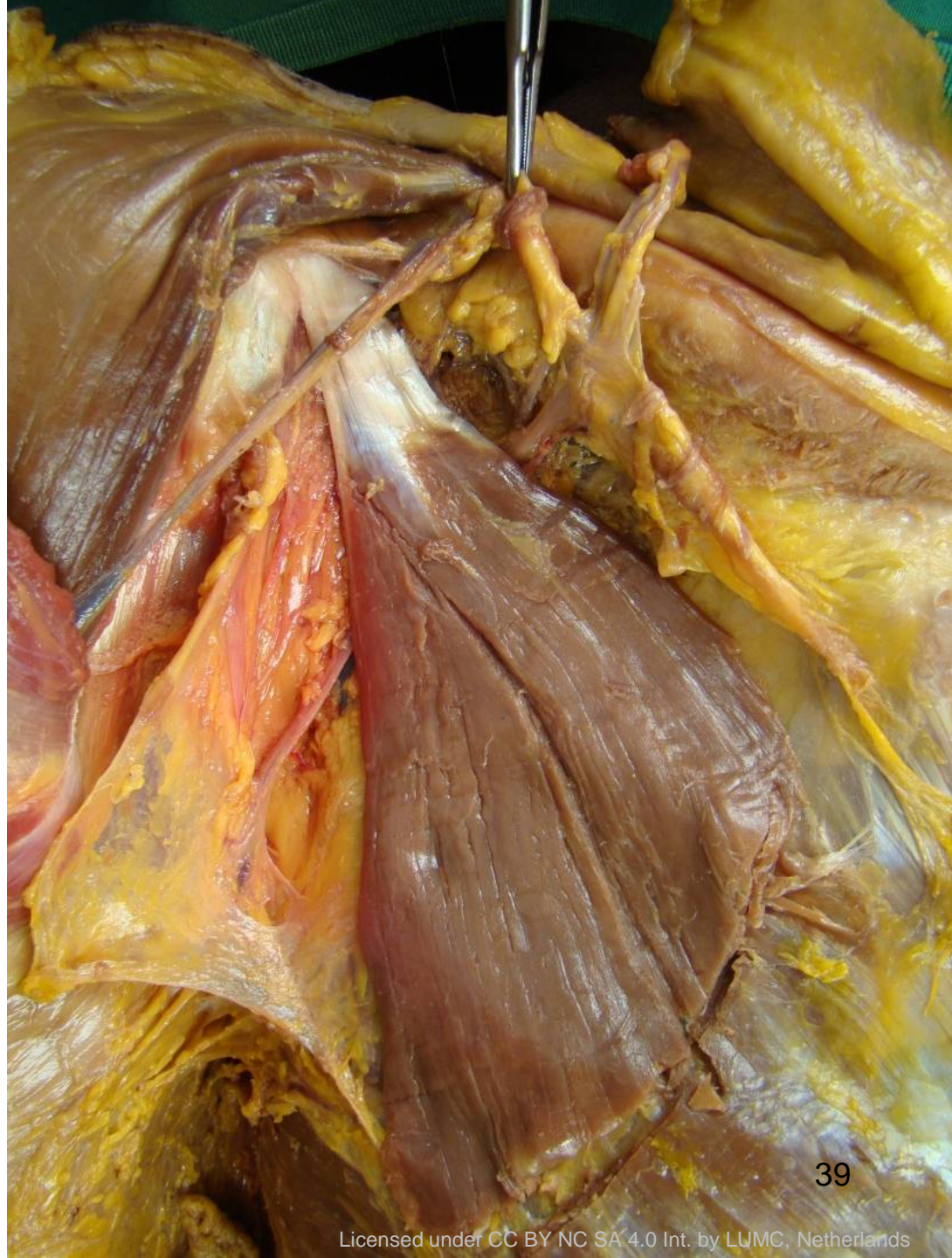

Clavipectoral fascia

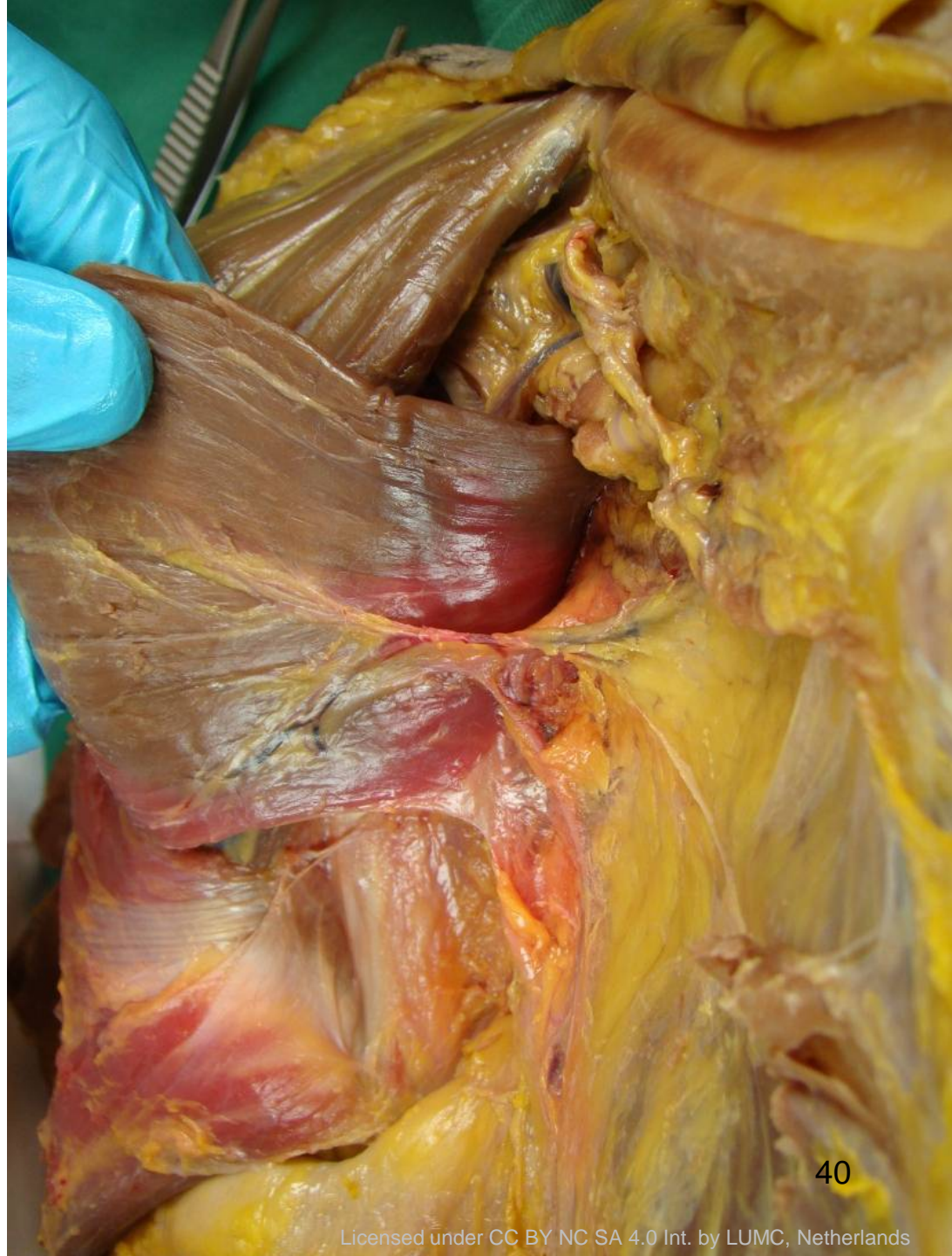Pectoralis minor
muscle



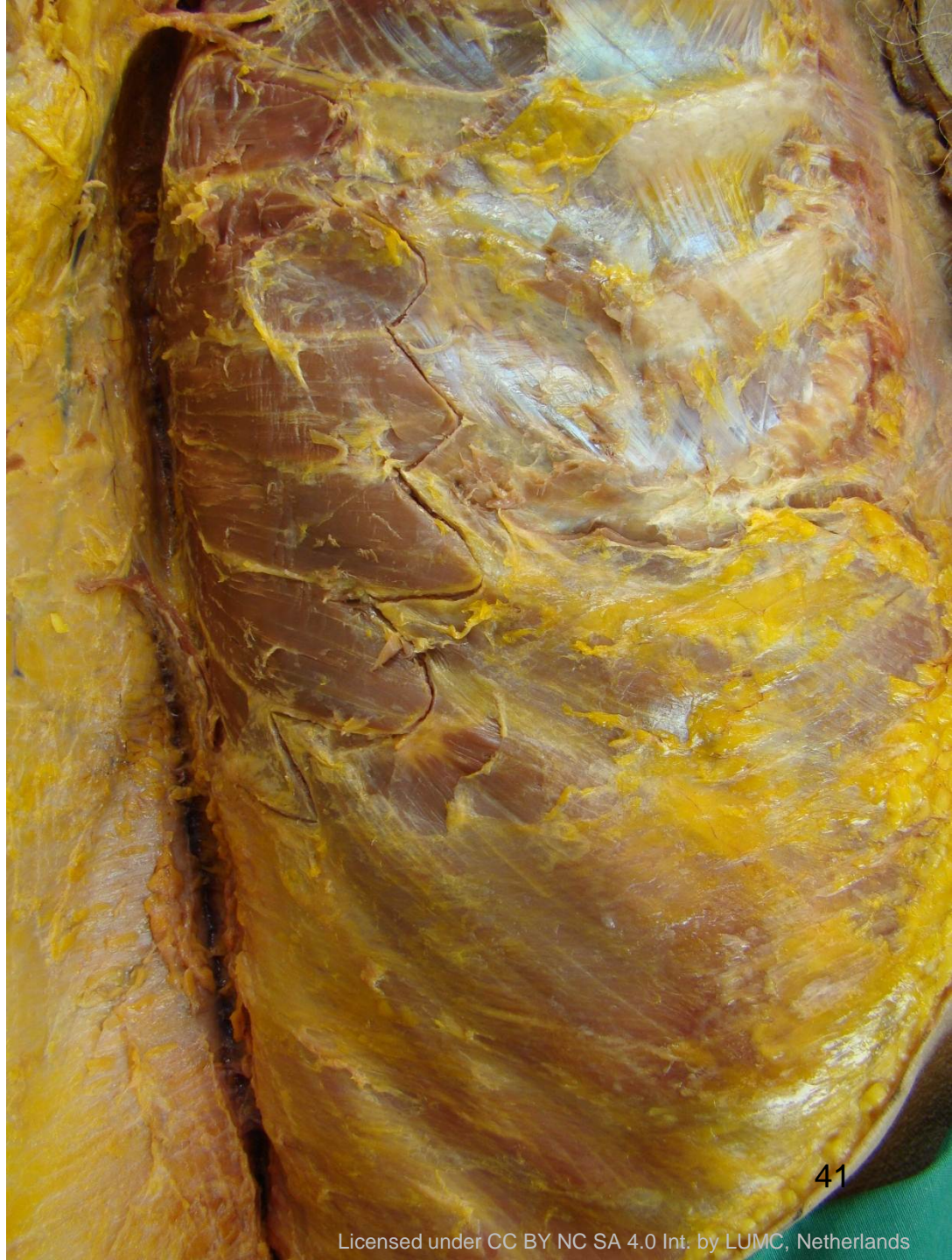Pectoralis minor muscle



Pectoralis minor nerve and blood vessels

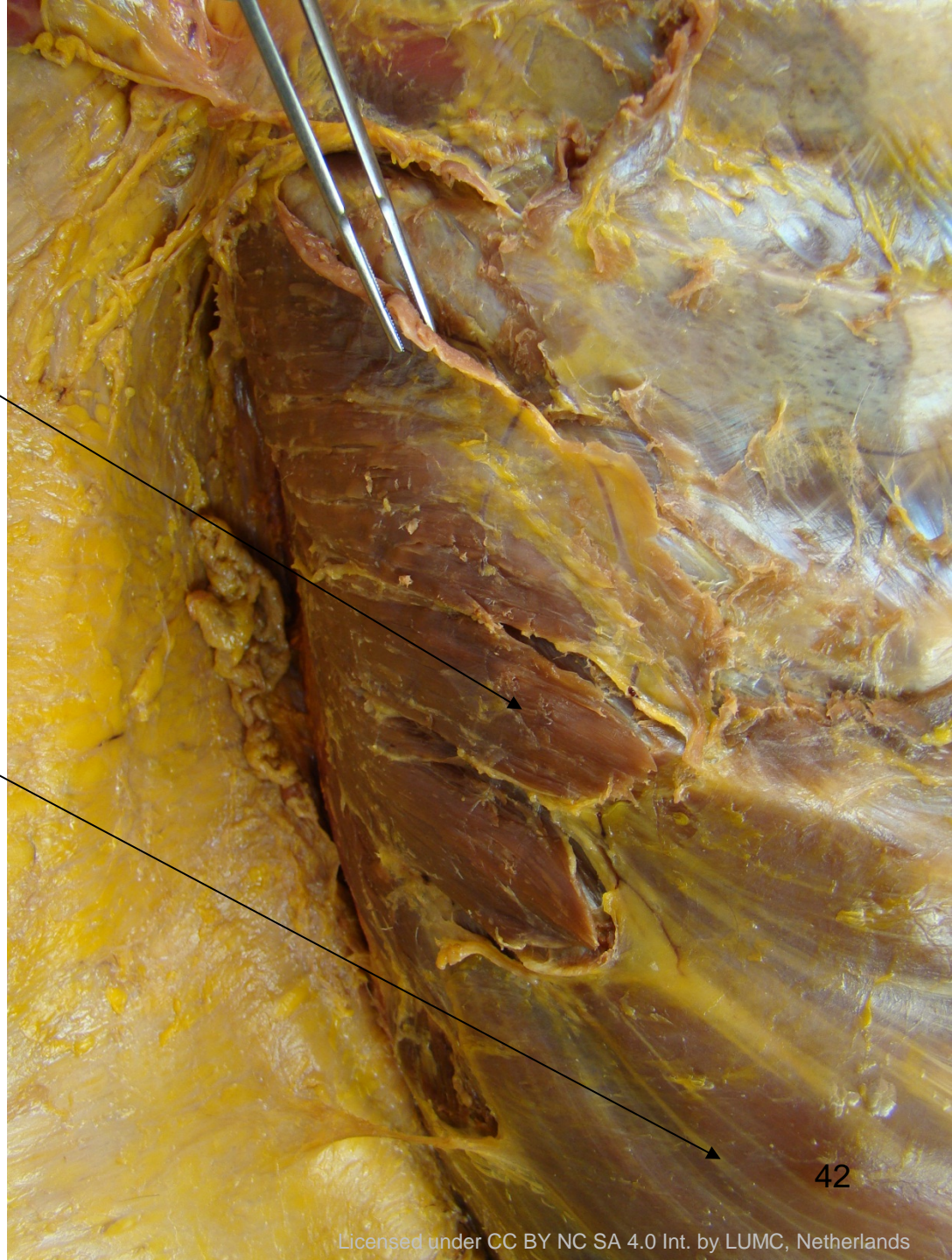

Serratus anterior muscle
origins from ribs



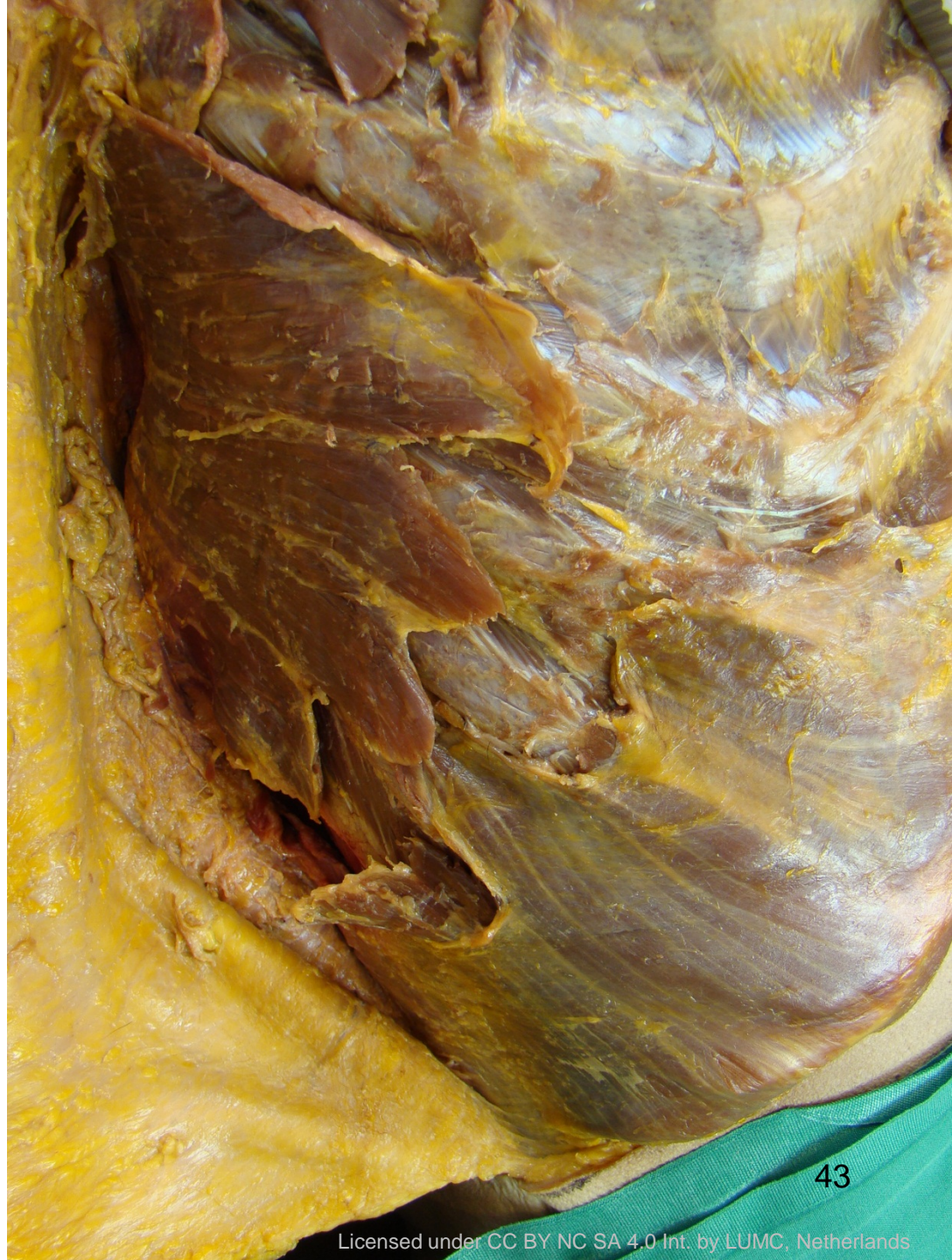Serratus anterior
muscle interdigitation
with

Abdominal external
oblique muscle



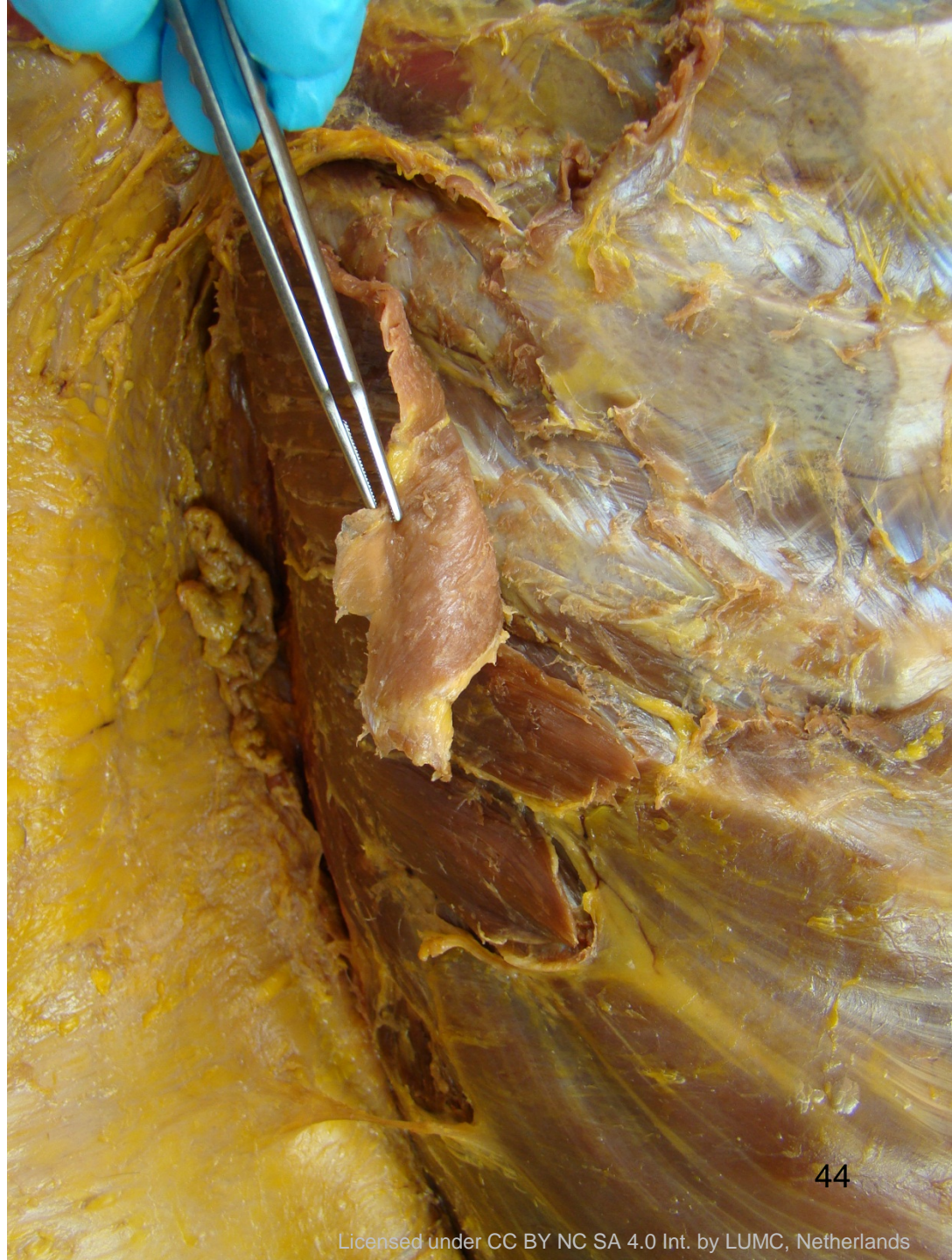Serratus anterior
muscle interdigitation
with

Abdominal external
oblique muscle

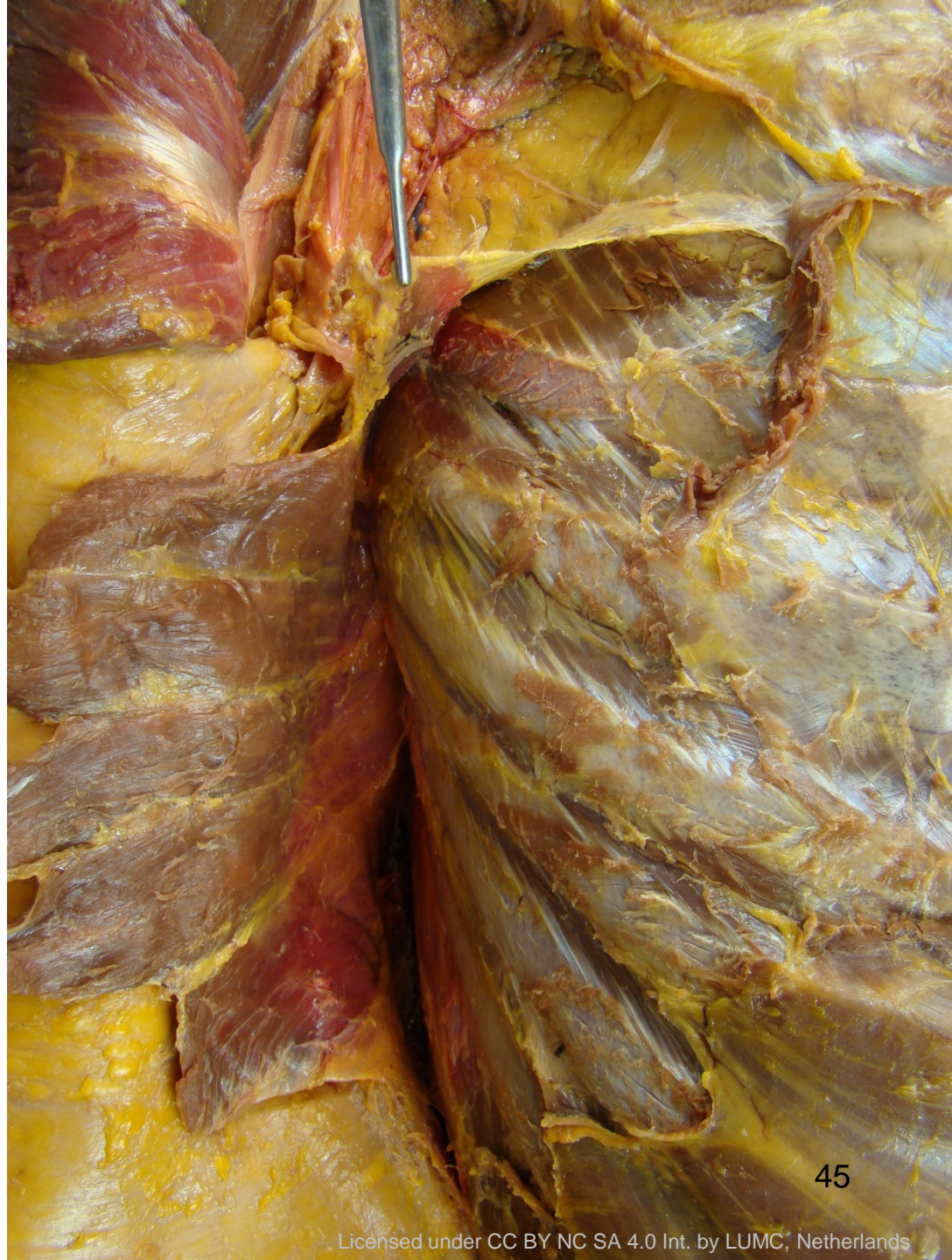

Serratus anterior
muscle interdigitation
with

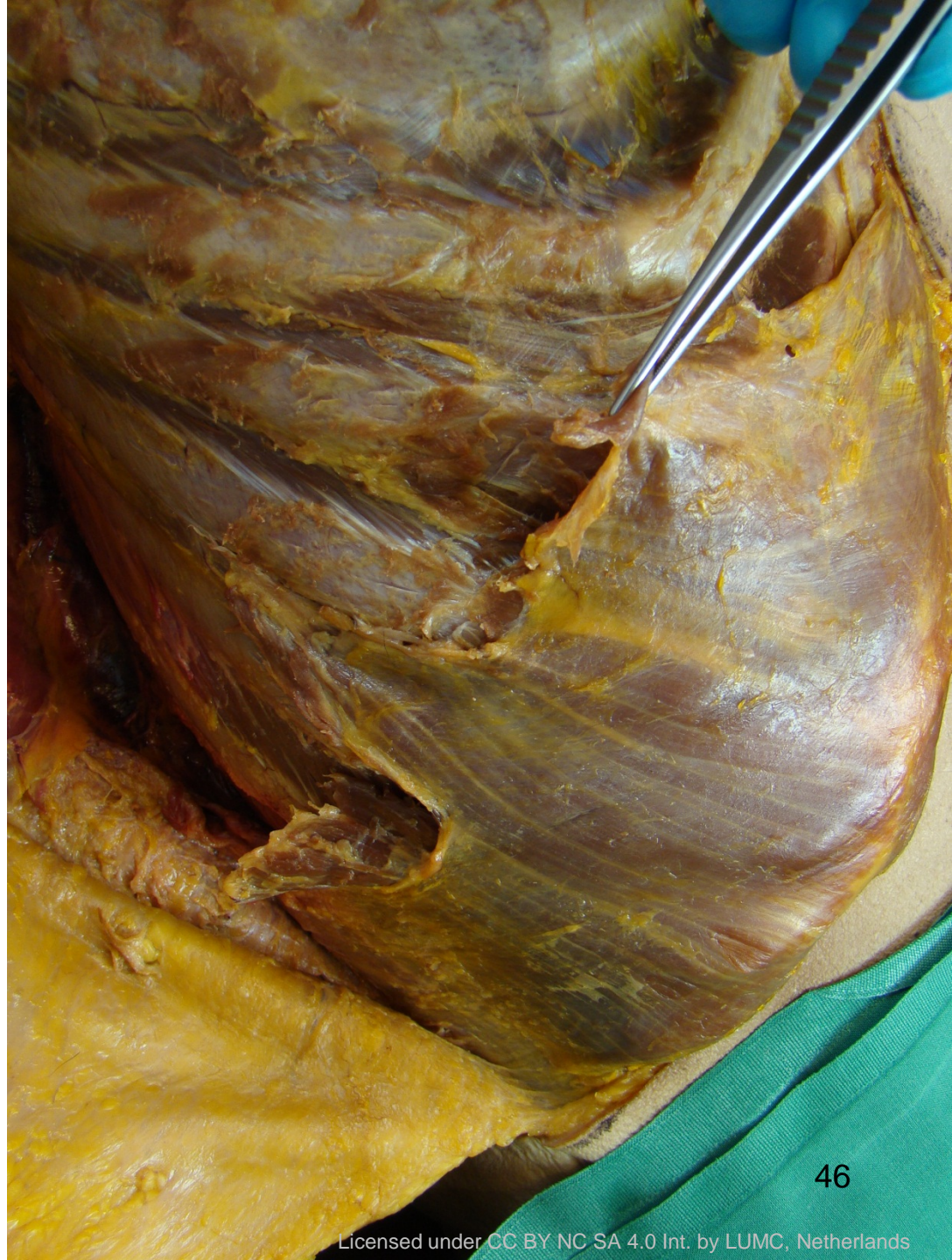
Abdominal external
oblique muscle



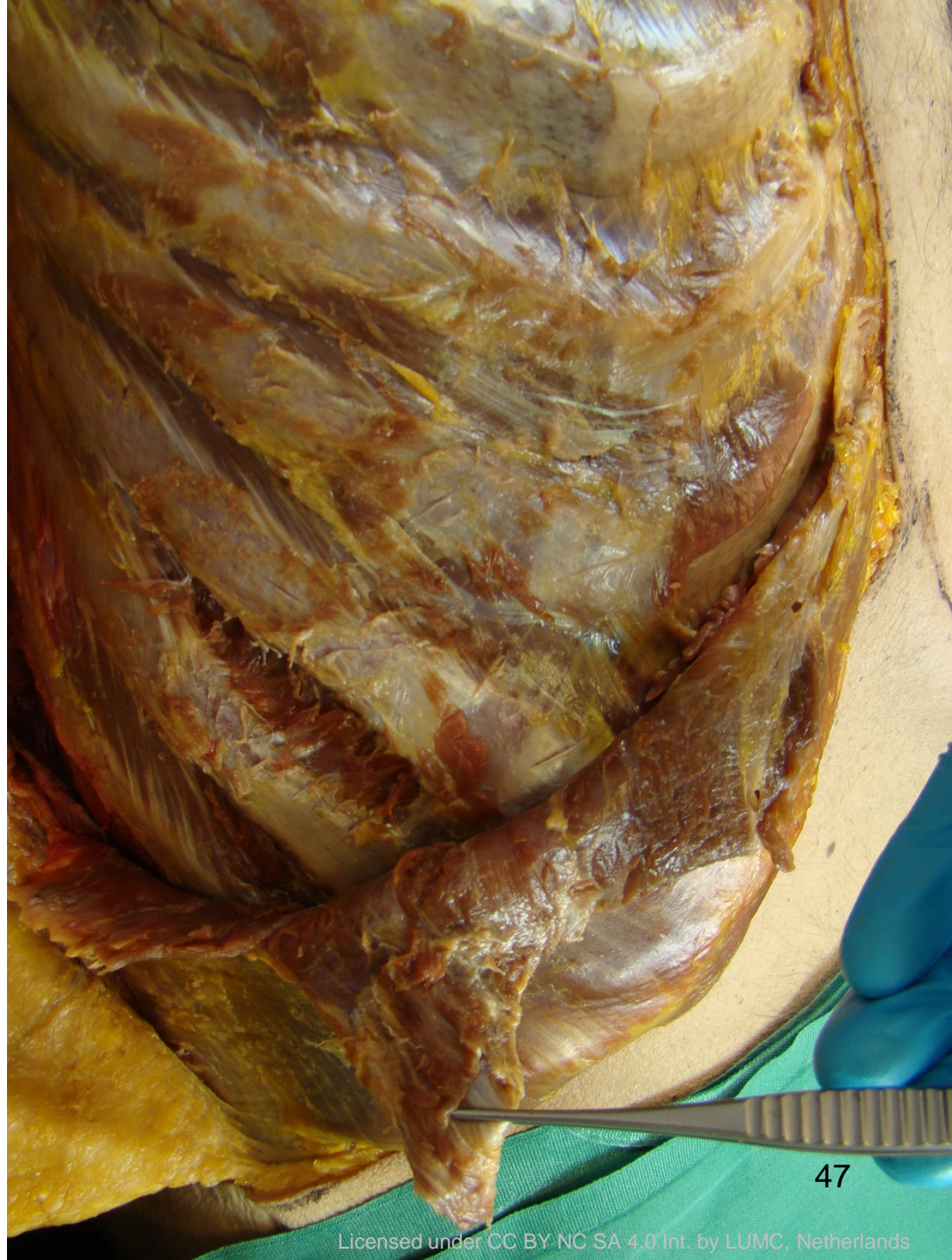Serratus anterior
muscle dissected



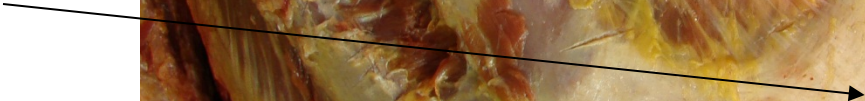External abdominal
oblique muscle
origins from ribs



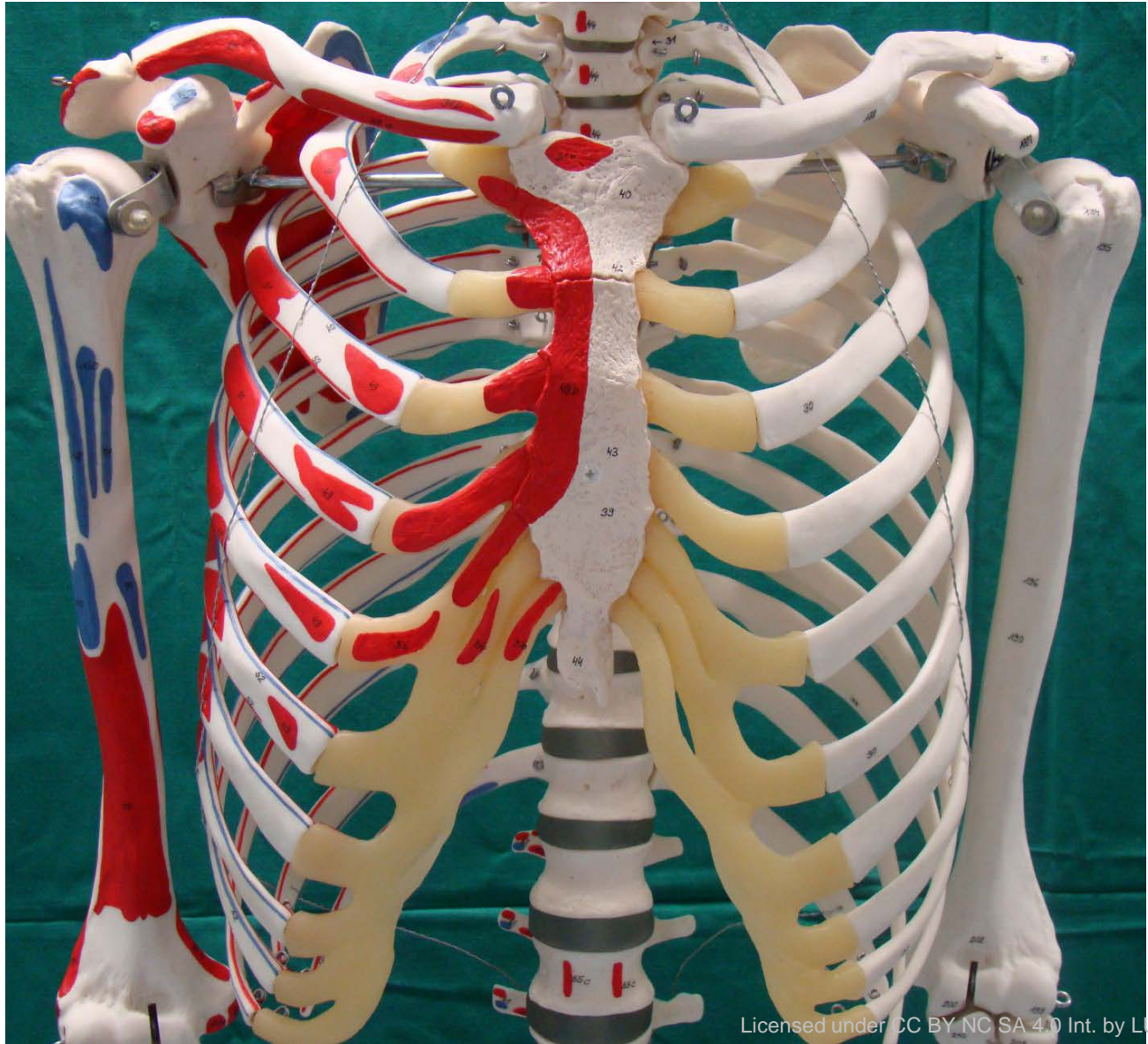
External abdominal
oblique muscle
origins from ribs



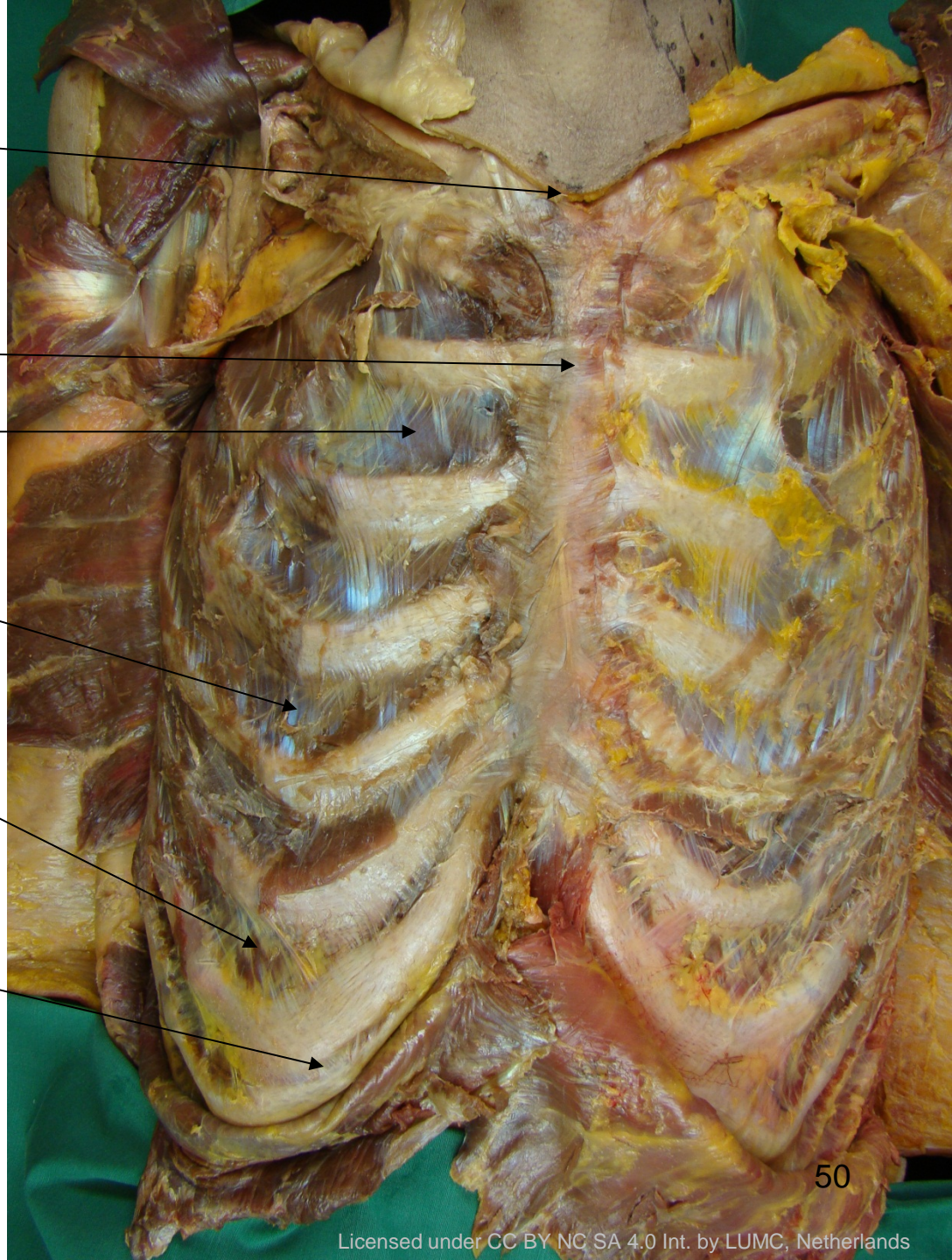
Costal margin



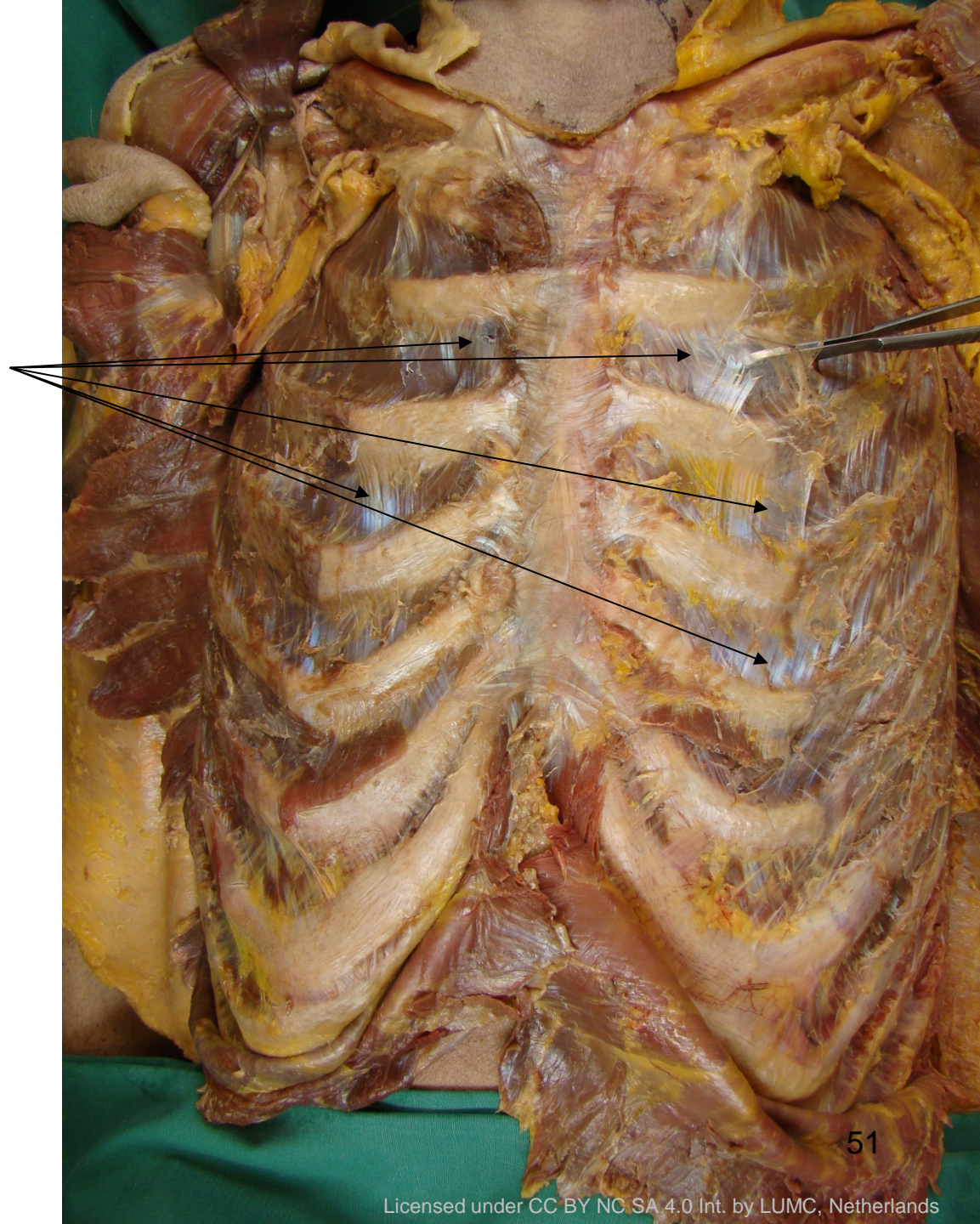
Intercostal spaces



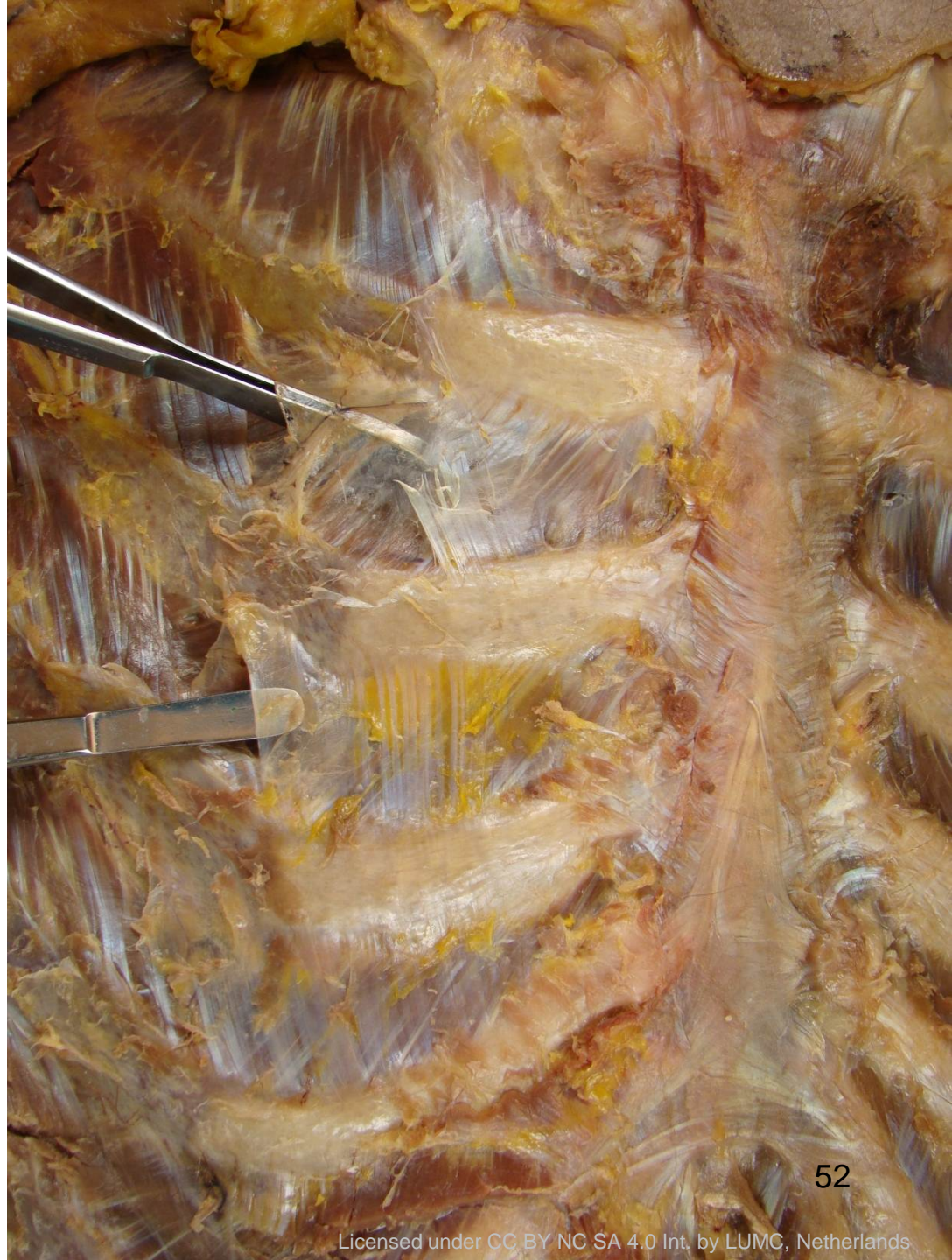
- Sternal notch
- Sternal angle
- 2nd intercostal space
- 4th intercostal space
- 6th intercostal space
- Costal margin



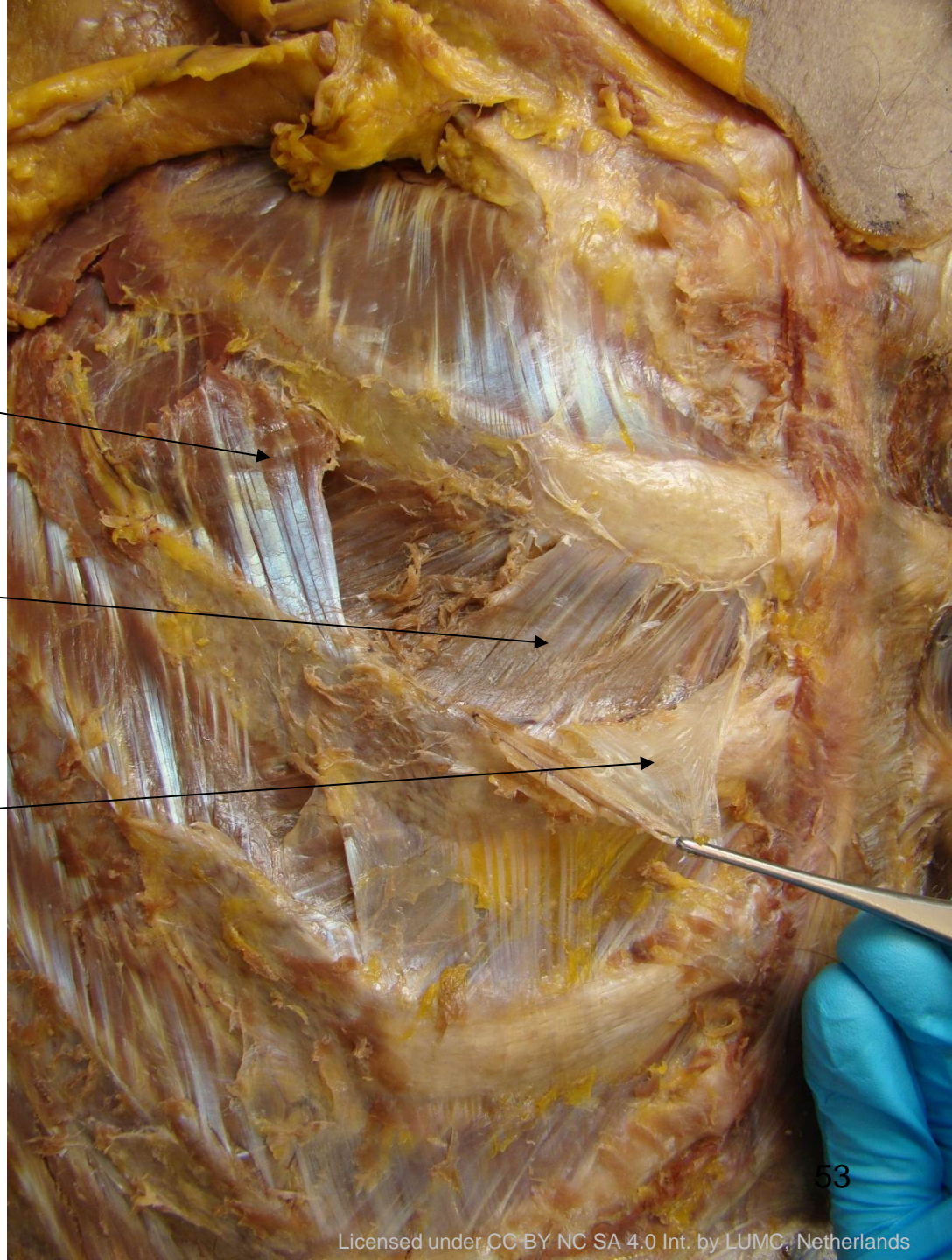
- External intercostal membrane



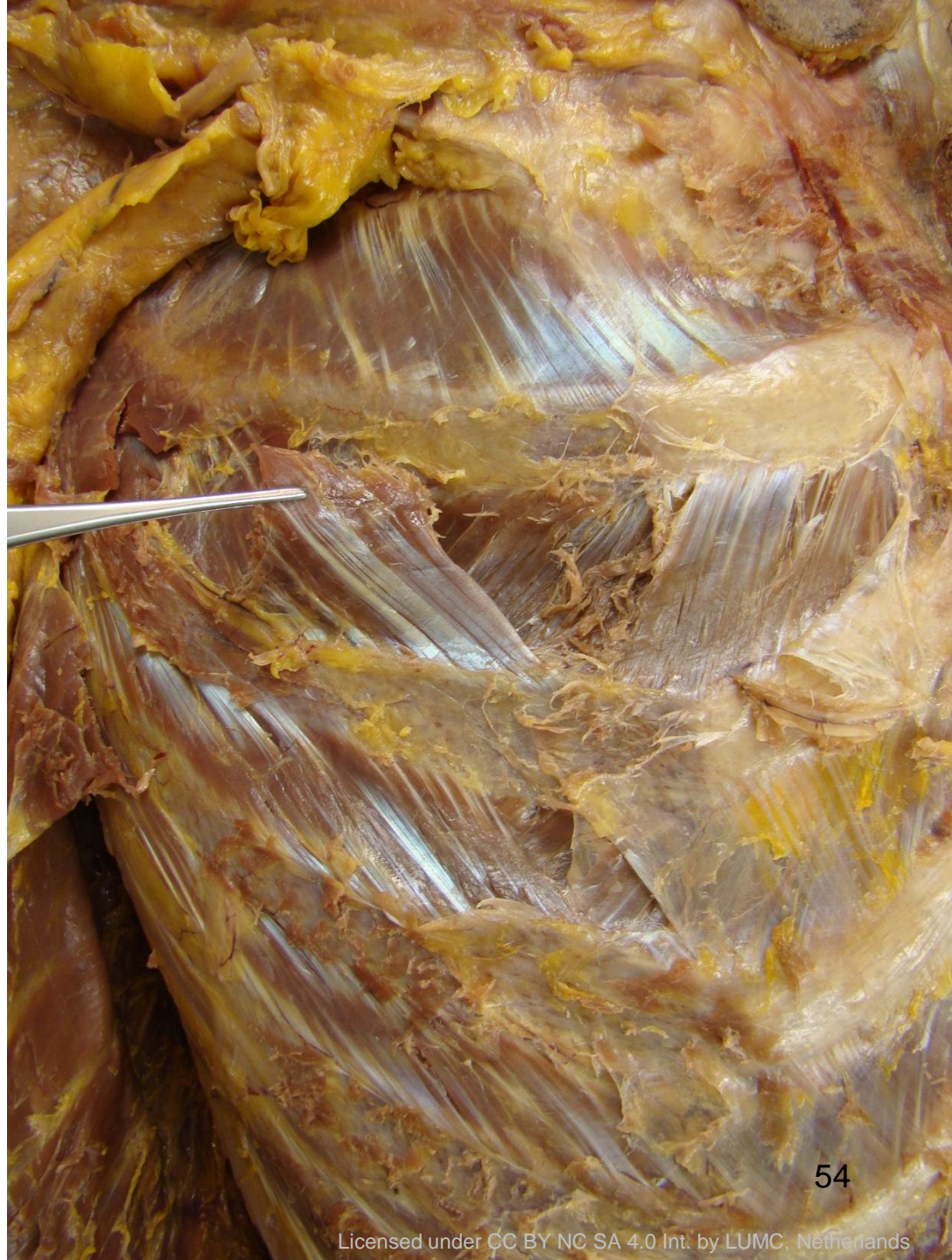- External intercostal membrane



- External intercostal muscle
- Internal intercostal muscle
- External intercostal membrane



- External intercostal muscle dissected

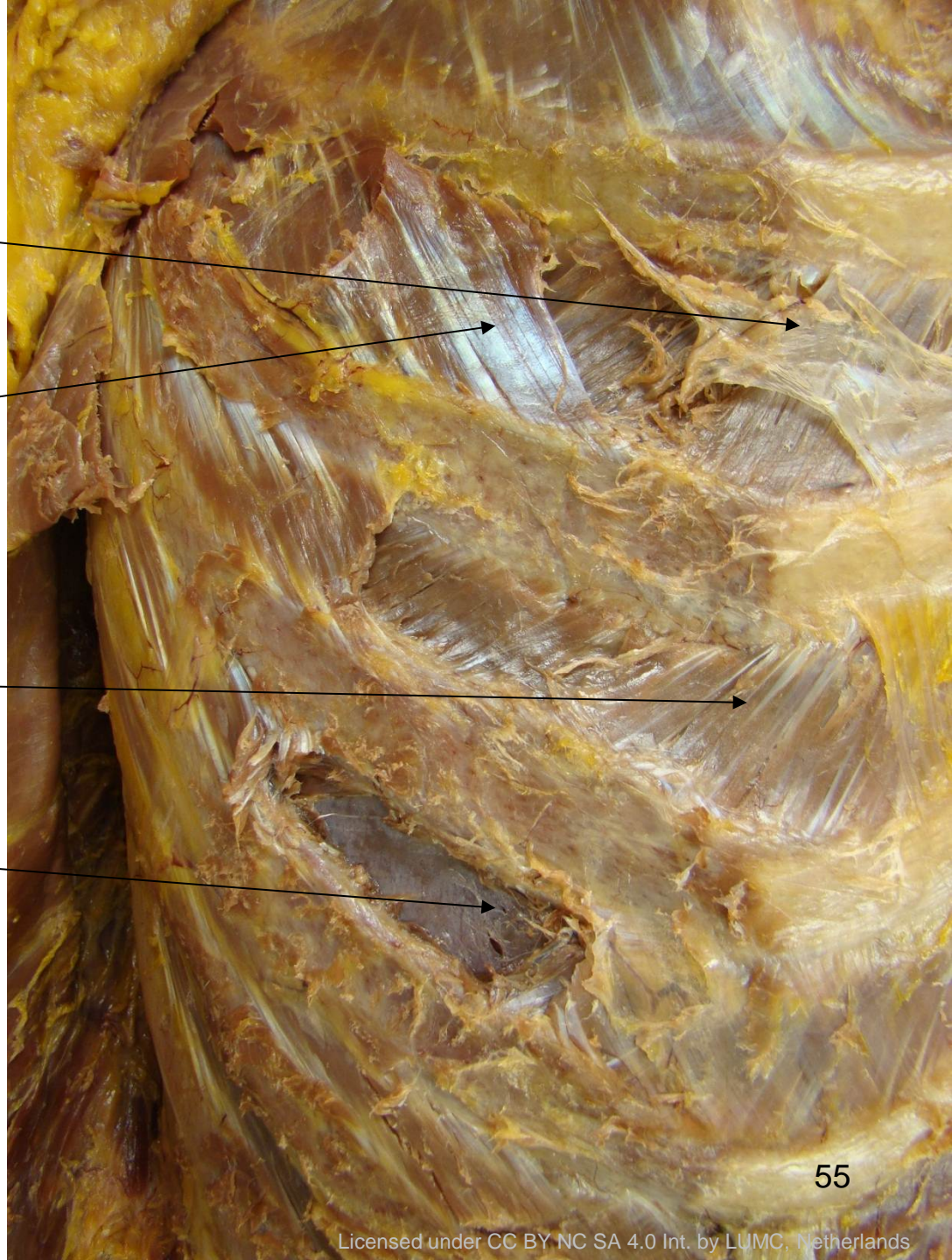

- External intercostal membrane

- External intercostal muscle

- Internal intercostal muscle

- Parietal pleura



- Clavicle

- Ribs:

- 1

Sternal angle

- 2

- 3

- 4

- 5

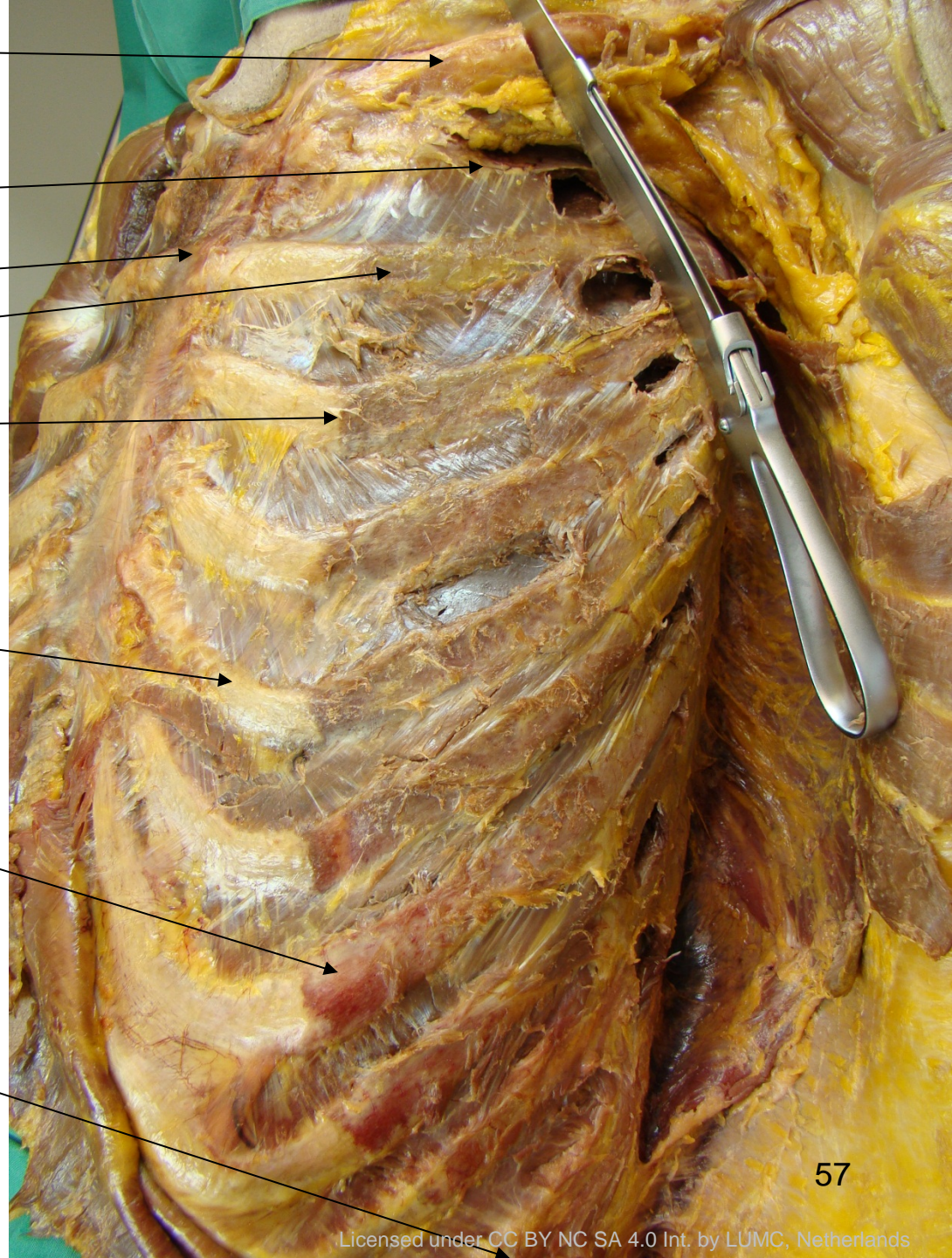- 6

- 7

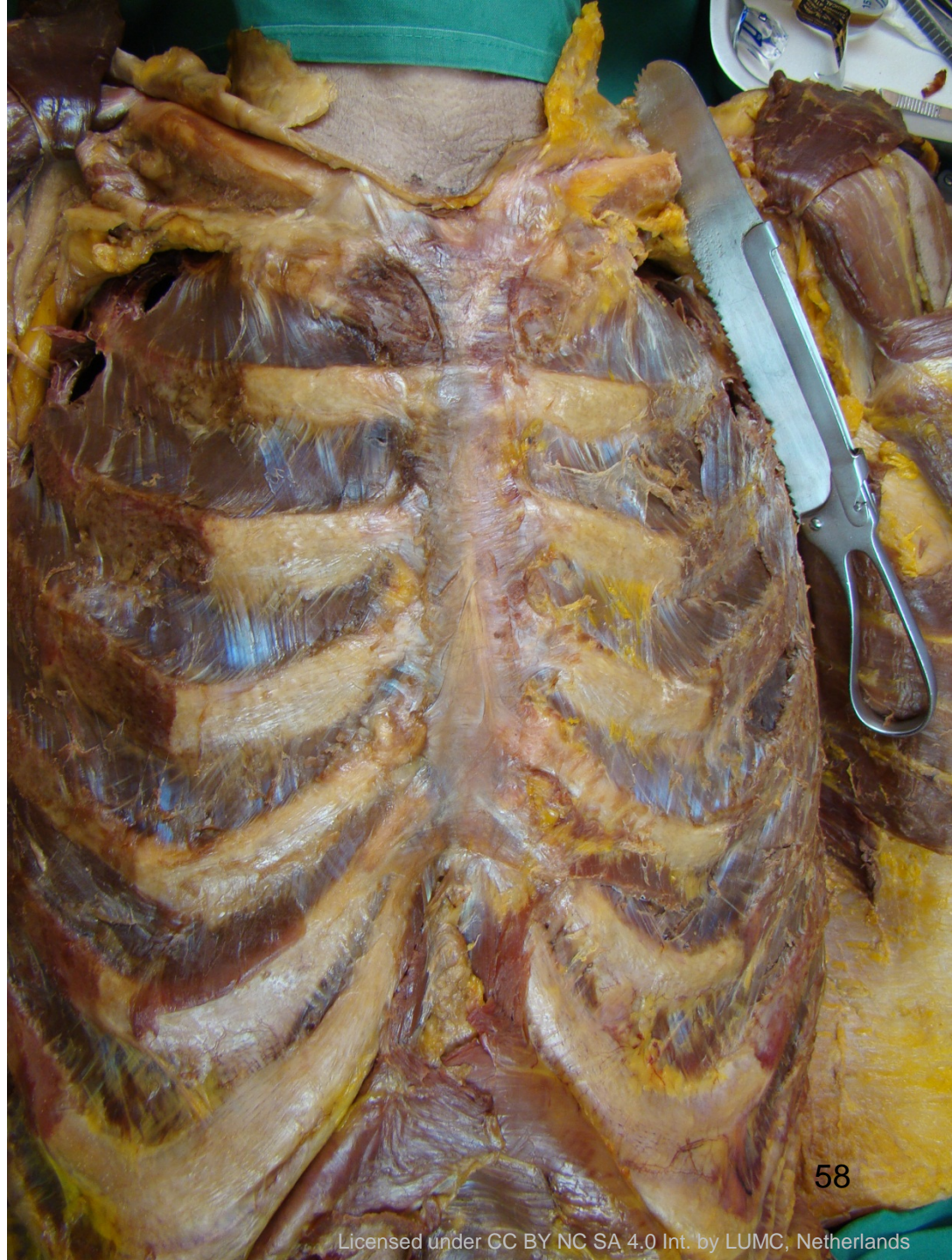- 8

- 9

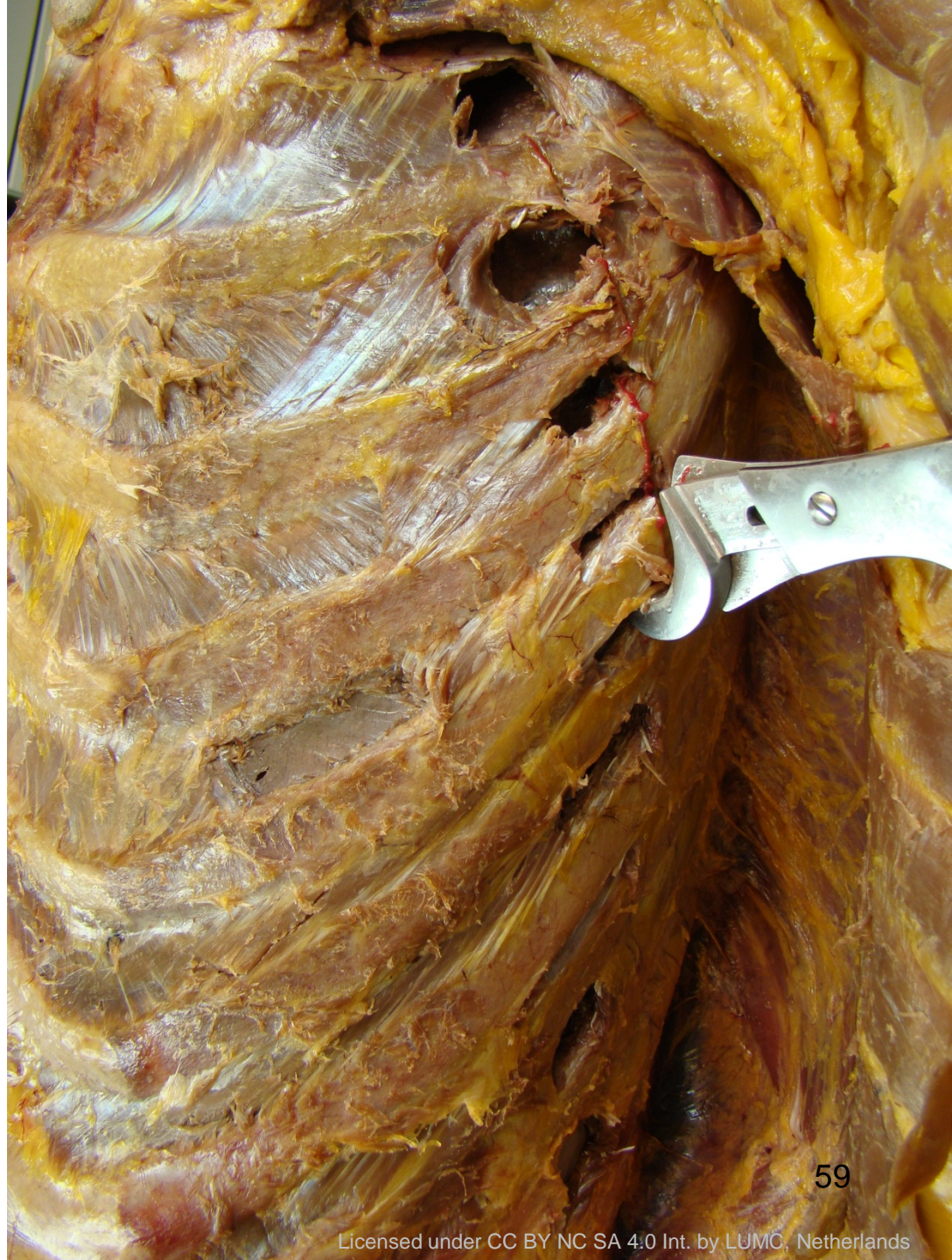- 10



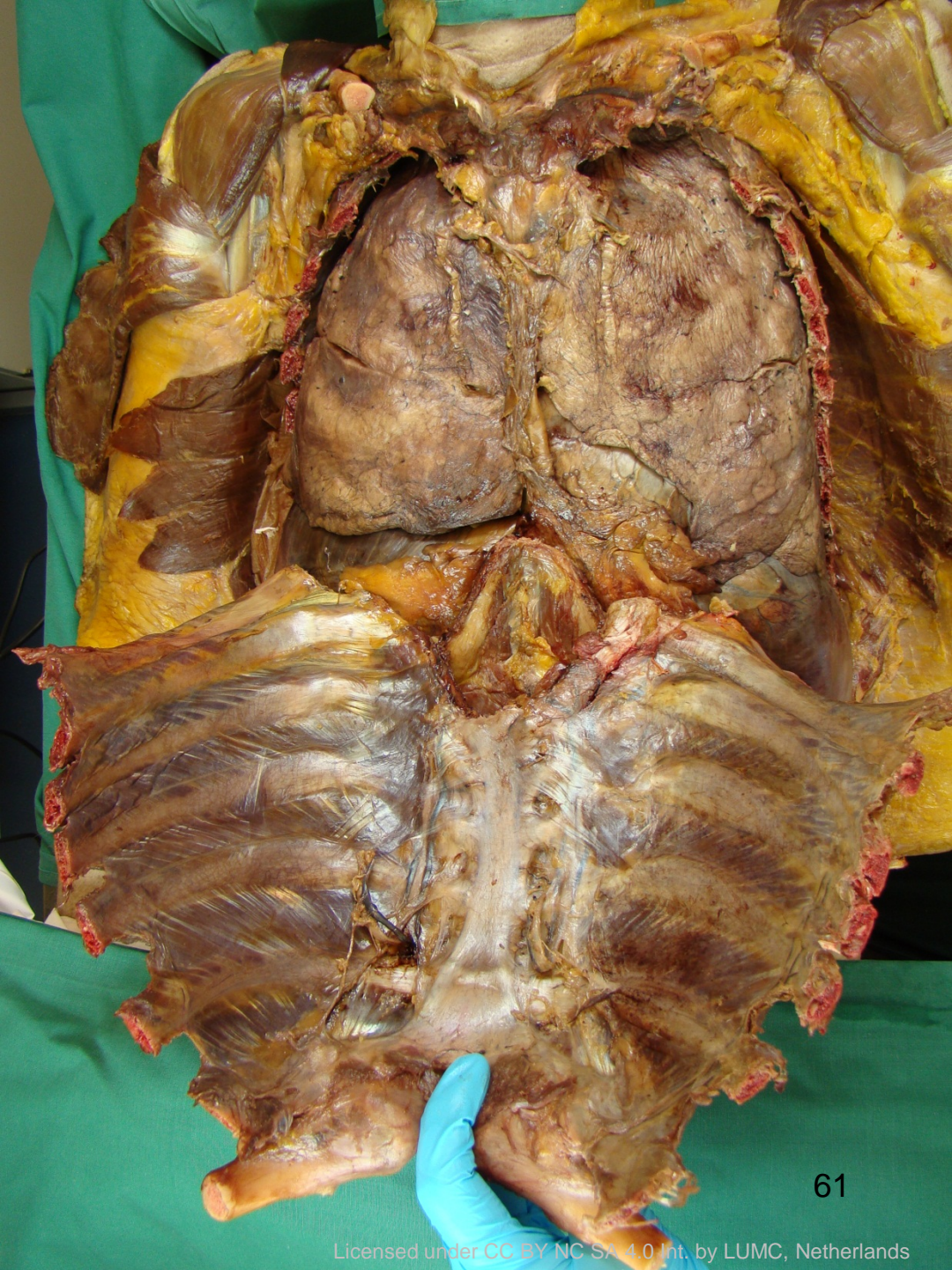
Cutting of the
clavicles on both
sides



- In mid-axillary line or more dorsal
- Holes in each intercostal space
- Cutting the Ribs


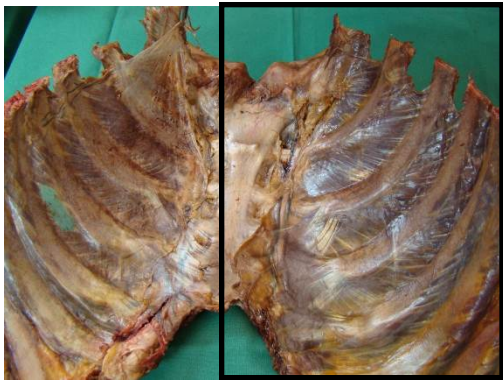


Anterior thoracic wall
opened

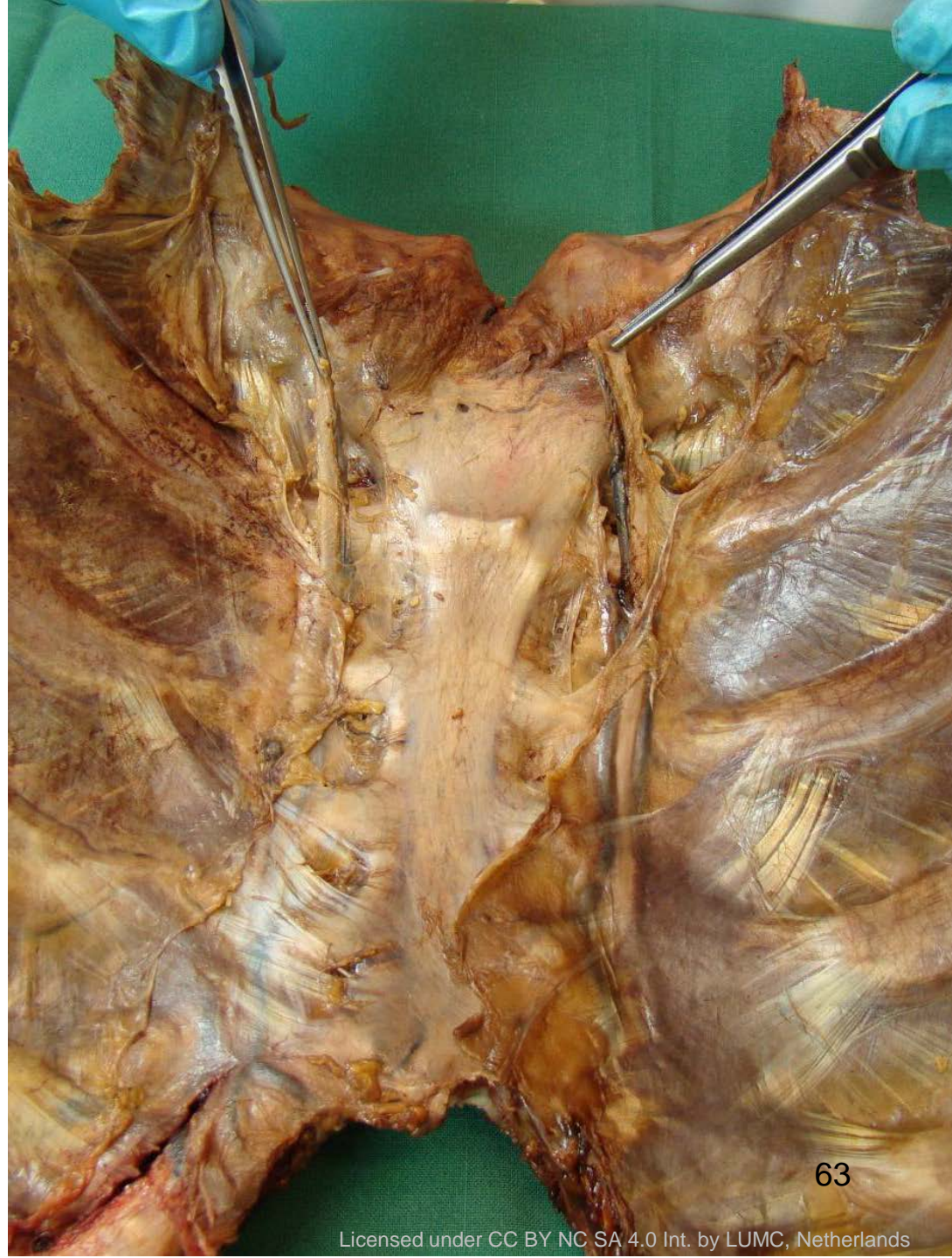

Parietal pleura

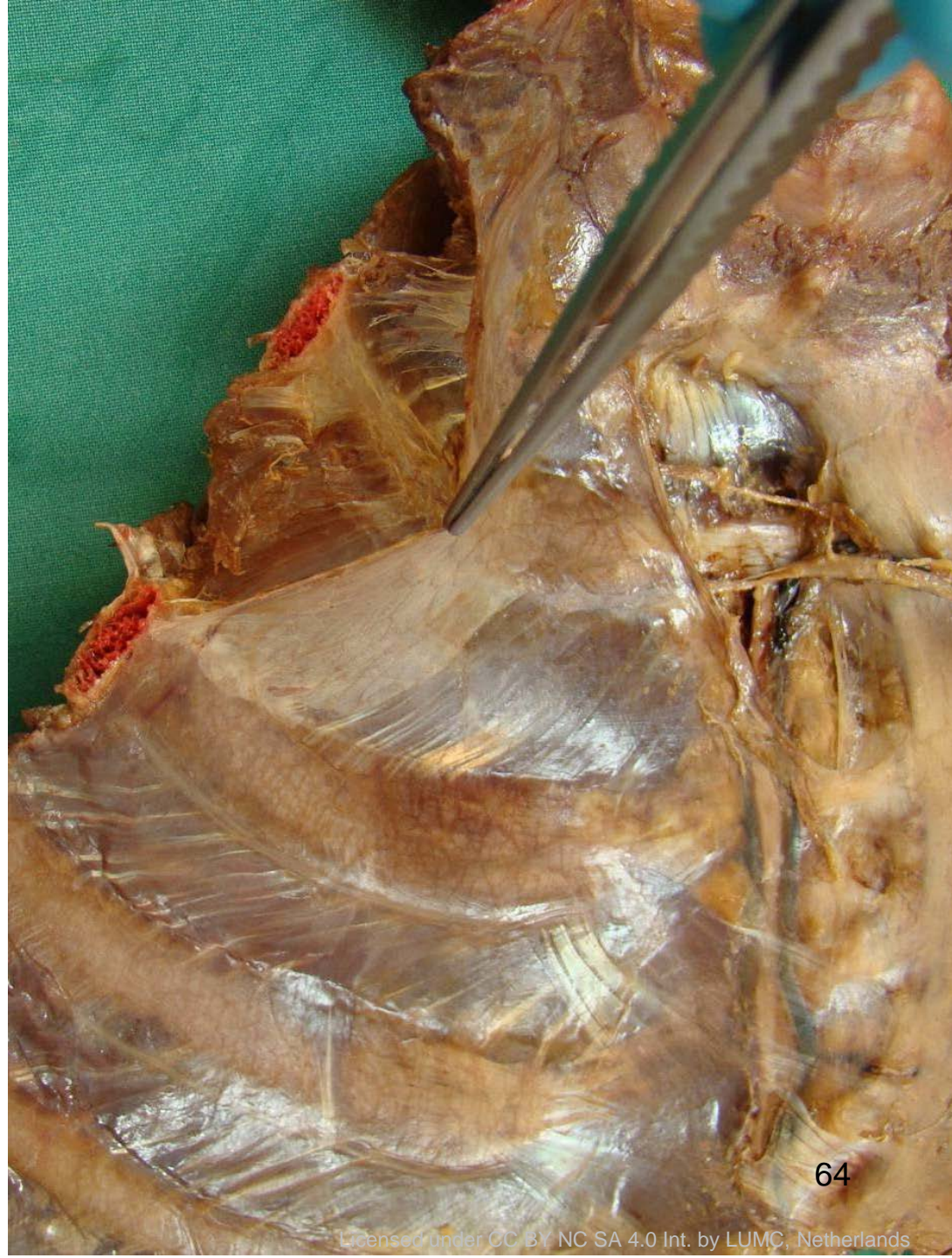(view from inside)



Internal thoracic artery
and veins
(aa./vv. mammaria)
(view from inside)

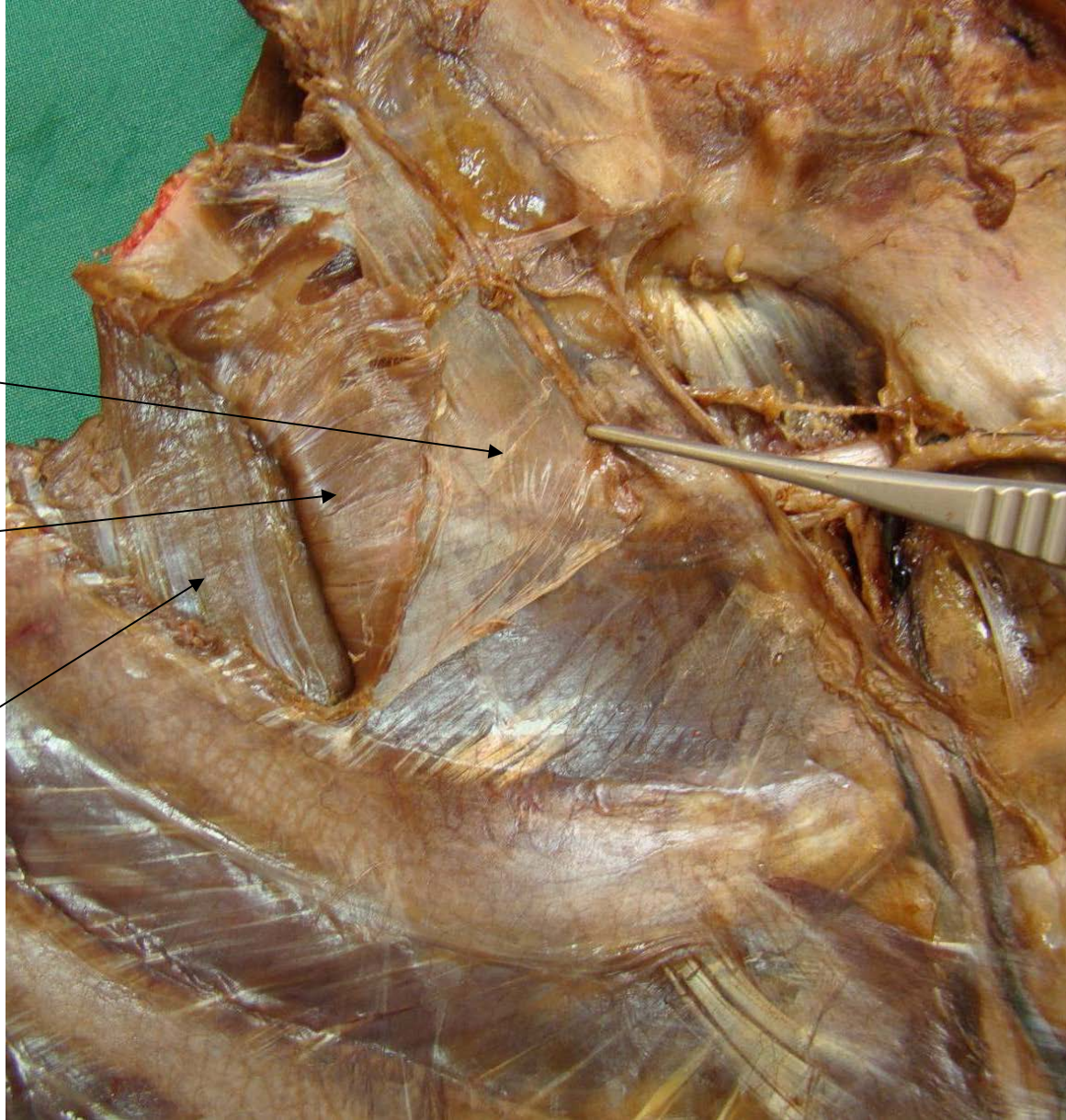

- **Parietal pleura**
(view from inside)



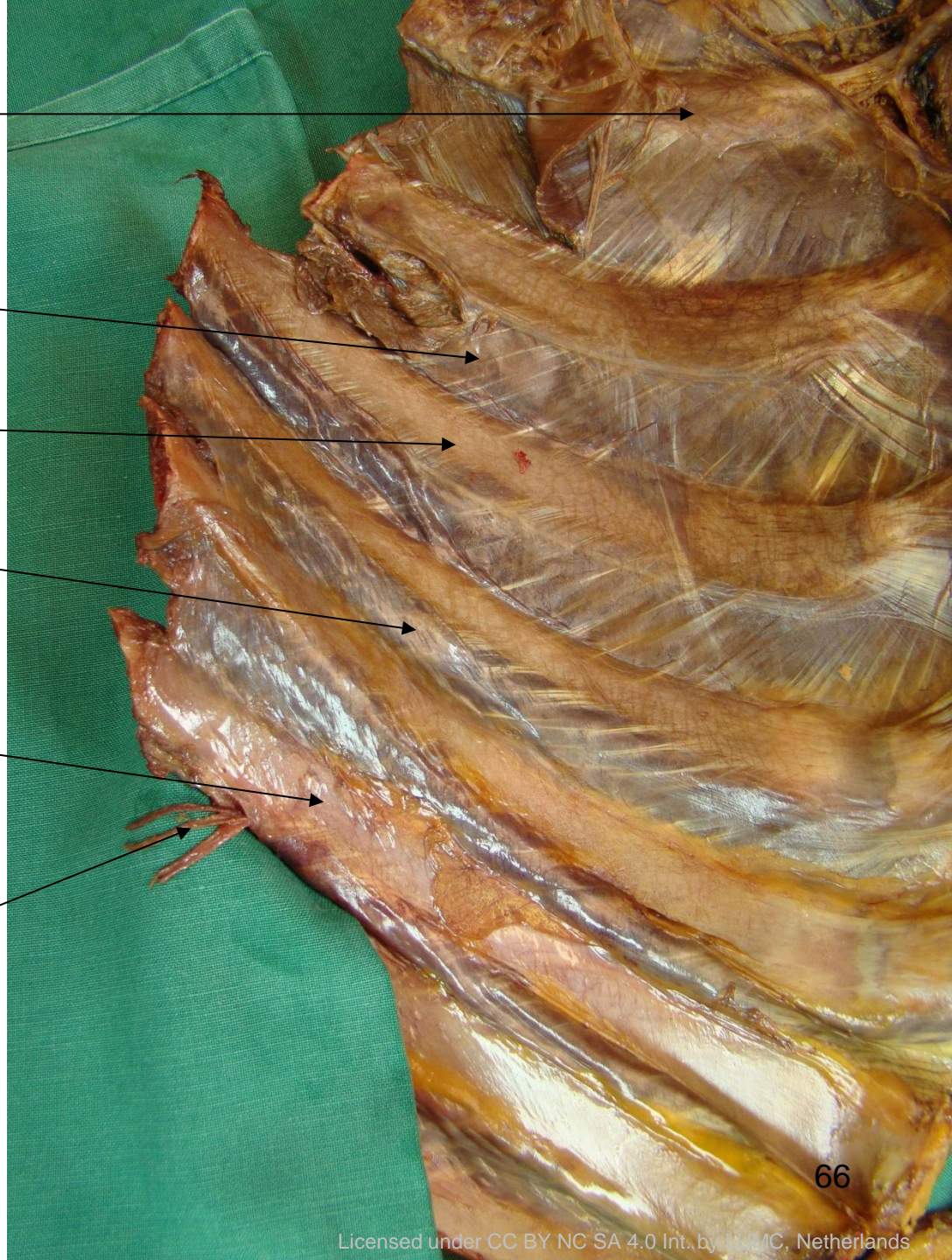
- Parietal pleura
- Internal intercostal muscle
- External intercostal muscle

(view from inside)



- First rib
- 2nd intercostal space
- 3rd rib
- 4th intercostal space
- 6th rib
- Intercostal neurovascular bundle

(view from inside)



- 3rd rib

- 4th rib

- Intercostal vein

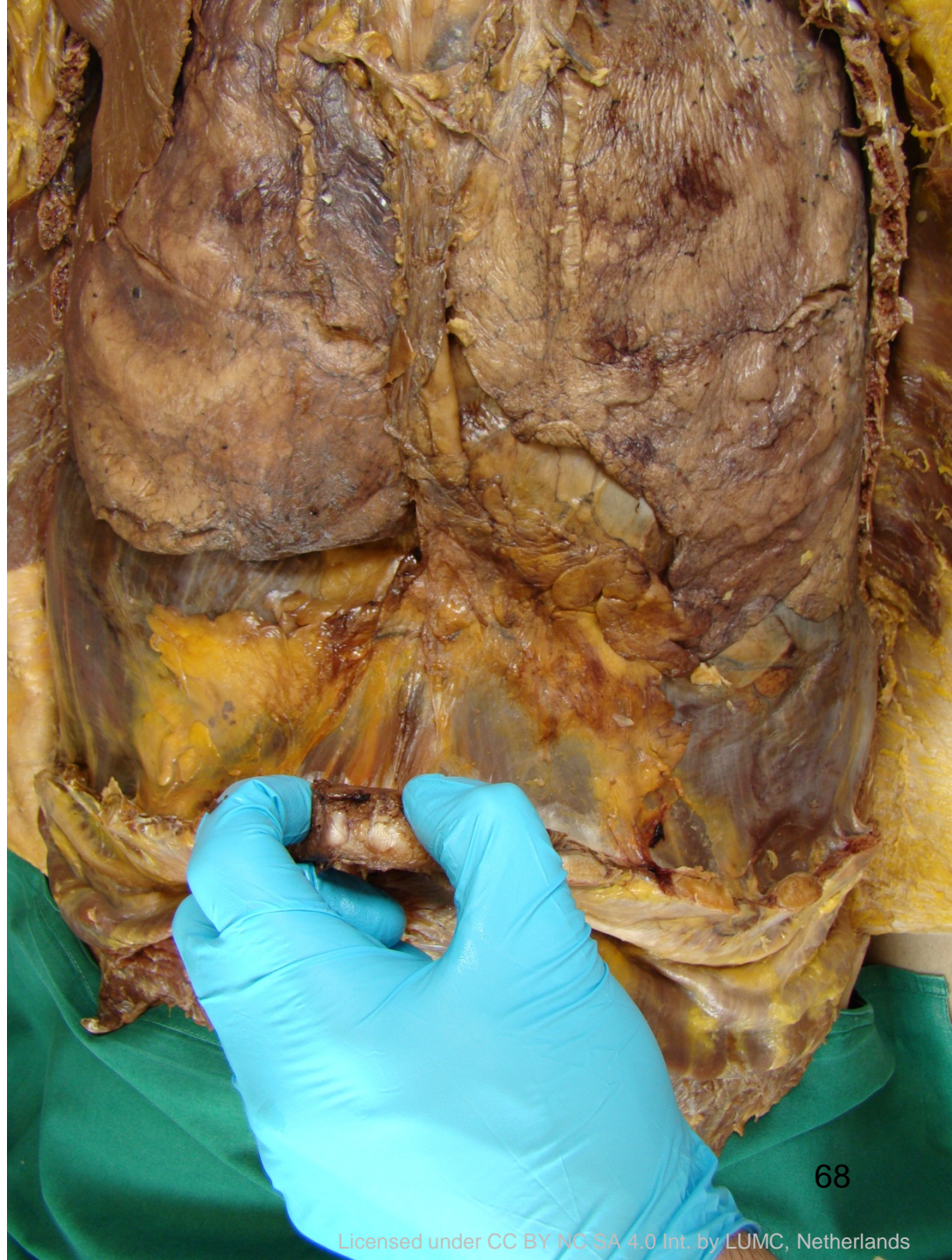- Intercostal artery

- Intercostal nerve

- 6th rib

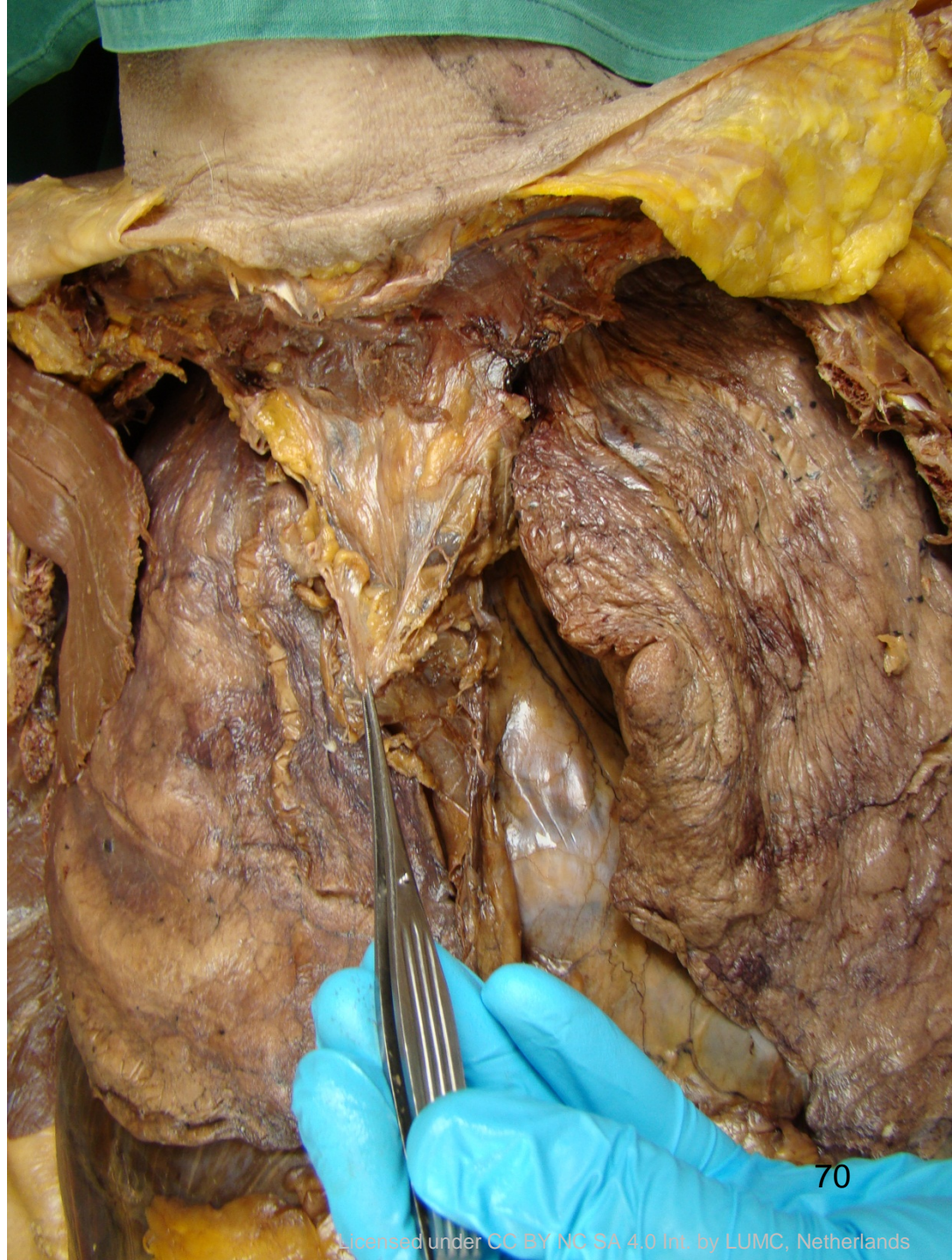

Attachment of xiphoid process of sternum to the diaphragm

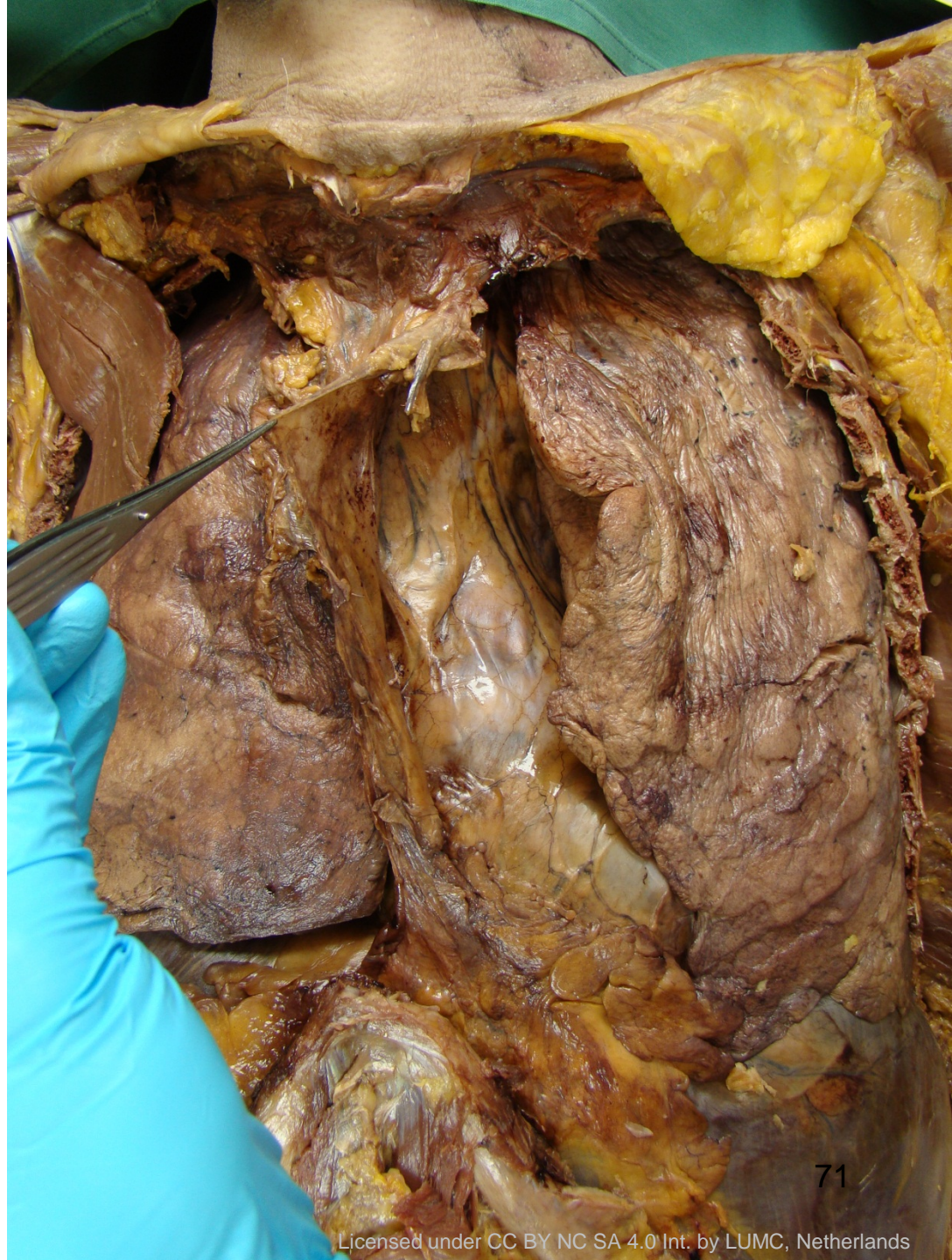

Inspection of the thorax

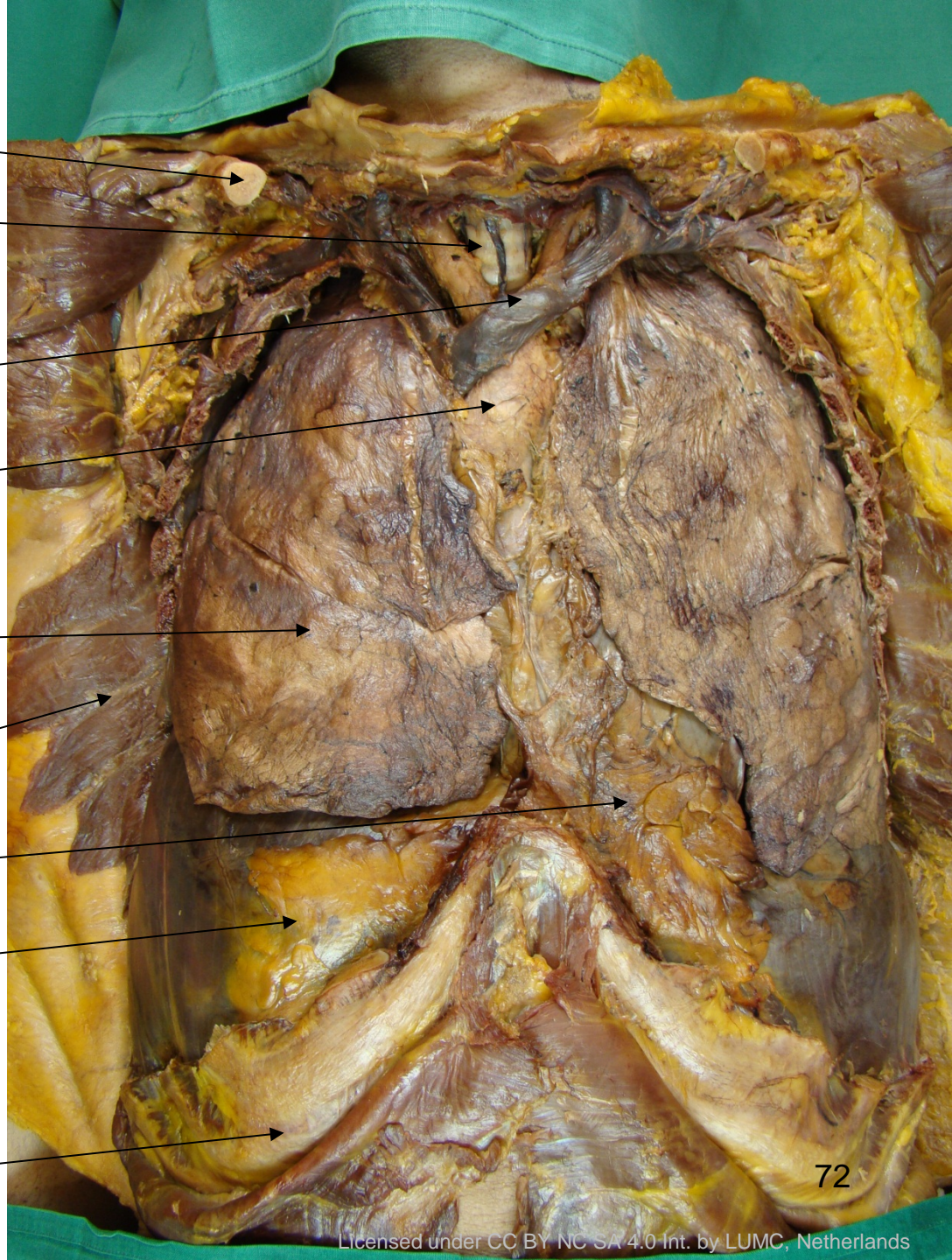- Thymus gland remnant



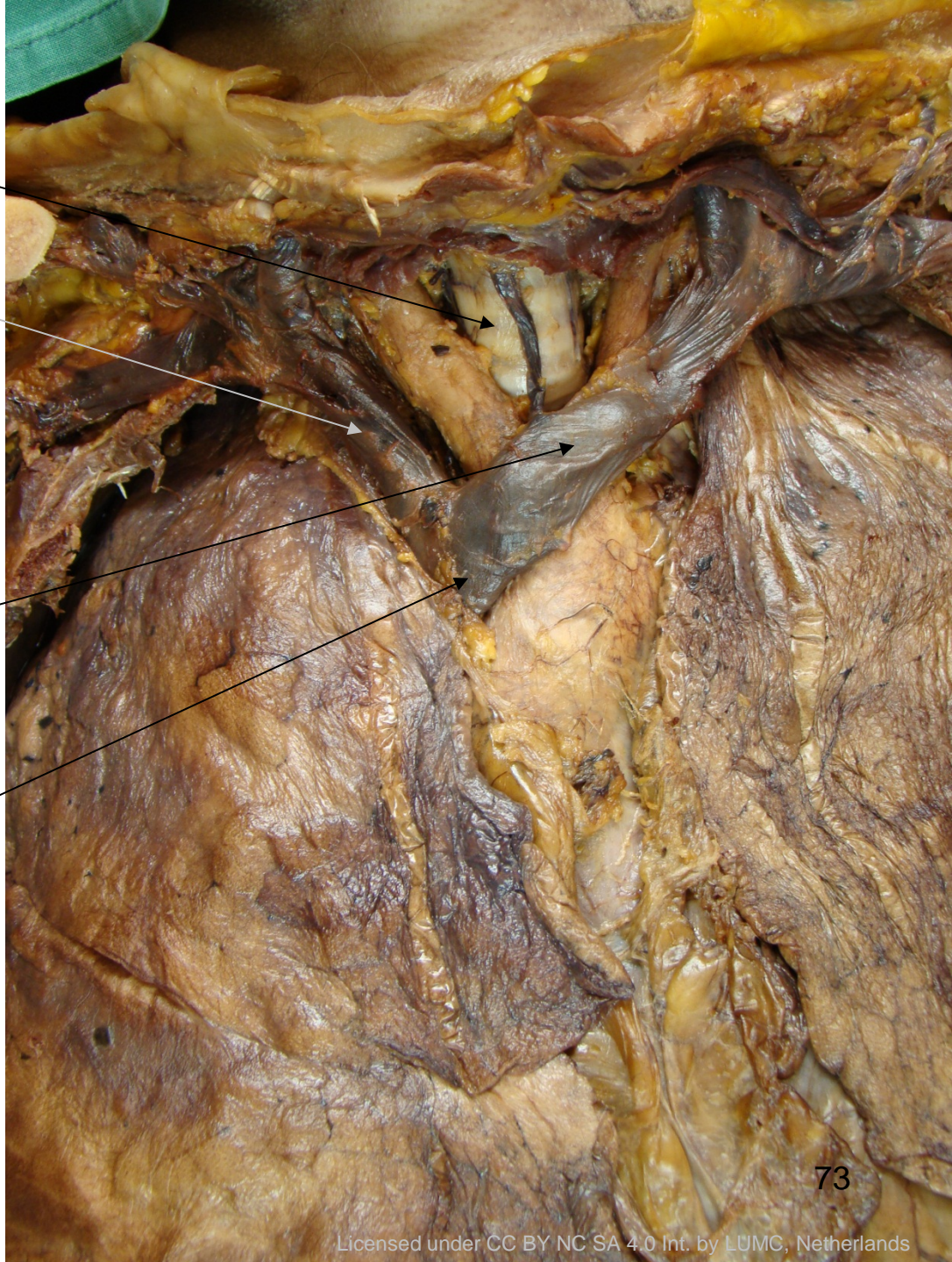Mediastinal part of
parietal pleura



- Clavicle
- Trachea
- Left brachiocephalic vein
- Aorta
- Right lung
- Serratus anterior m.
- Pericardium
- Right dome of diaphragm
- Costal margin

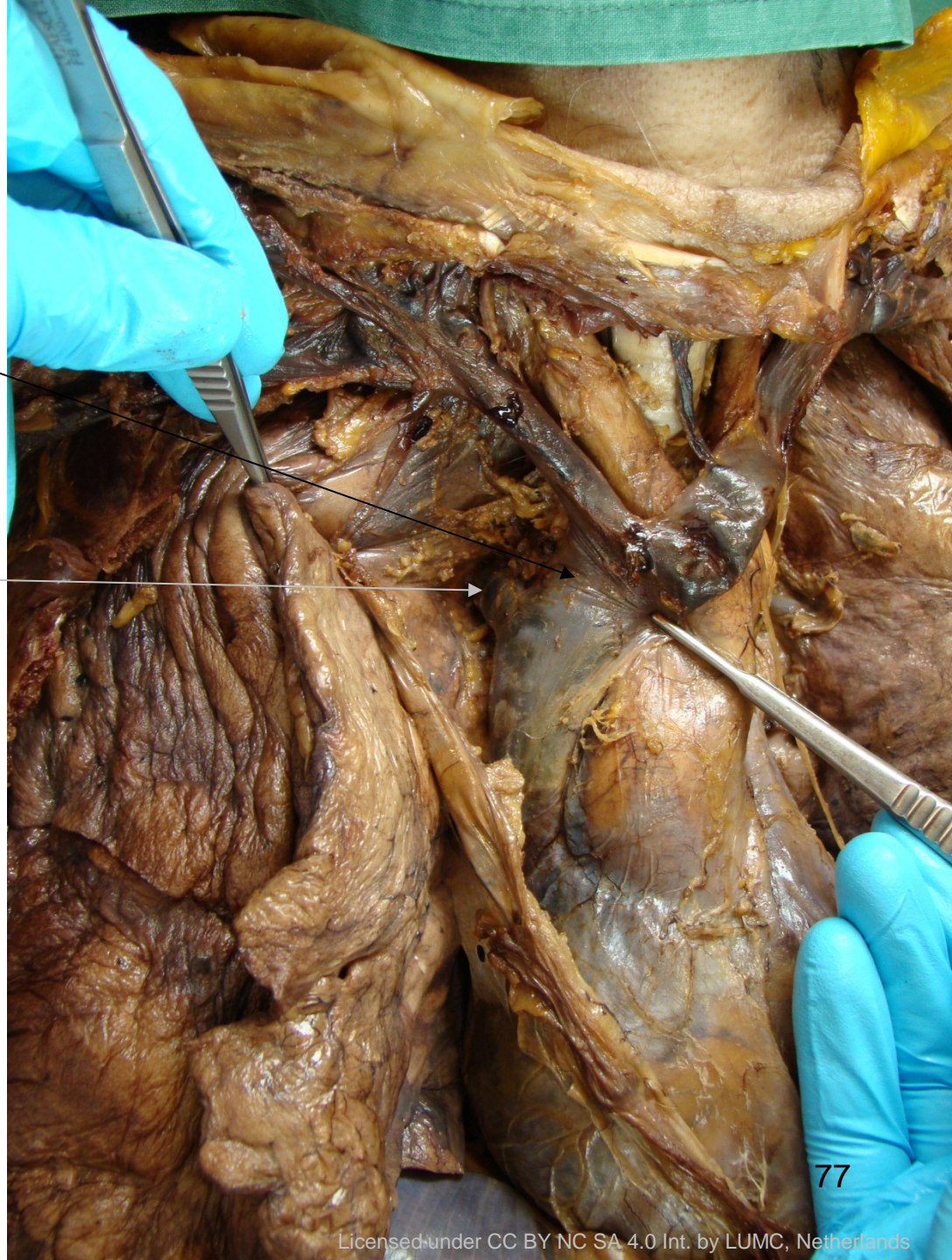

- Trachea
- Right brachio-cephalic vein
- Left brachio-cephalic vein
- Superior vena cava



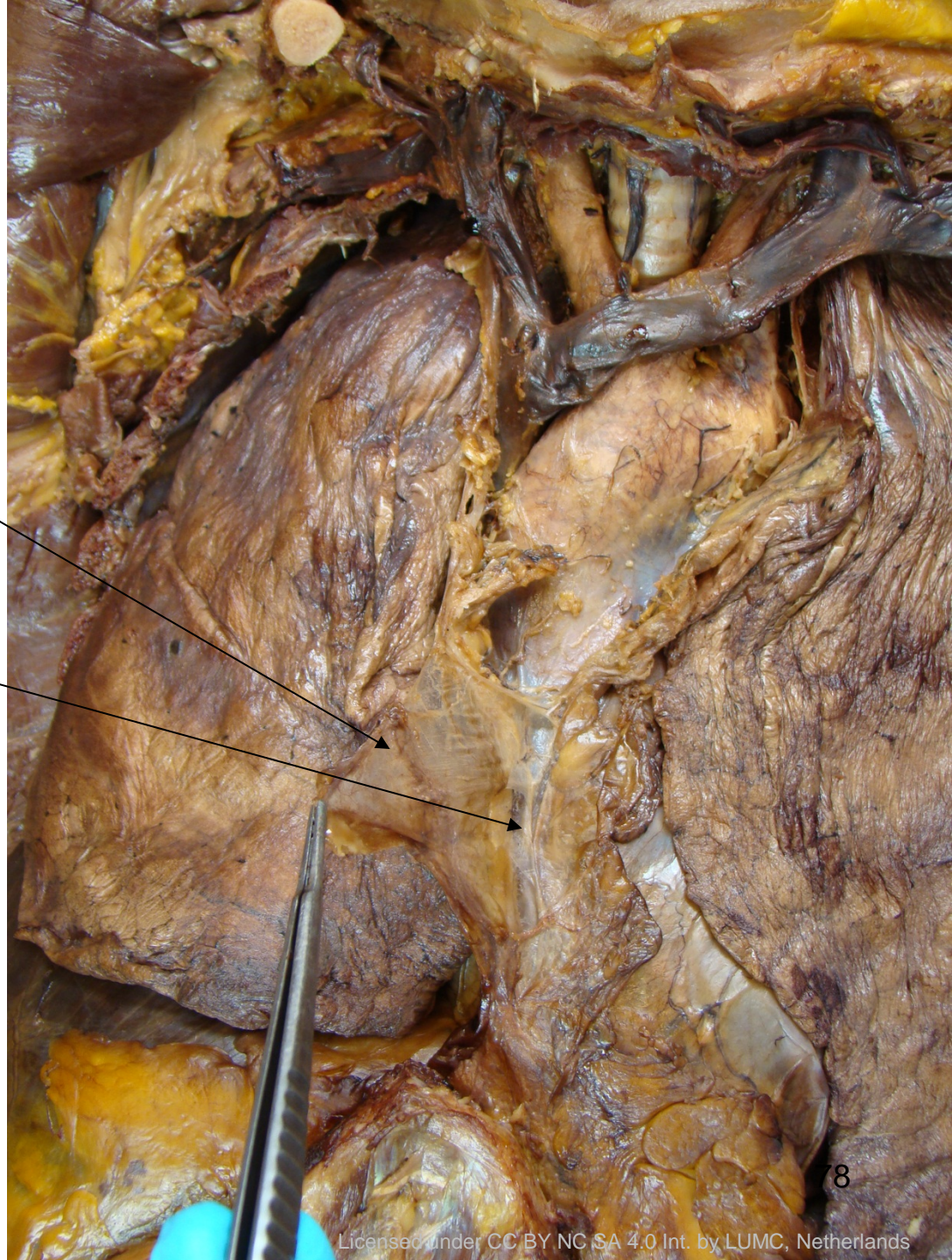- Superior vena cava

- Azygos vein



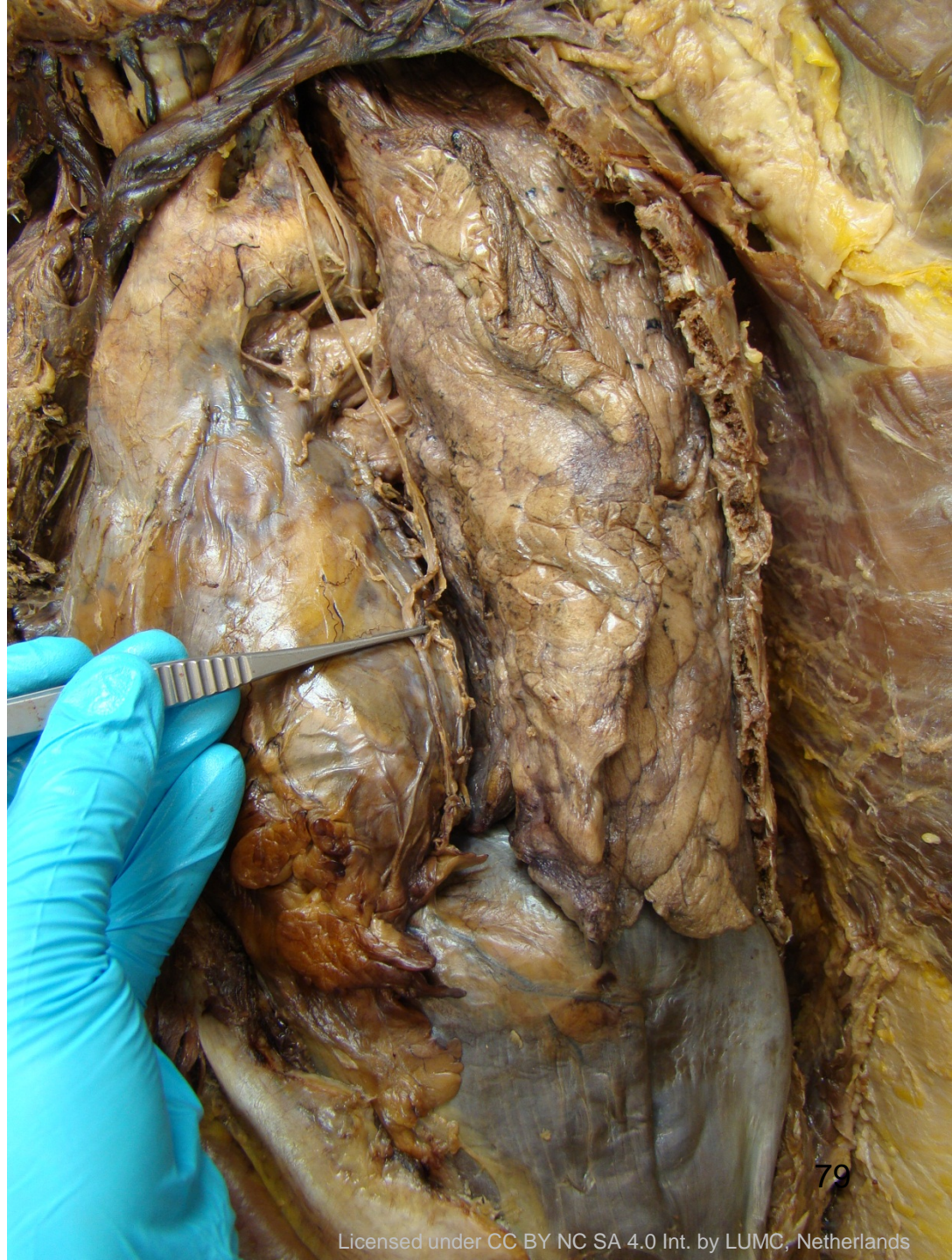- Mediastinal pleura

- Pericardium

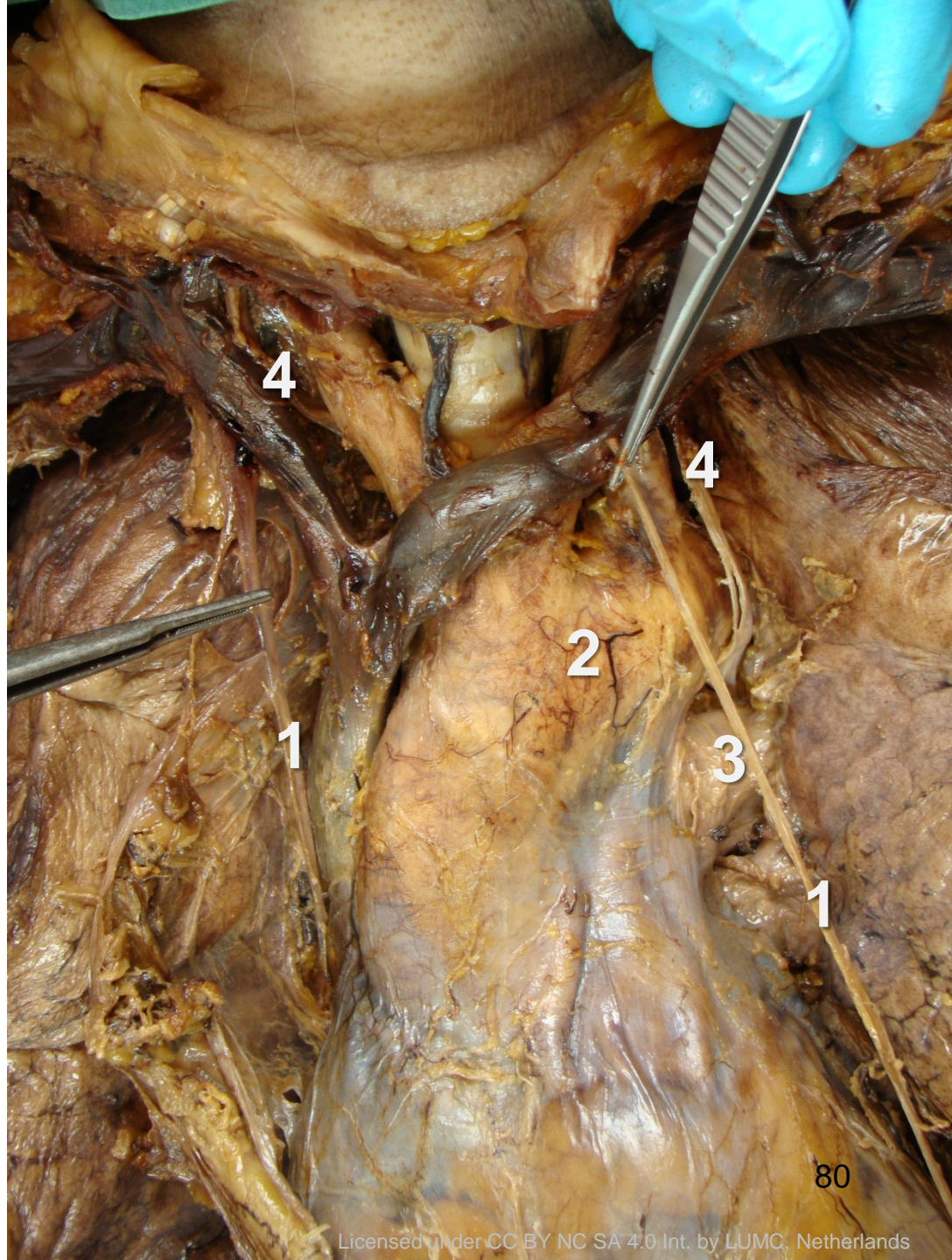


Left phrenic nerve

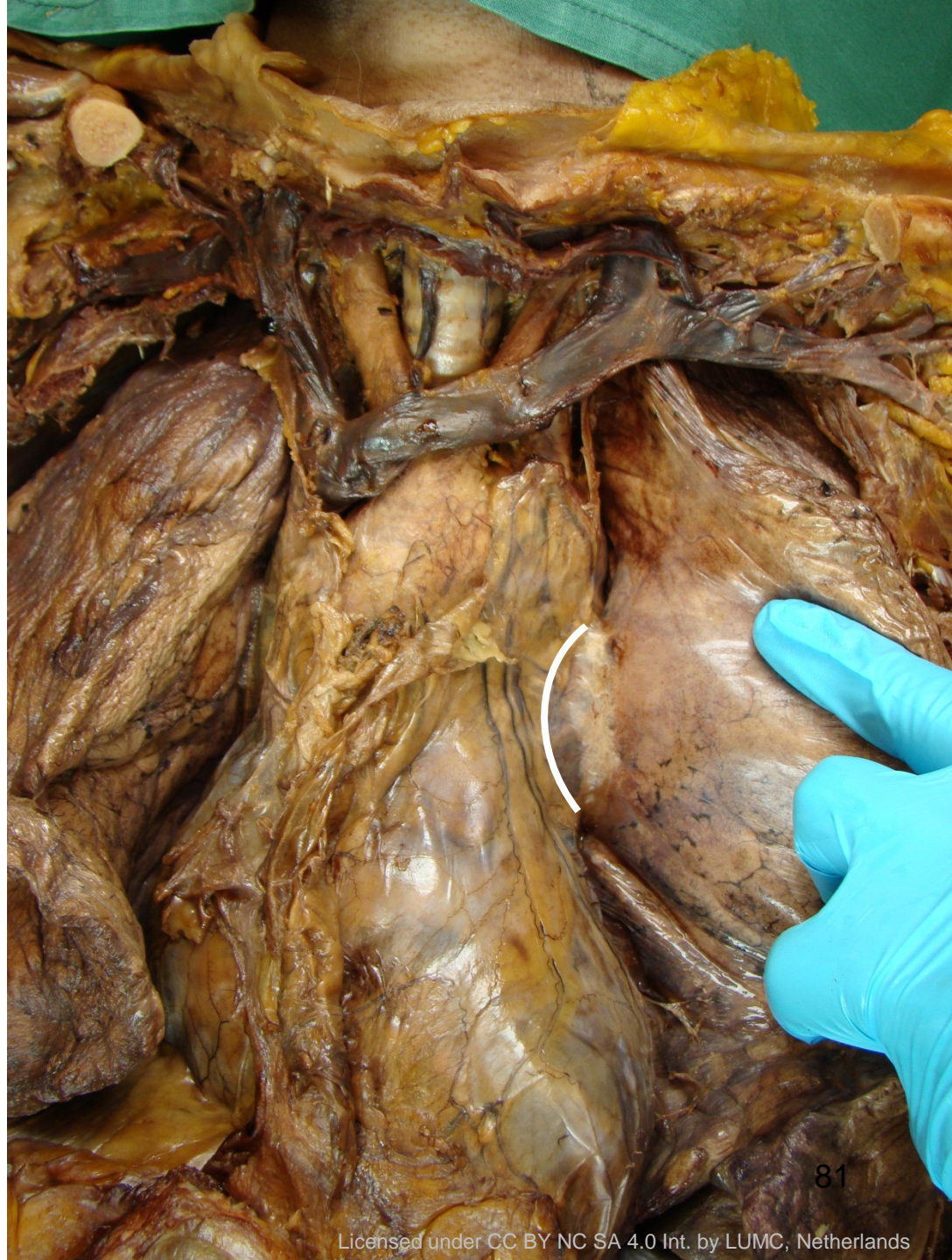Runs over pericardium
and reaches to
diaphragm



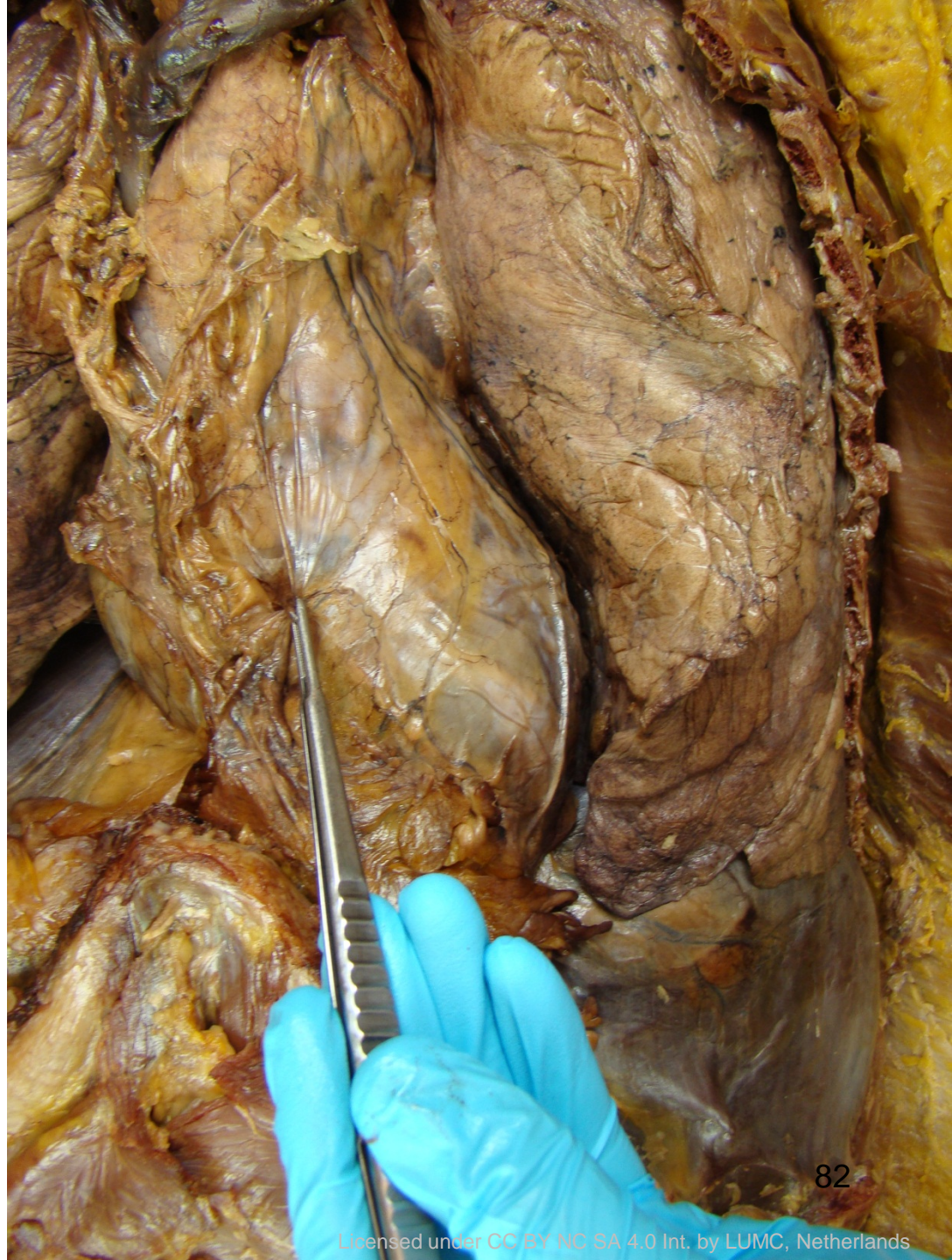1. Phrenic nerves
2. Aorta
3. Left pulmonary artery
4. Vagus nerve



- Left lung hilum



- Pericardium



- Left brachiocephalic vein
- Left subclavian artery
- Arcus aortae
- Left vagus nerve
- Left recurrent laryngeal nerve
- Pulmonary artery



- Left side:

- Aortic arch

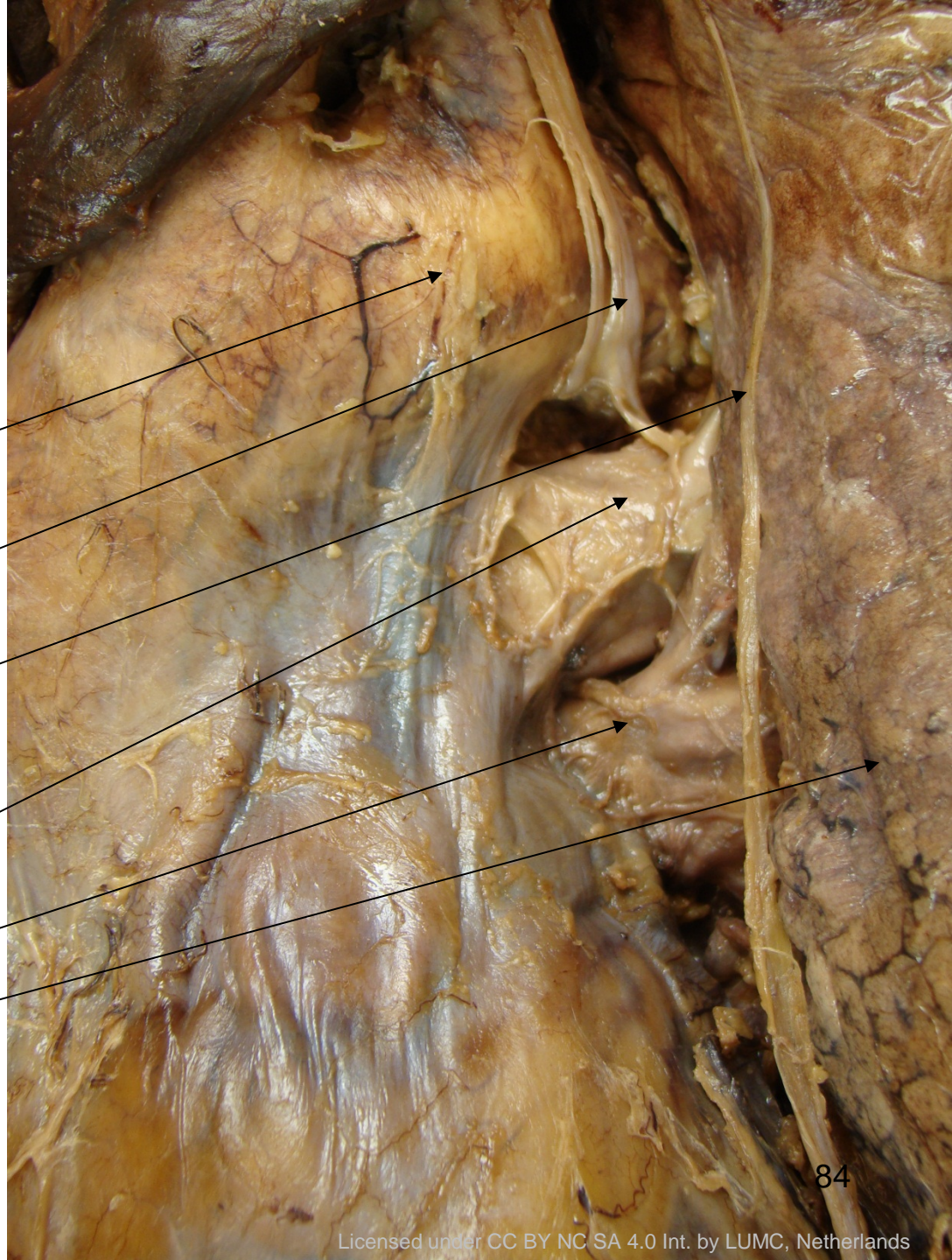- Vagus nerve

- Phrenic nerve

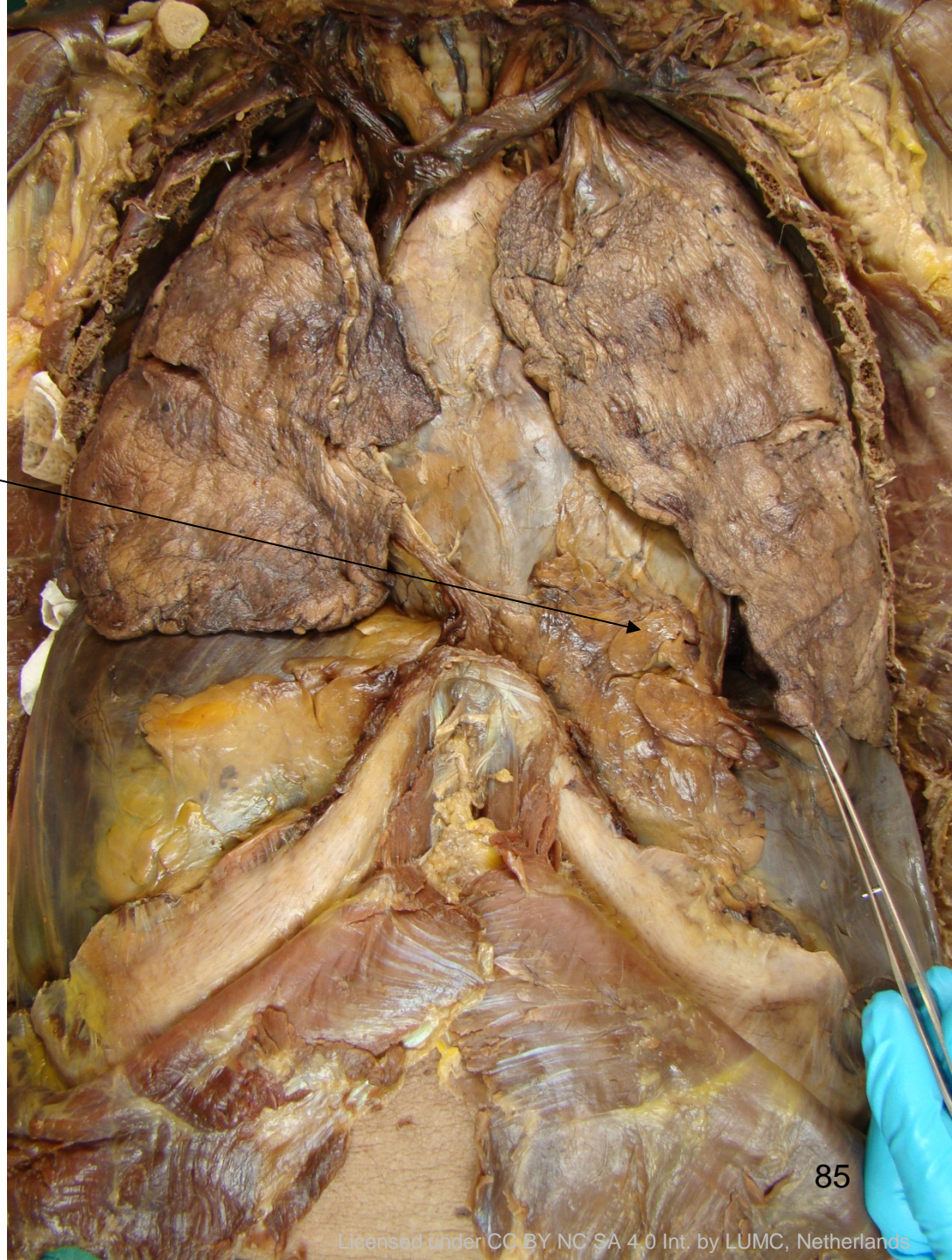
- Pulmonary artery

- Pulmonary veins

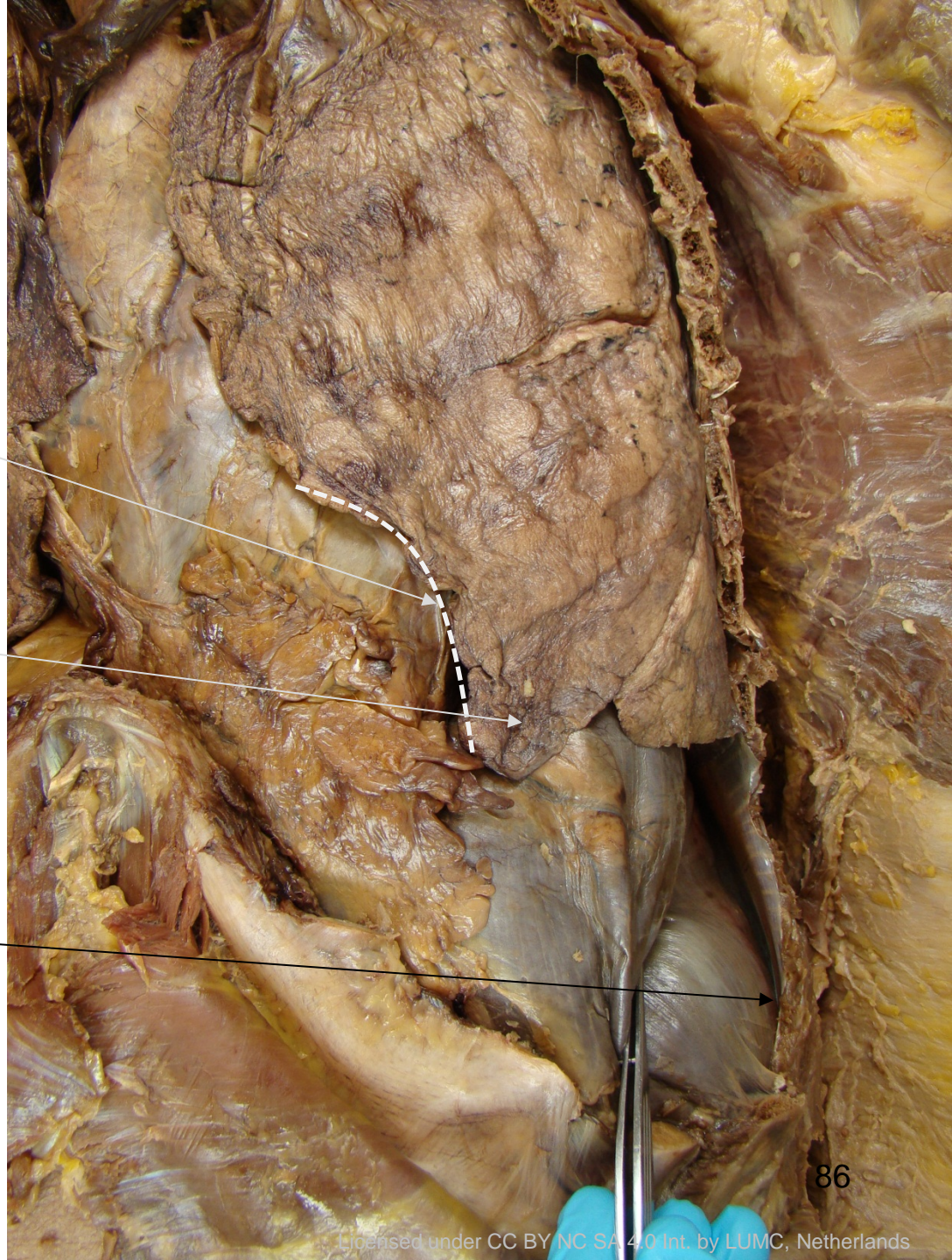- lung



- Costo-mediastinal recess

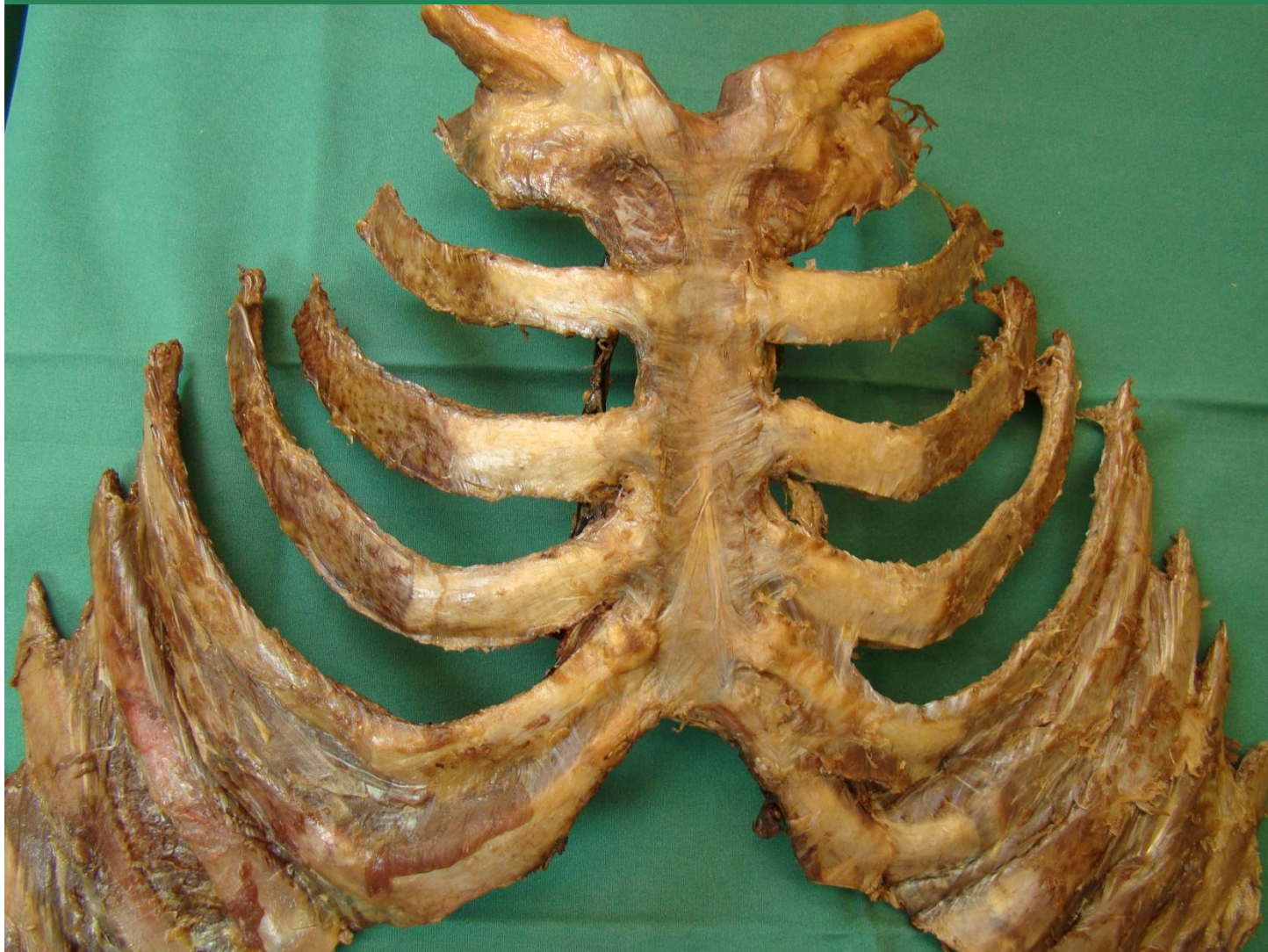

- Cardiac notch of left lung (incisura cardiaca)
- Lingula of left lung
- Costo-diaphragmatic recess

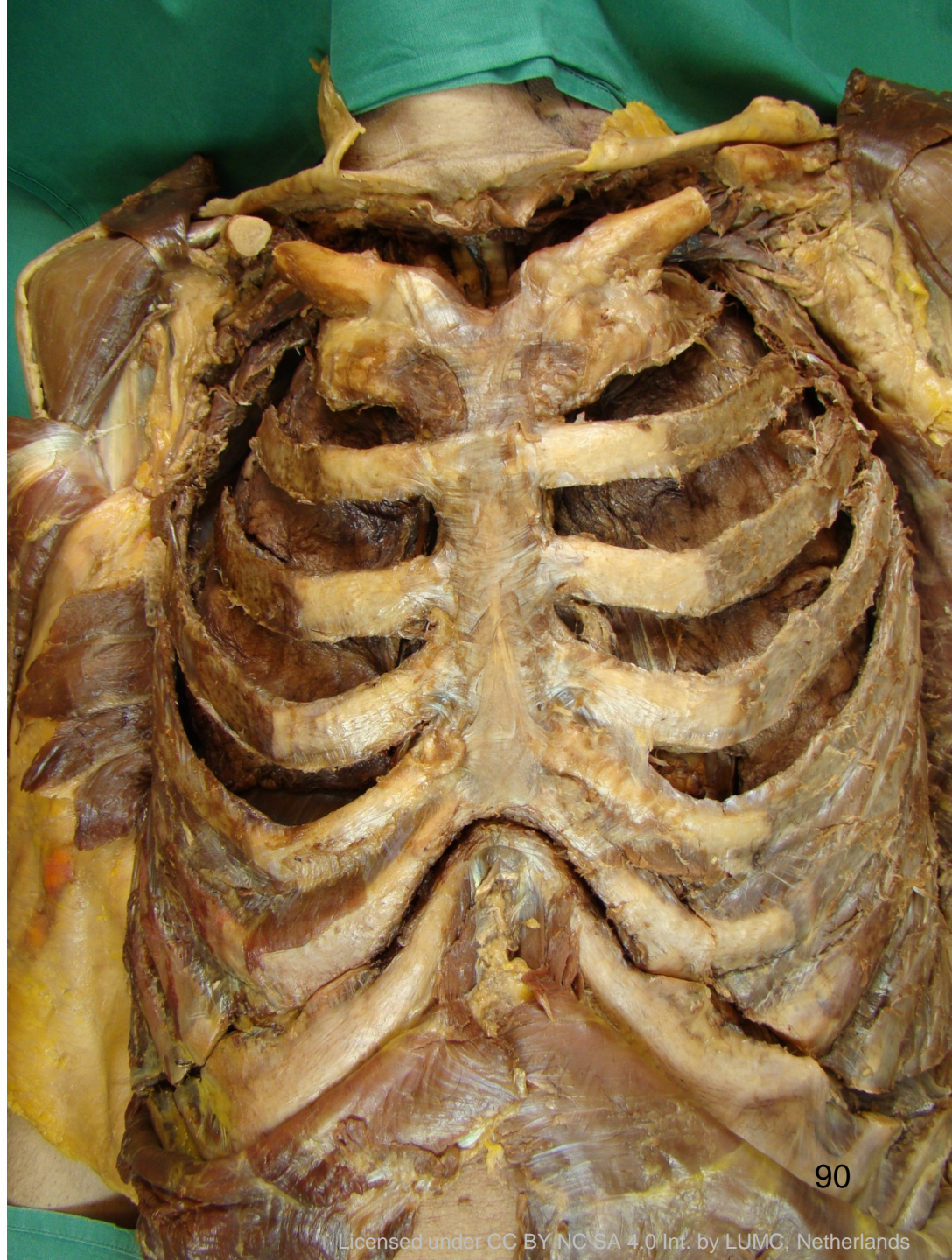


Inspection of heart and lungs

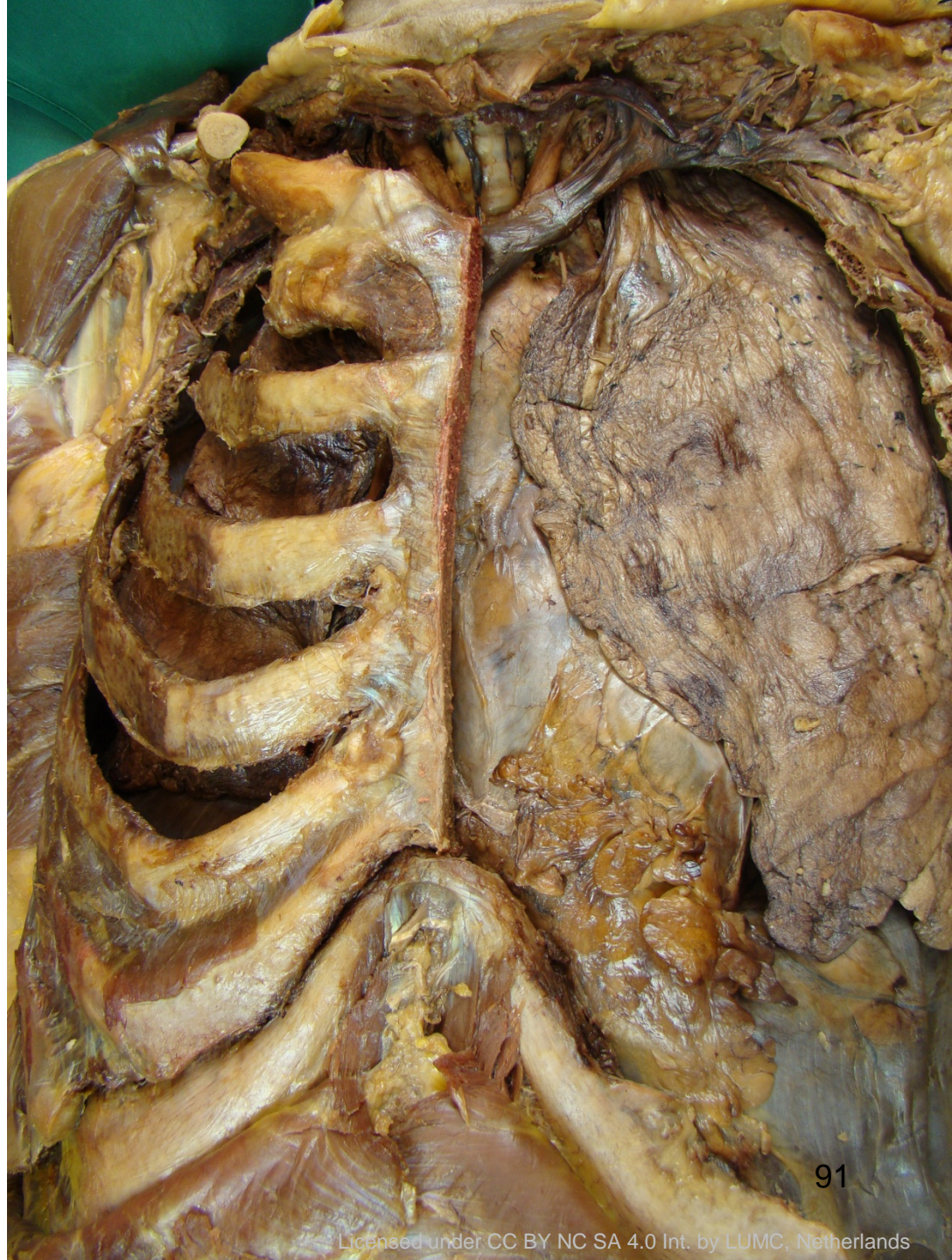Intercostal muscles are removed to show the projection of the intra thoracic organs



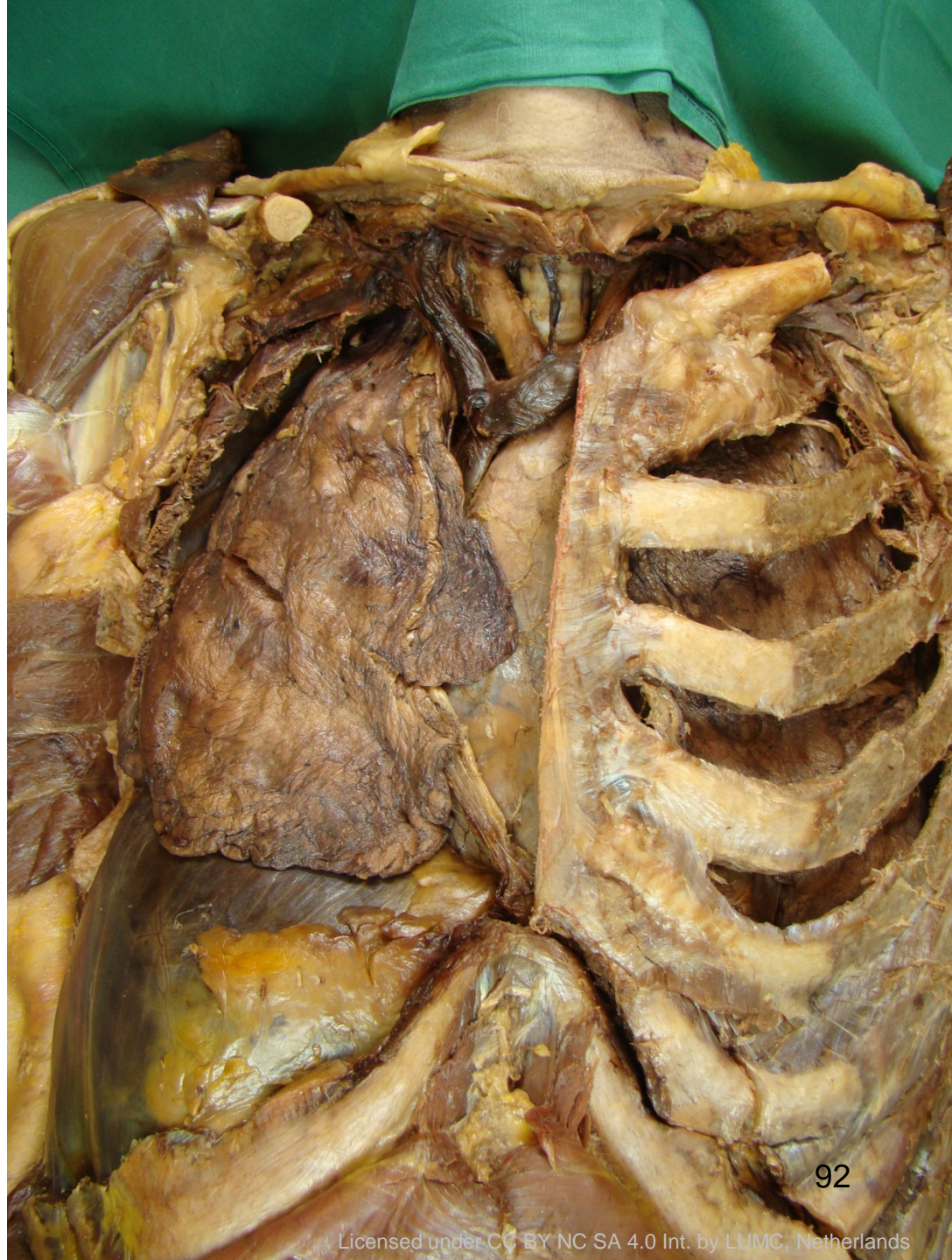
Surface projection of the lungs and heart through the rib cage



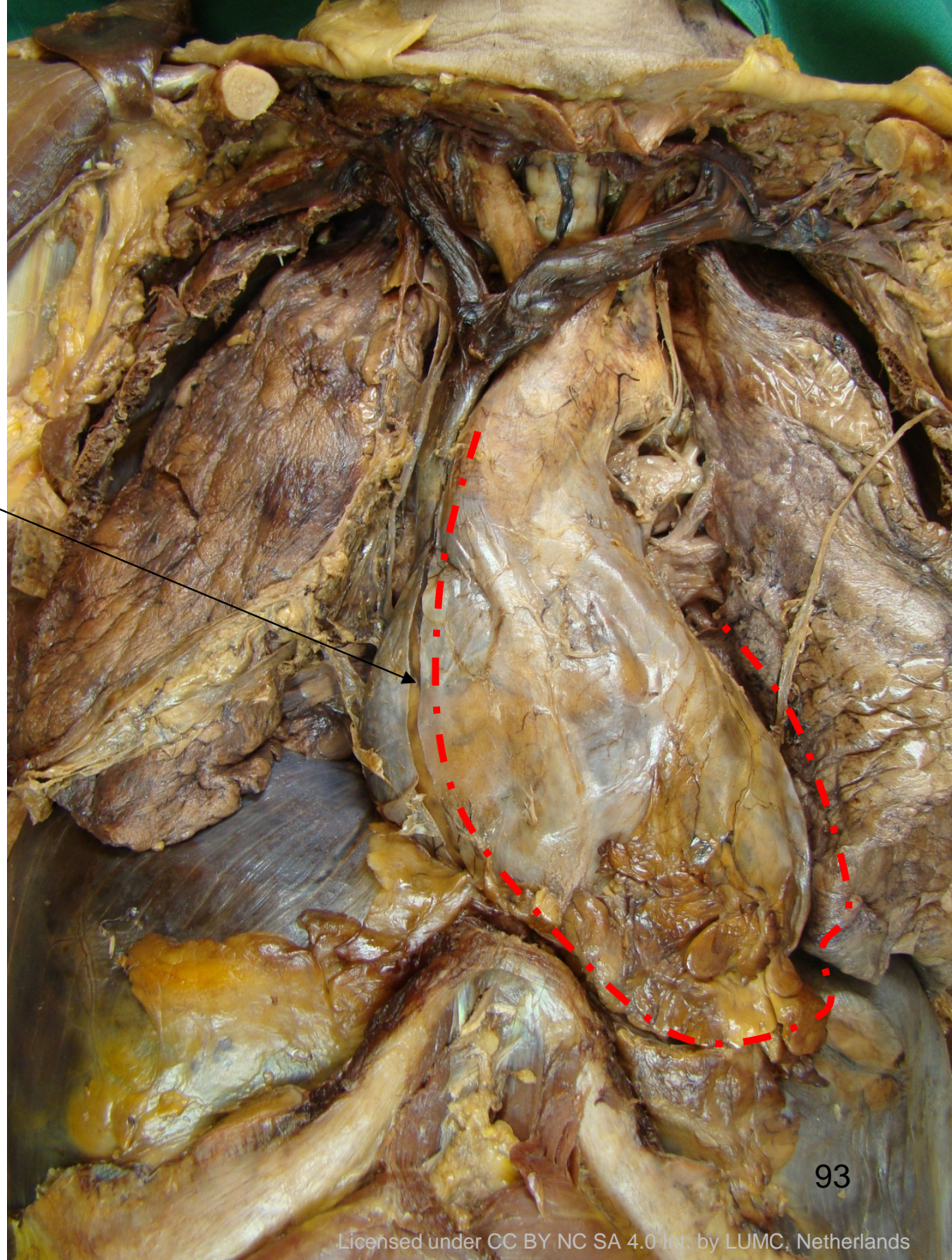
Observe the relationship between sternal body and pericardium, left side removed



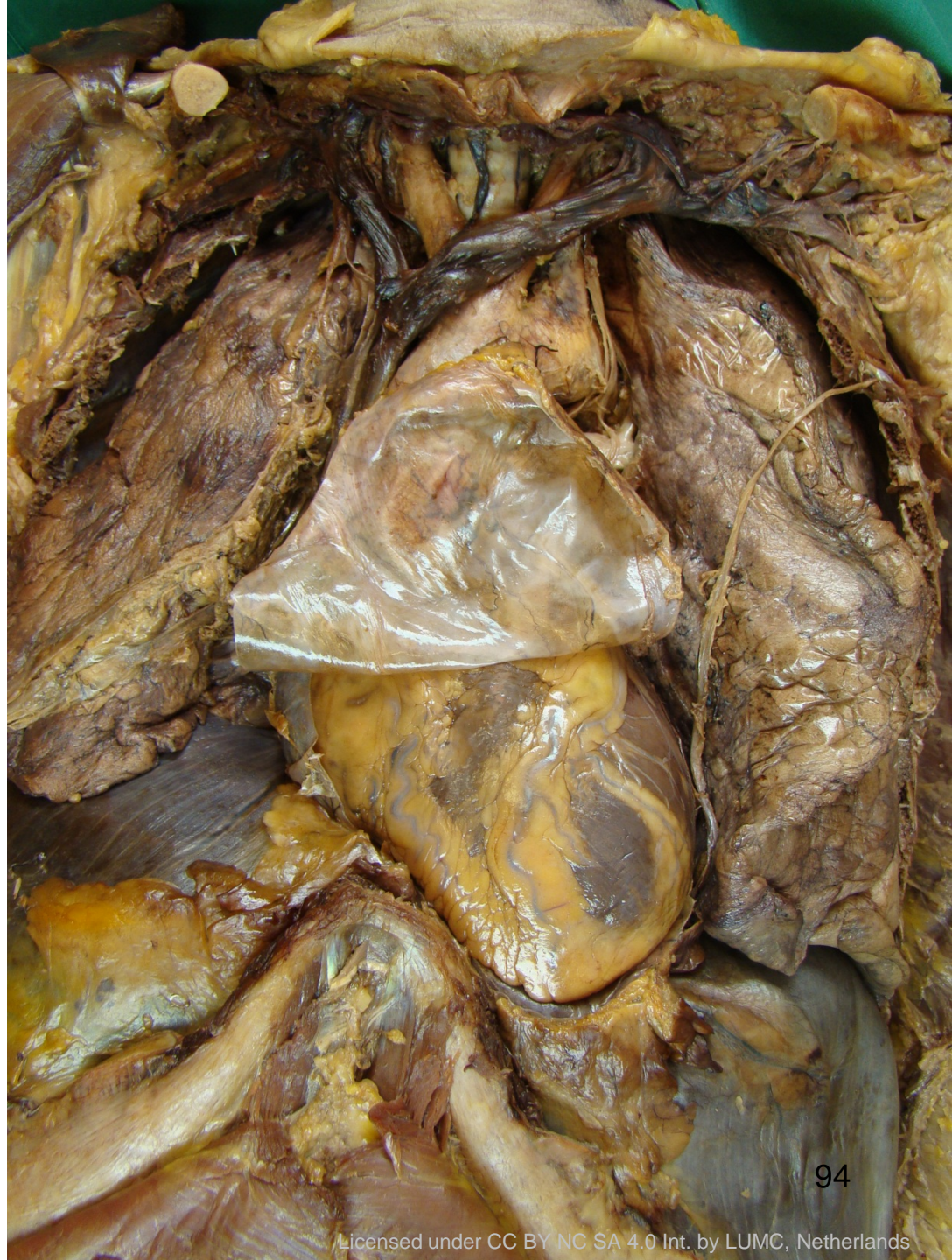Observe the relationship between sternal body and pericardium, right side removed



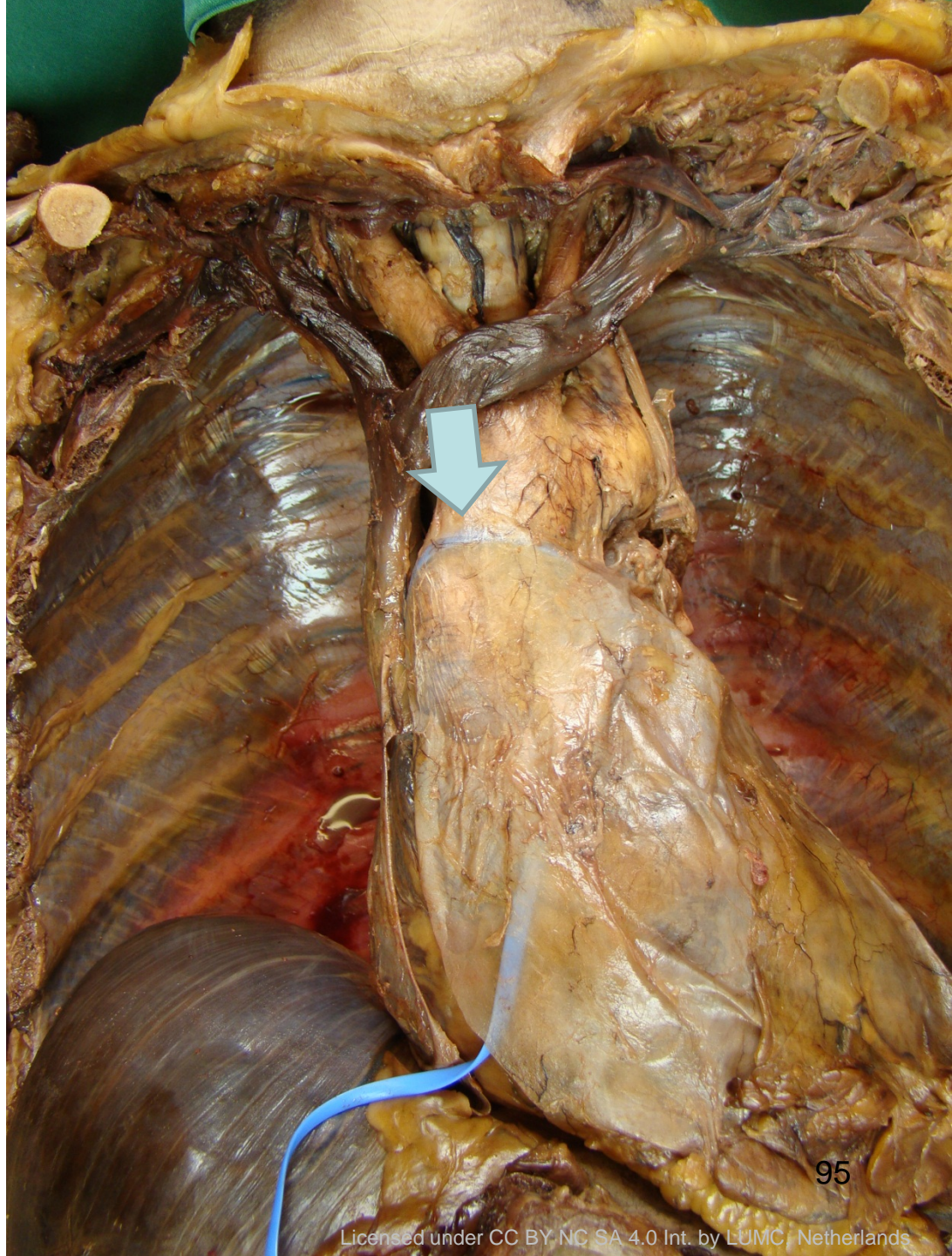
Pericardial opening line



Pericardium opened and reflected

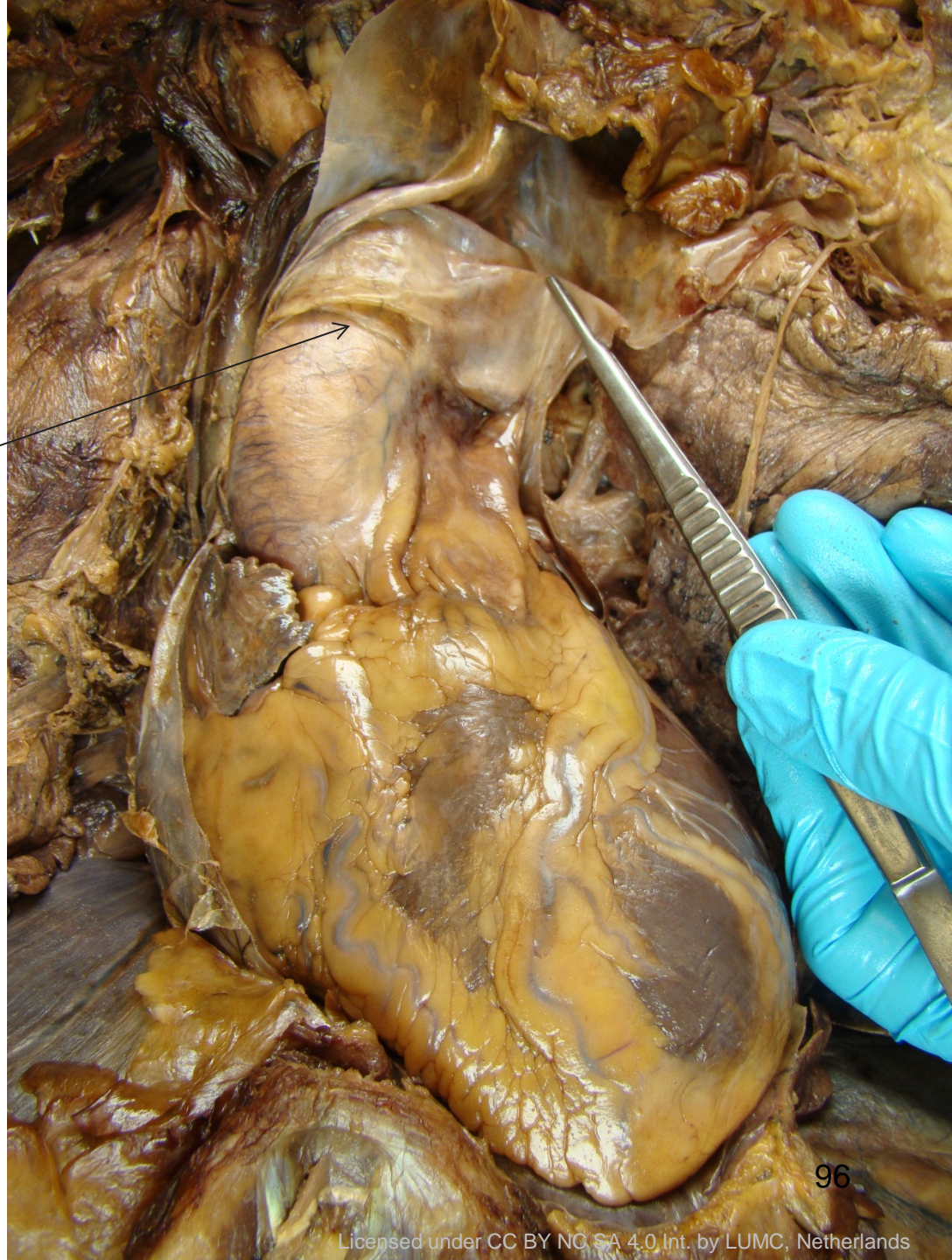


Epi-pericardial reflection
on the great vessels



Pericardium opened
and reflected

Epi-pericardial
reflection on great
vessels



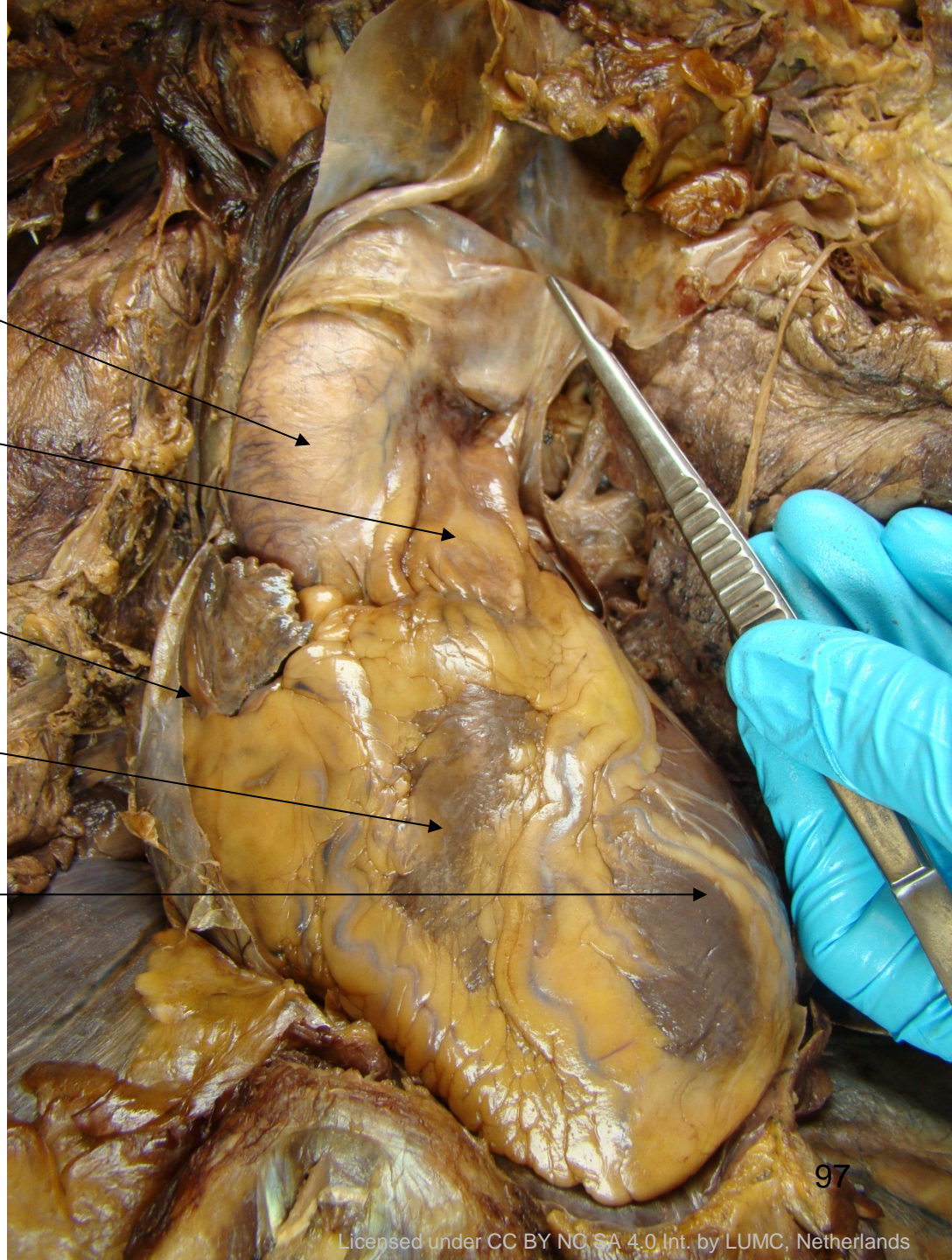
Ascending aorta ▲

- Pulmonary trunk

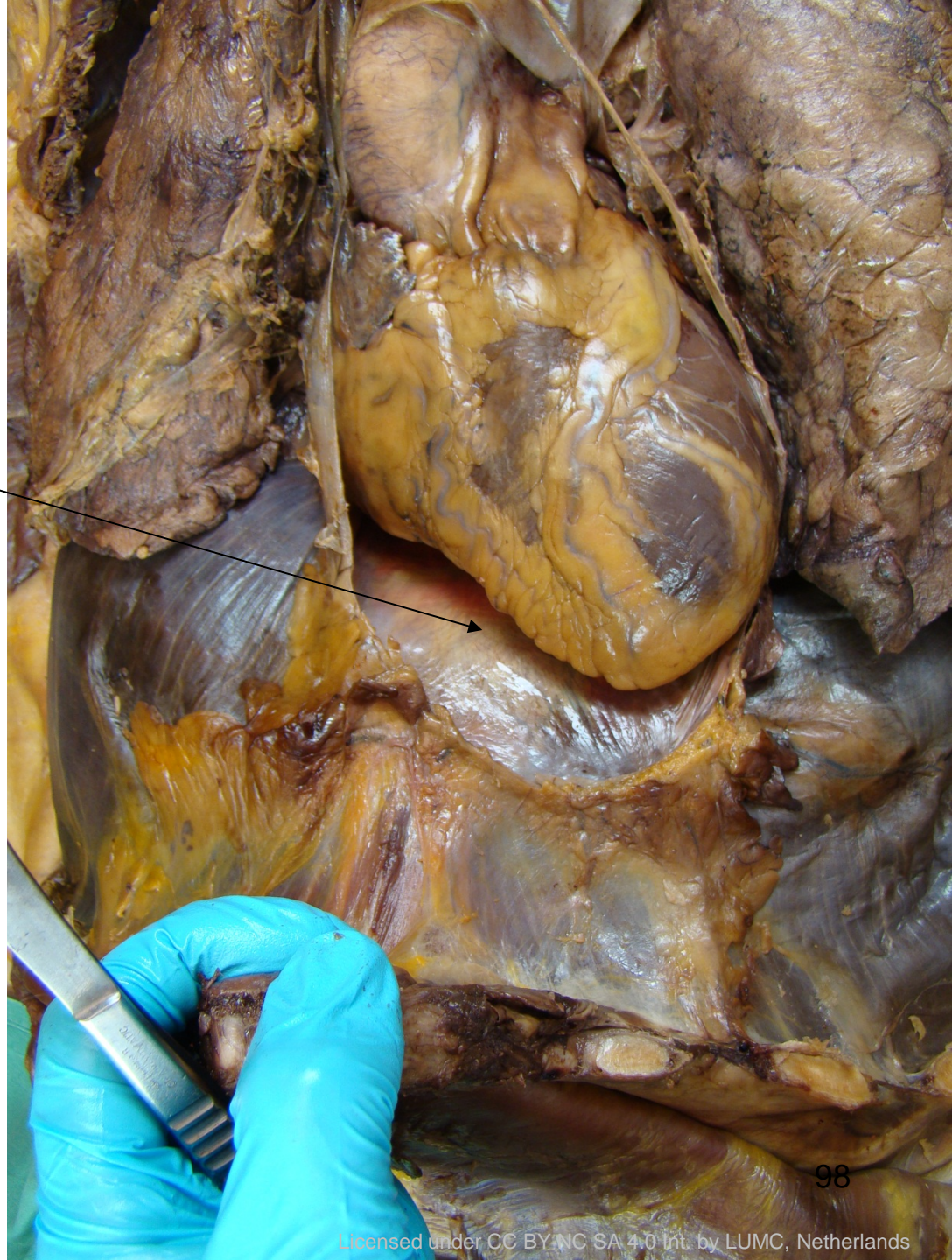- Right atrium

- Right ventricle

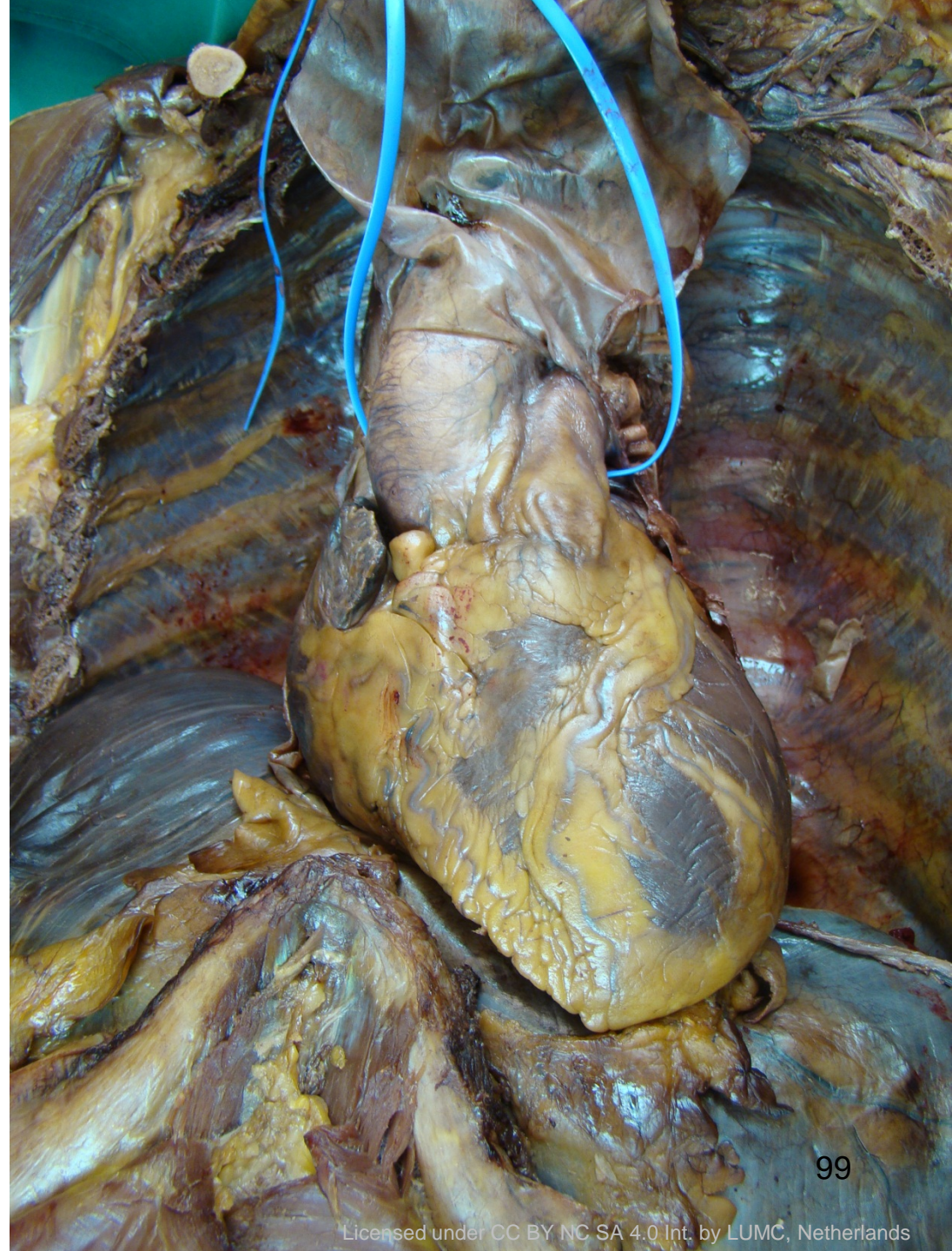- Left ventricle



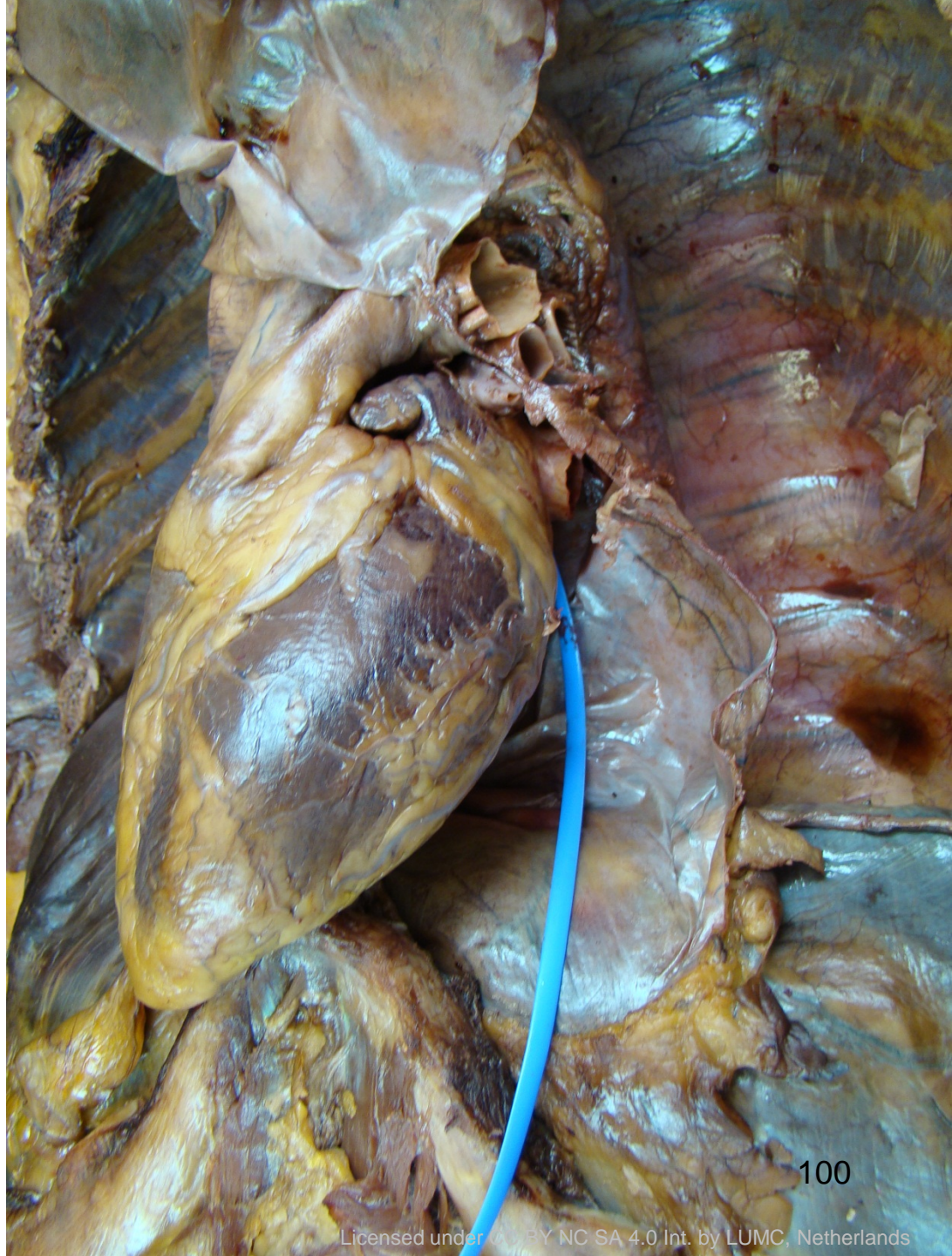Central tendon of diaphragm (centrum tendineum)



Vessel loop in
transverse pericardial
sinus

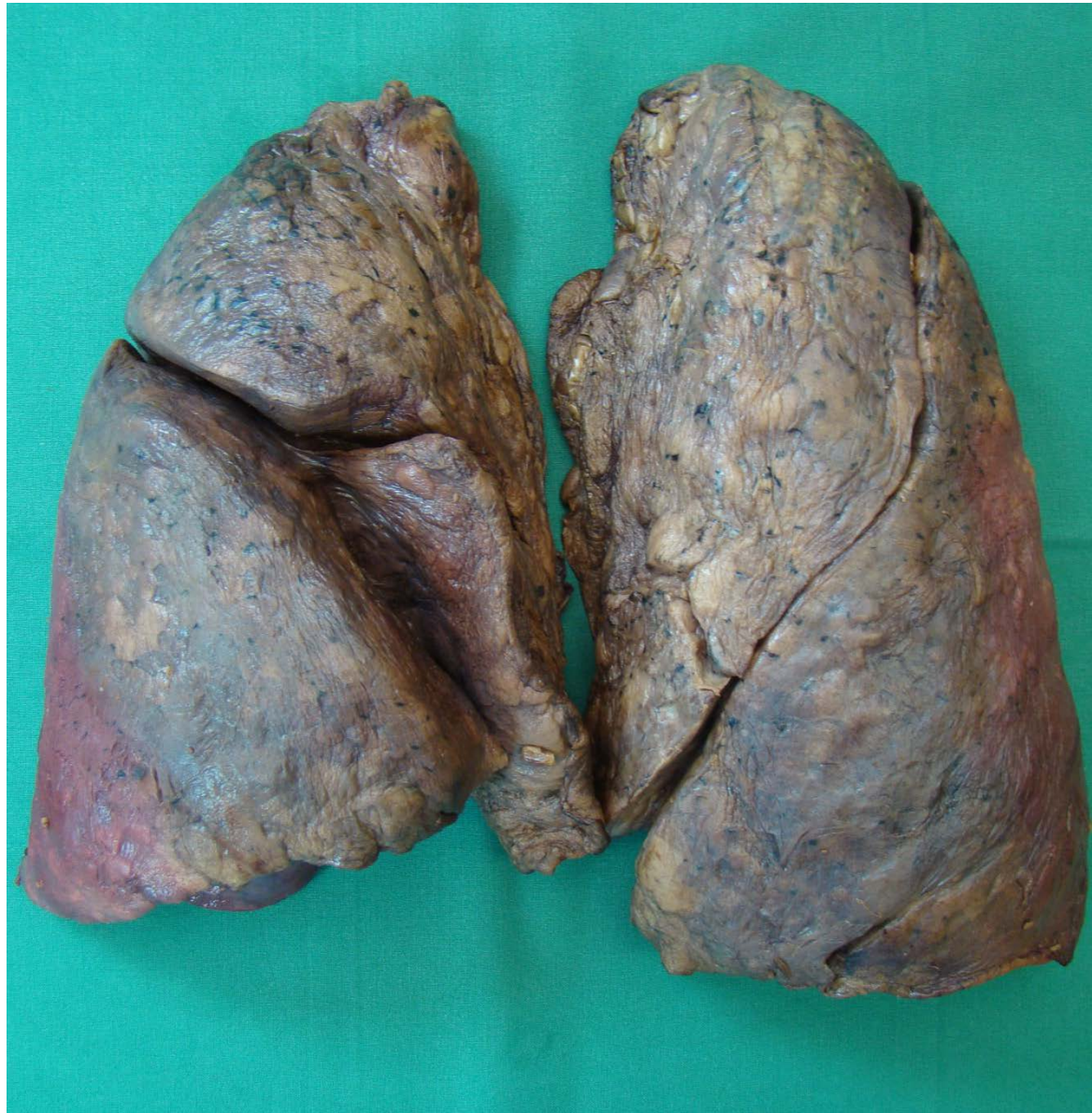

Vessel loop in
oblique pericardial sinus

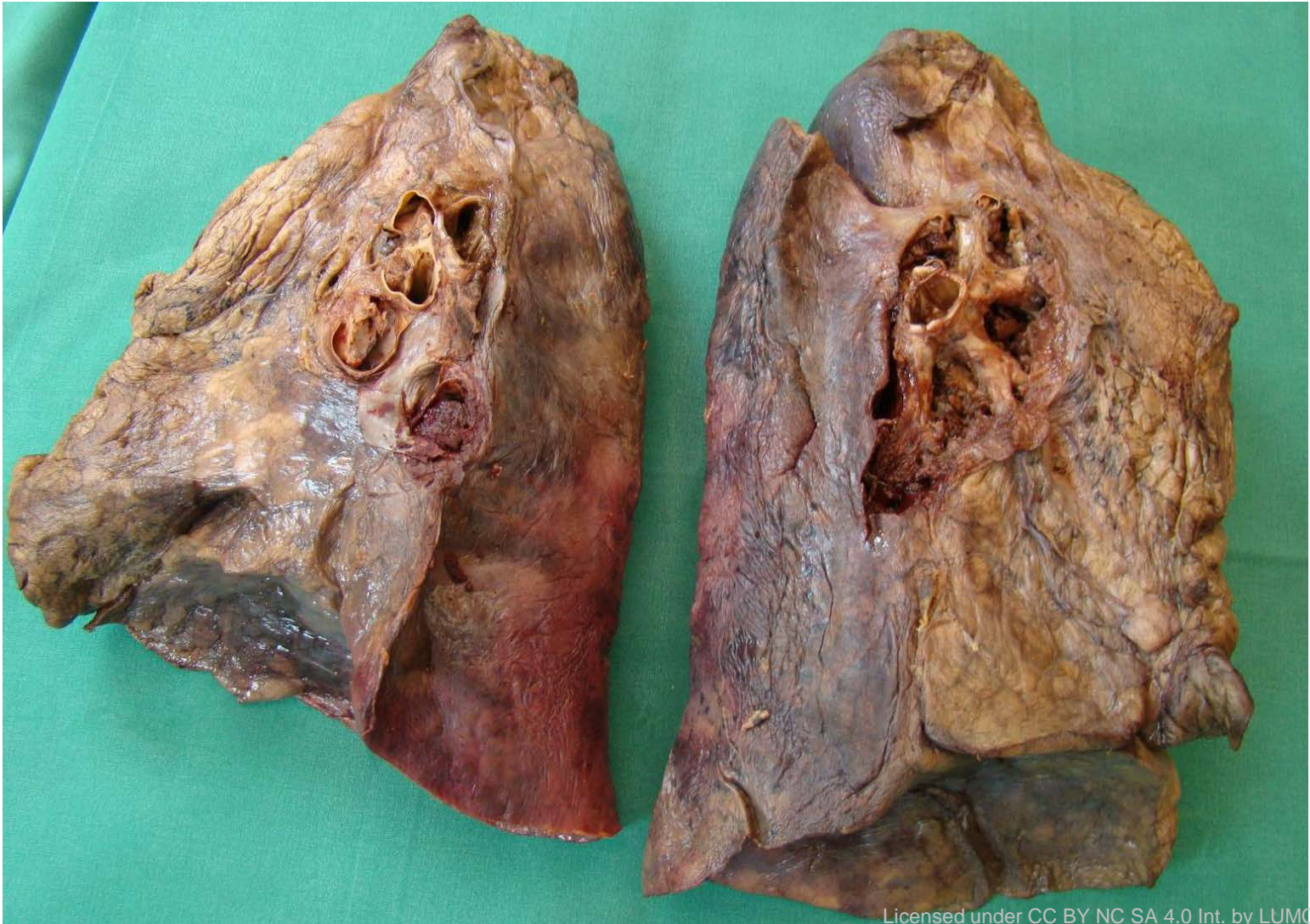

Dissection of the lungs

Compare right and left lungs



Mediastinal surface



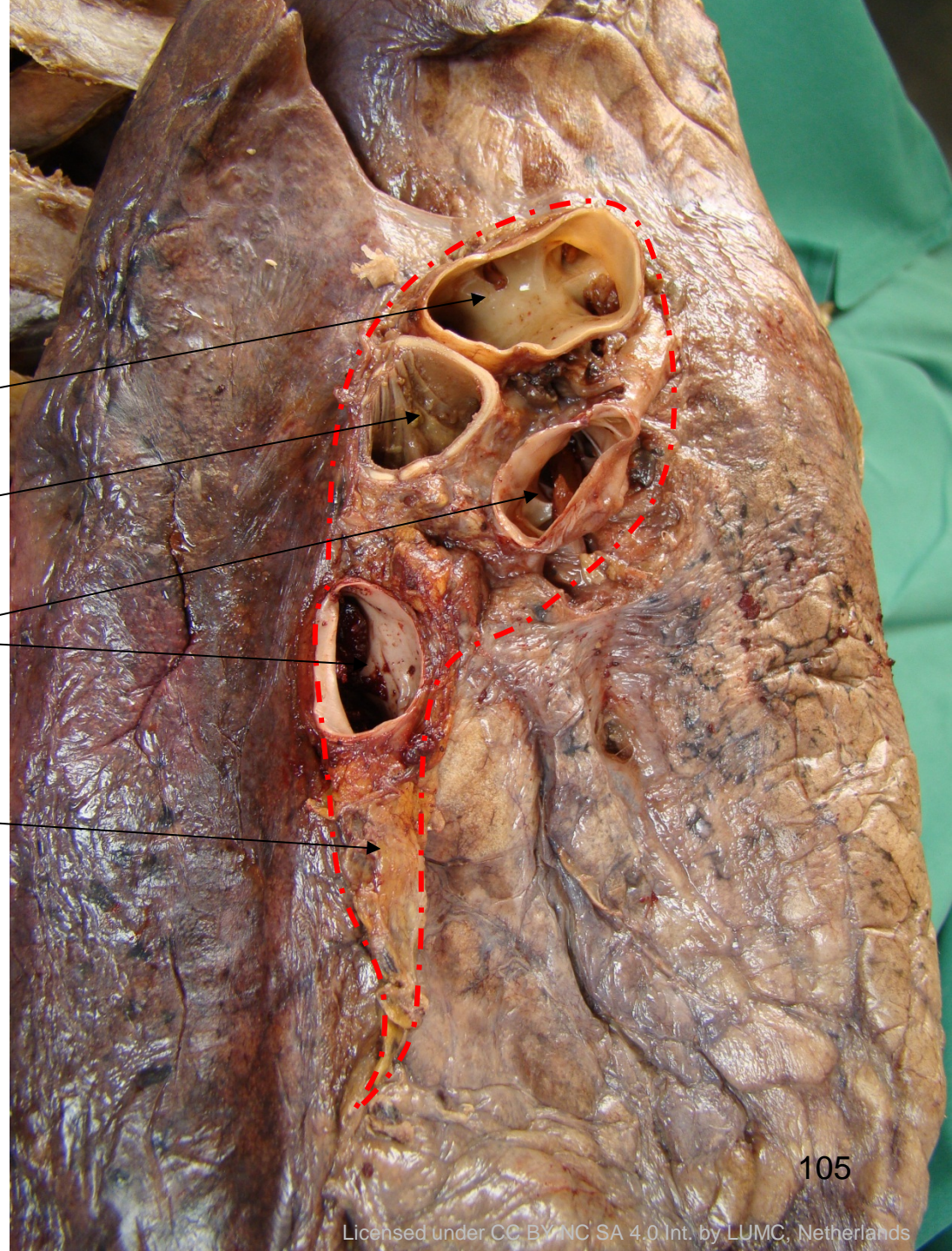
- Left lung hilum

- Pulmonary artery

- Main bronchus

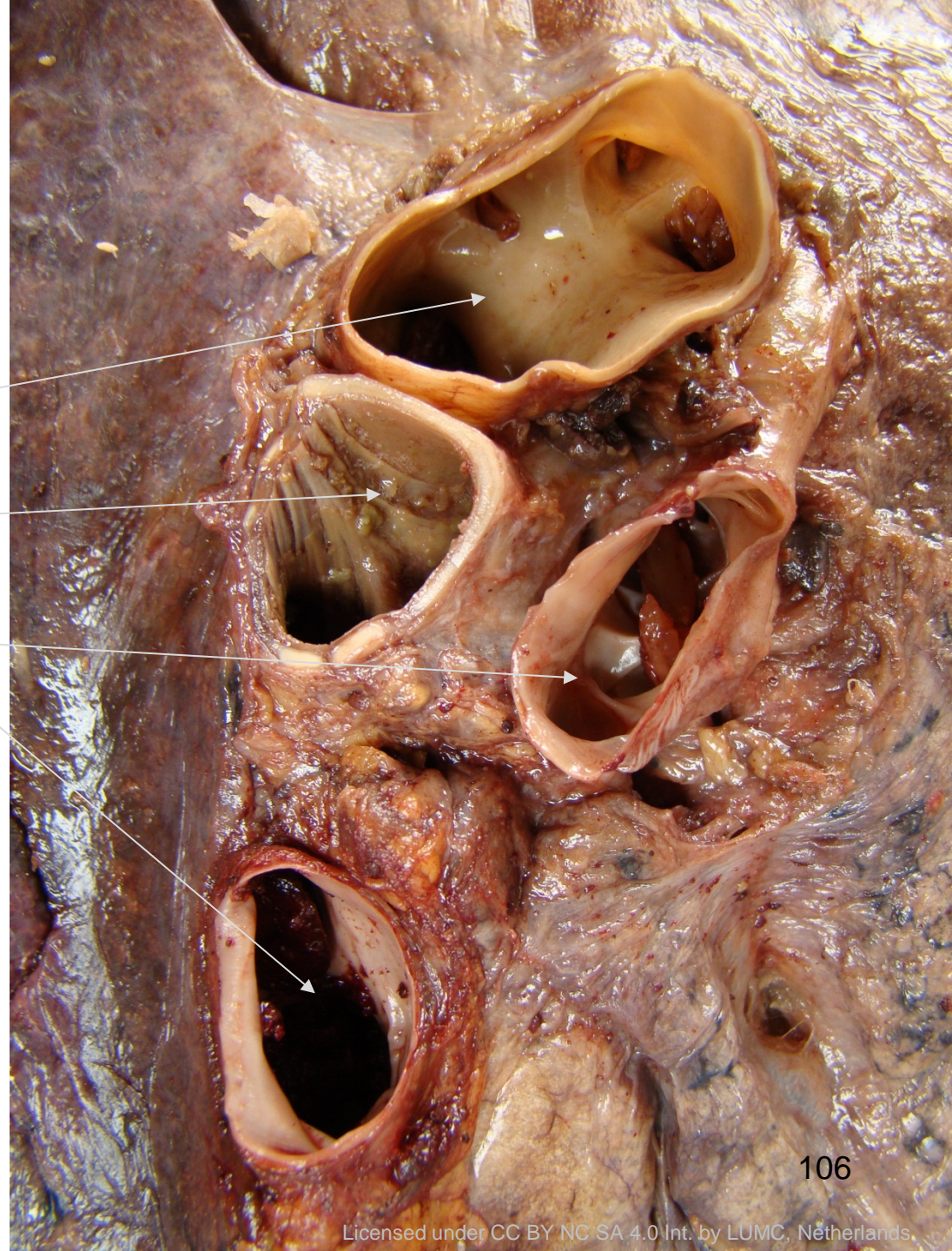
- Pulmonary veins

- Pulmonary ligament

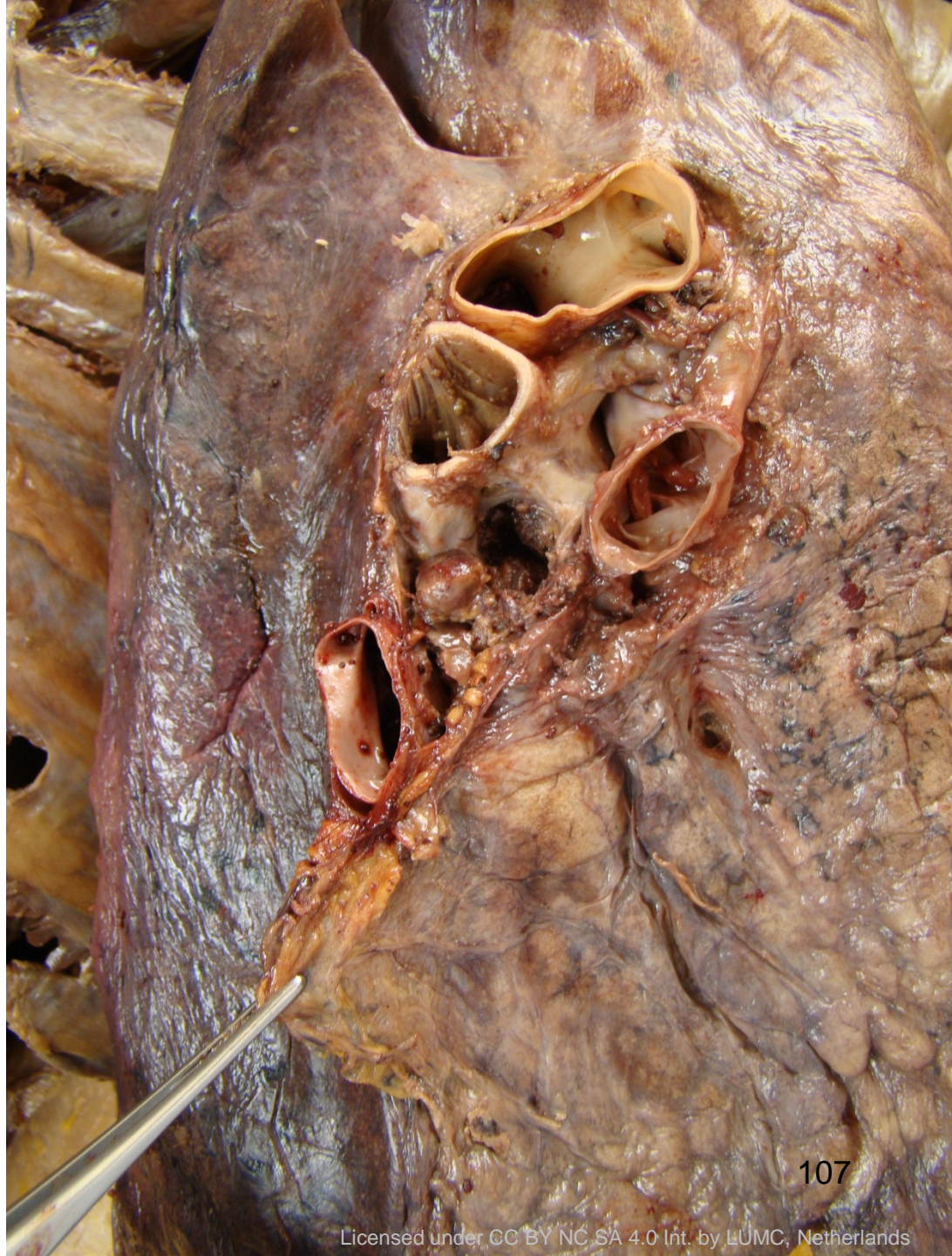

Close up

- Left lung hilum
 - Pulmonary artery
 - Main bronchus
 - Pulmonary veins



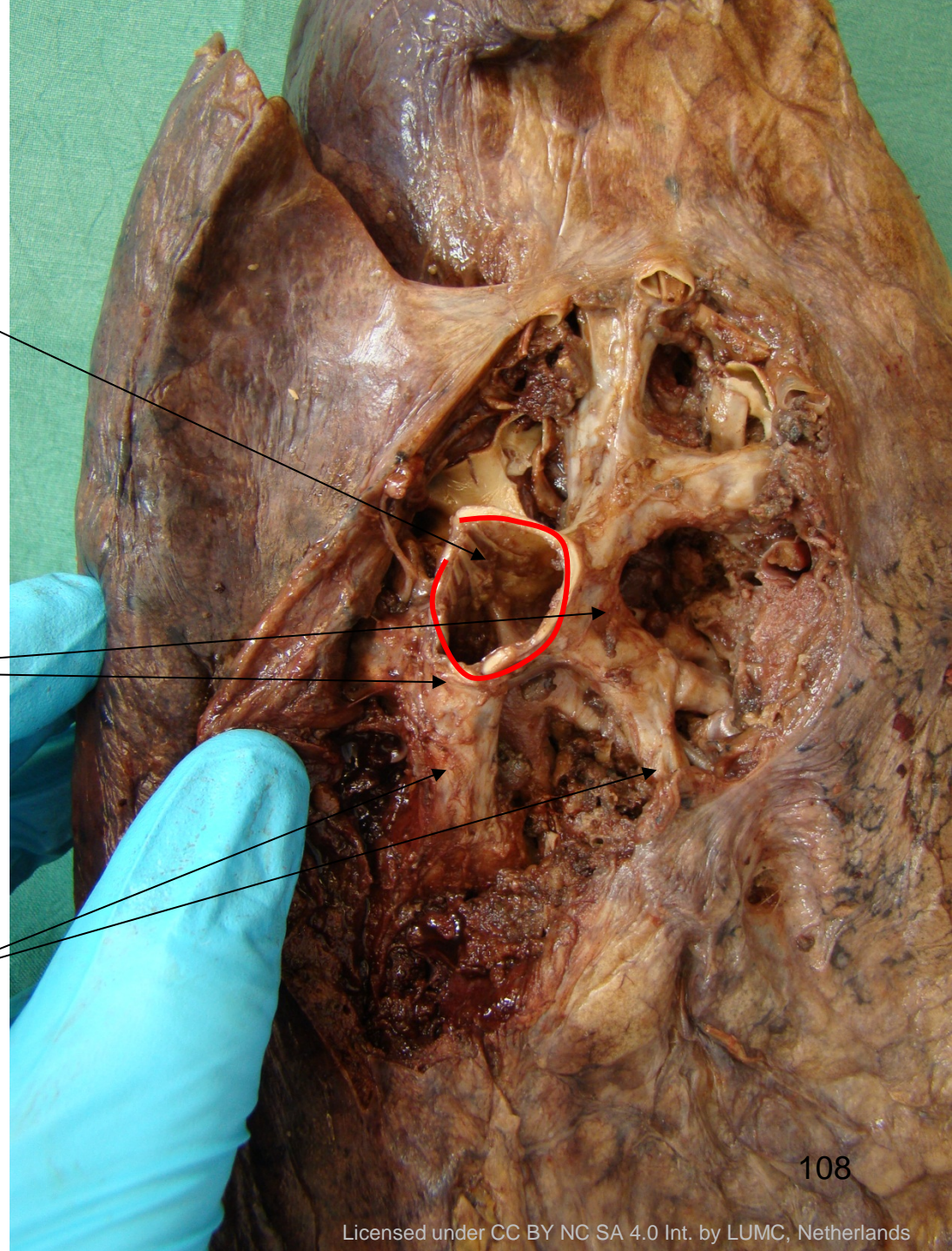
Pulmonary ligament



- Main bronchus
(red outline)

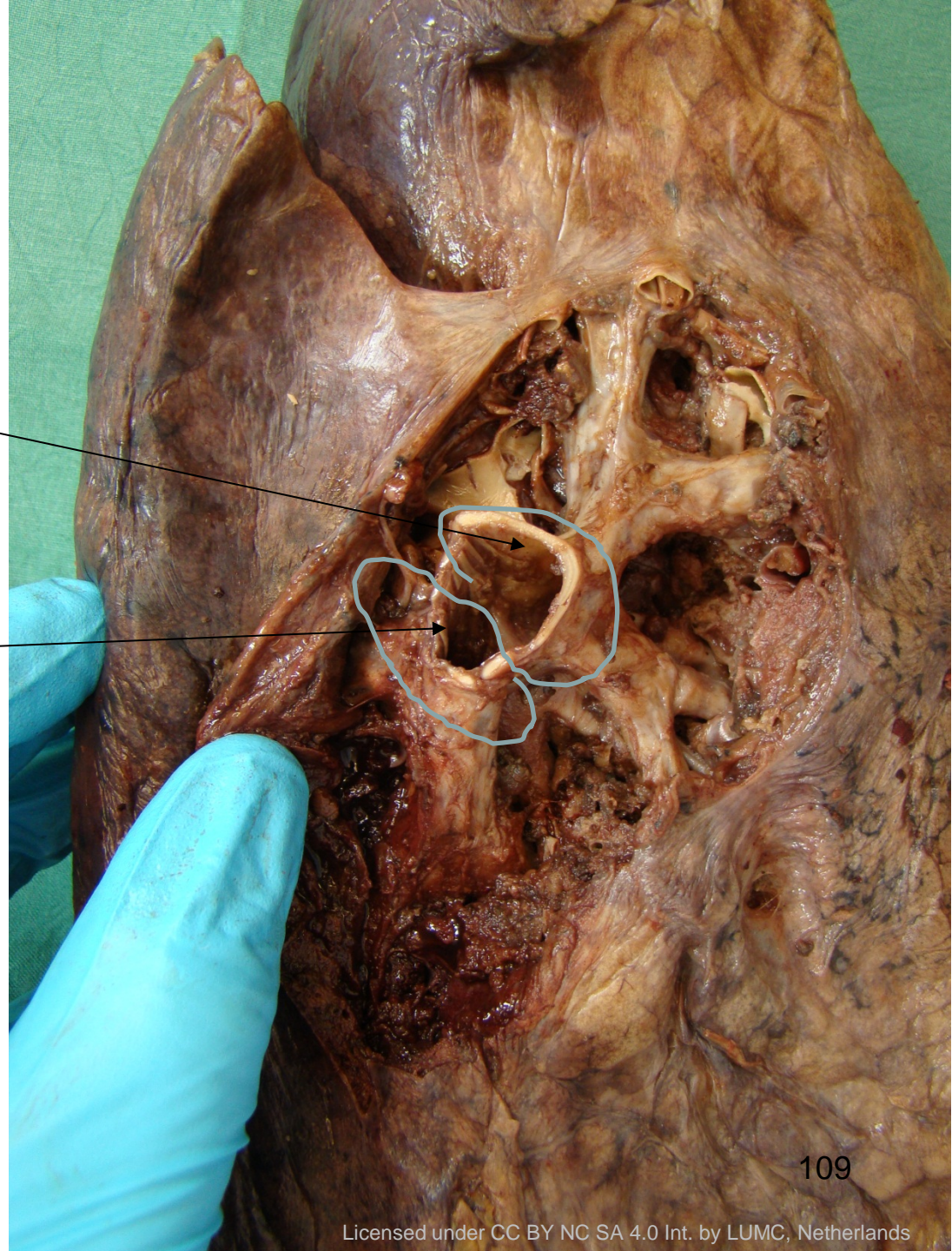
- Lobar bronchi

- Segmental bronchi

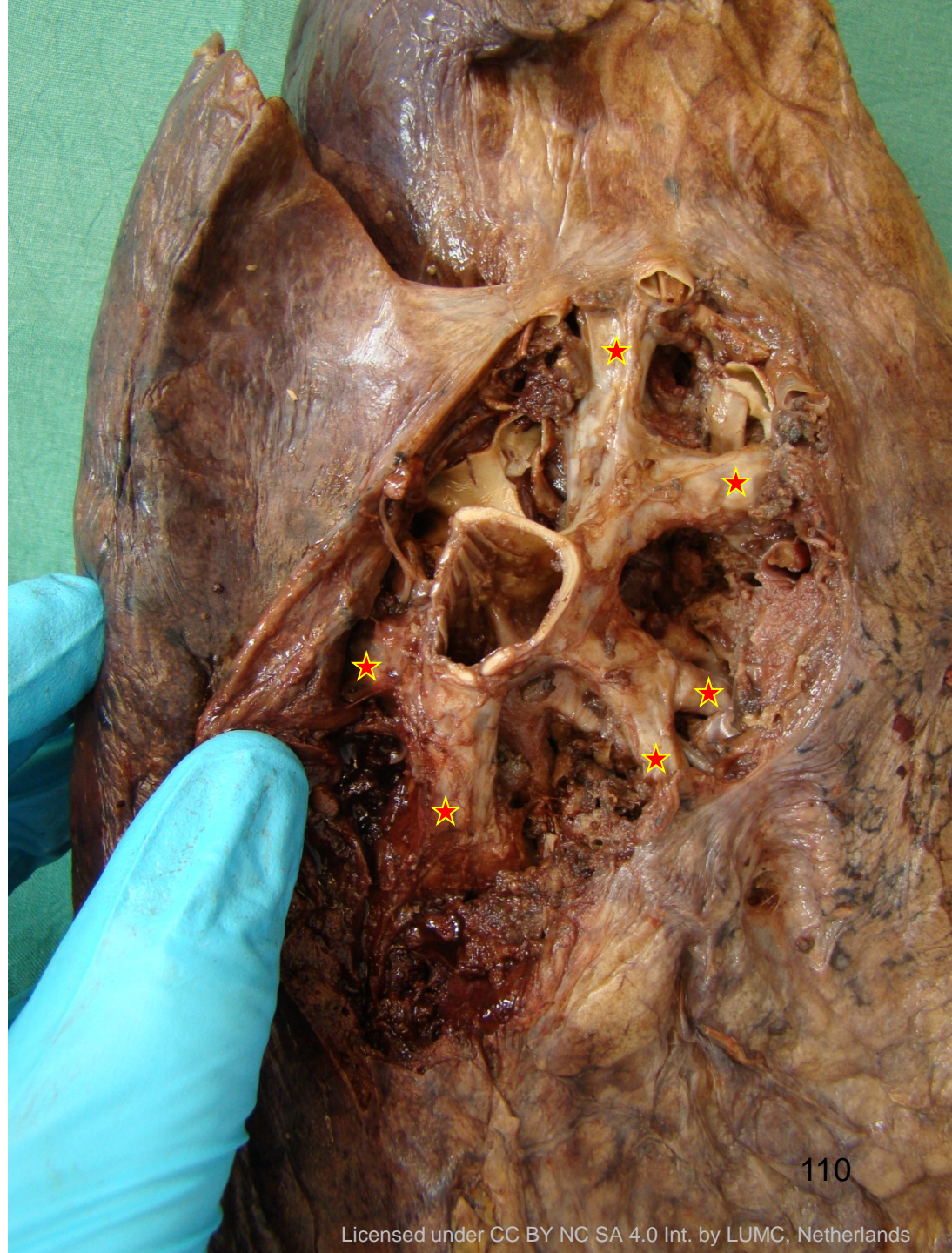

Lobar bronchi

- **Superior lobar bronchus**
(outline roughly indicates location)
- **Inferior lobar bronchus**
(outline roughly indicates location)



- Segmental bronchi



Dissection of the heart

The reflection line from epicardium to pericardium

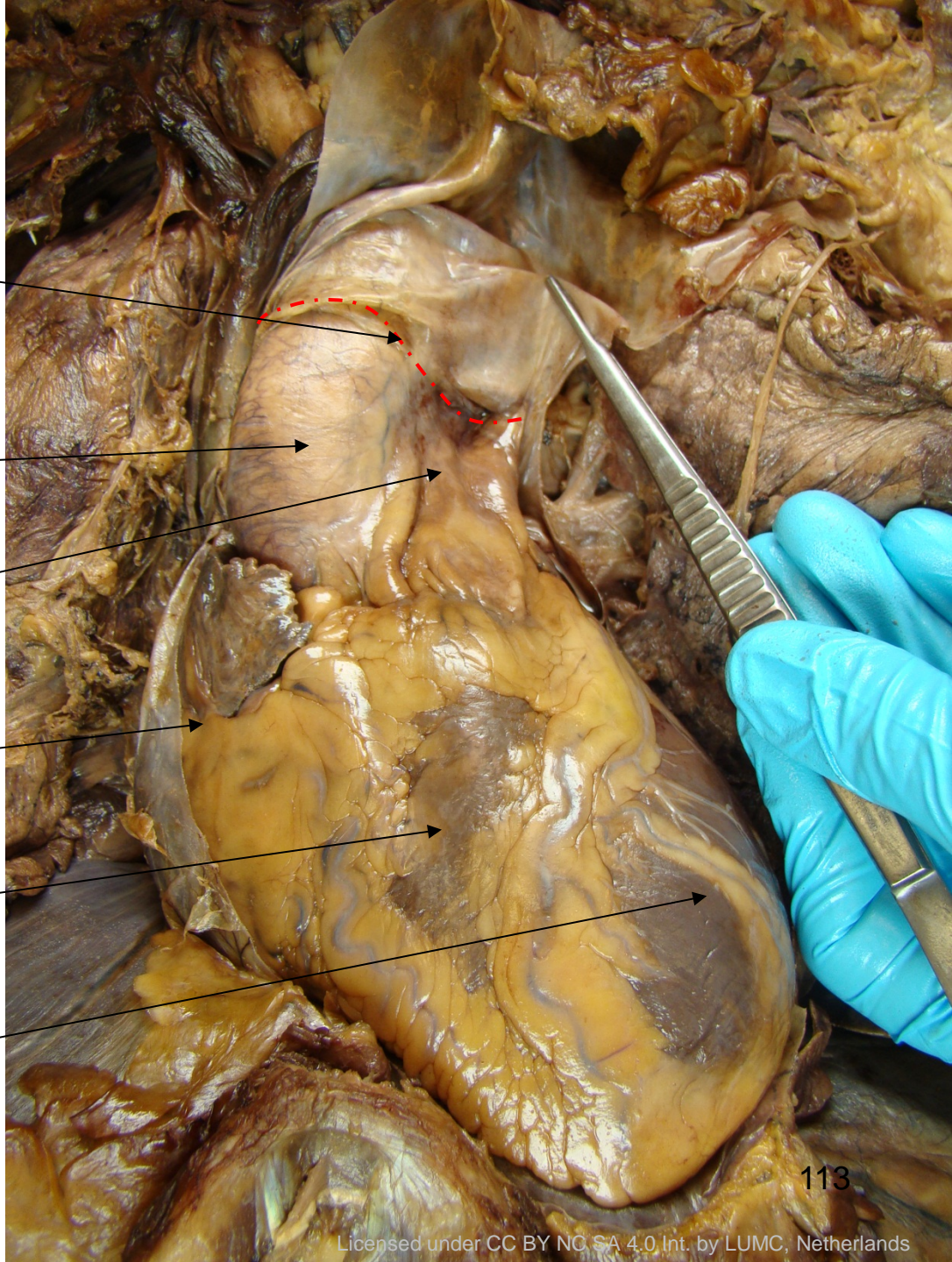
Ascending aorta

Pulmonary trunk

Right atrium

Right ventricle

Left ventricle



- Pulmonary valve

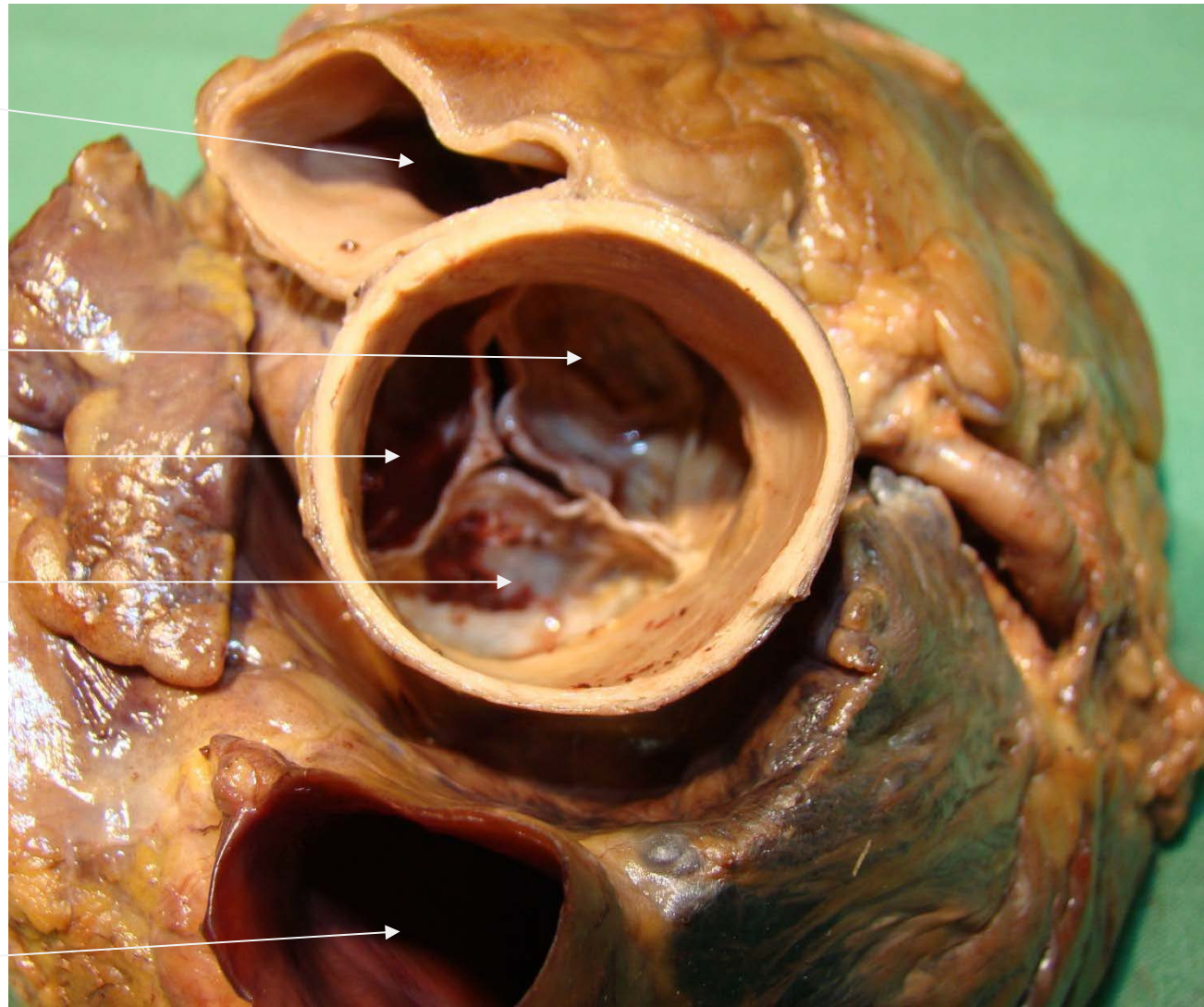
- Aortic valve

- Right

- Left

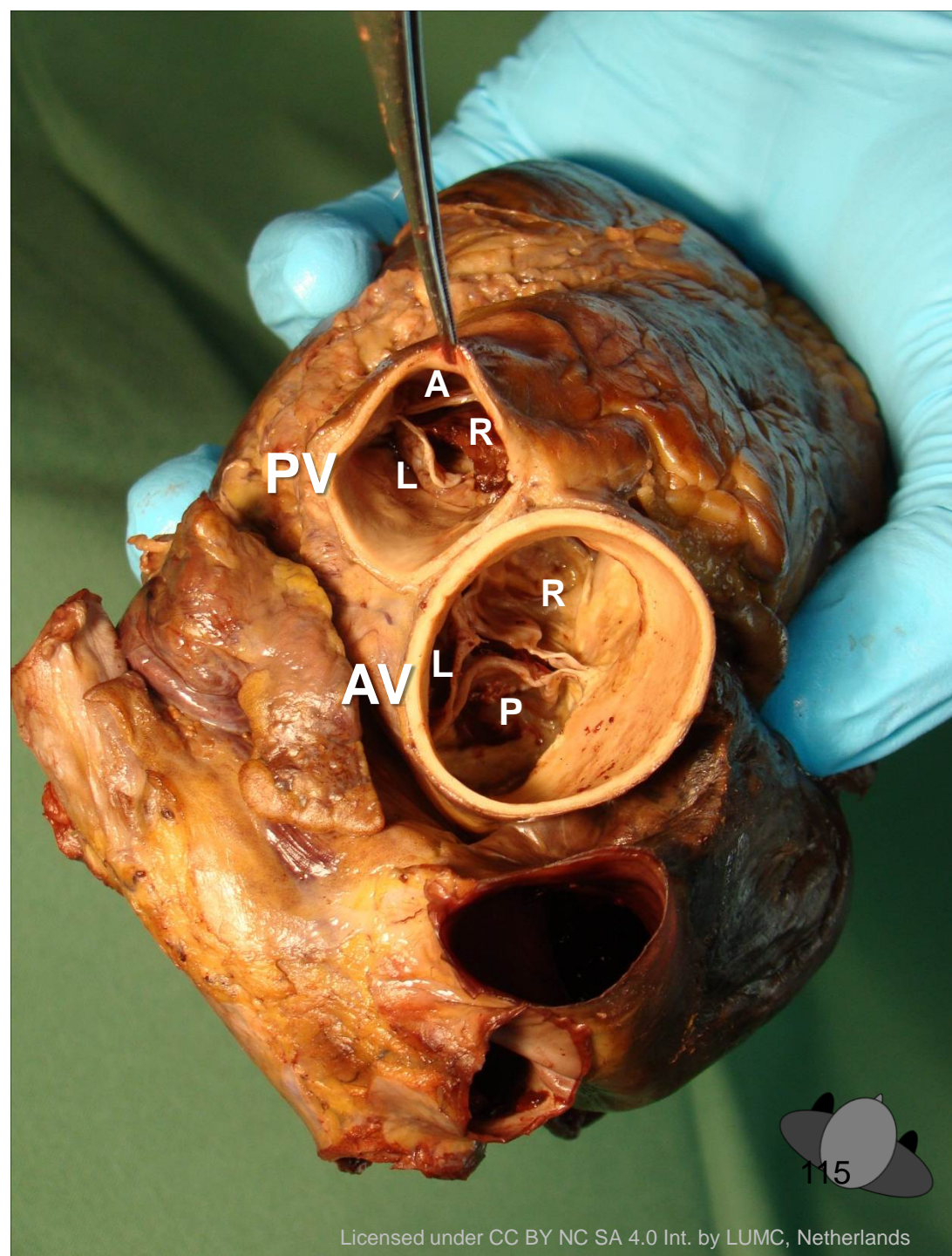
- Posterior
cusp

- Superior Vena
Cava



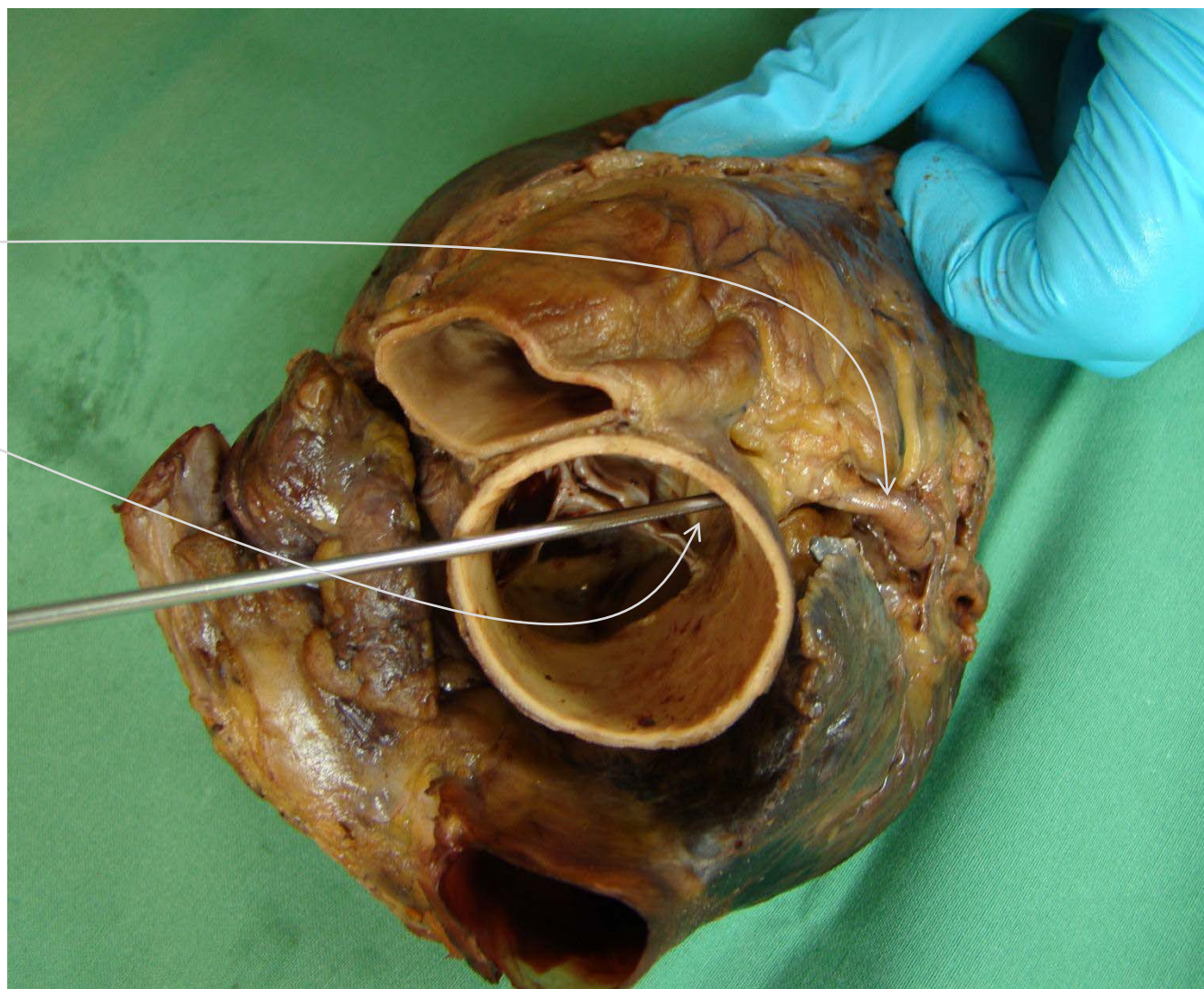
Semilunar cusp's are named according to their position

- Anterior cusp (A)
- Left cusps (L)
- Right cusps (R)
- Posterior cusp (P)
- PV: Pulmonary valve
- AV: Aortic valve

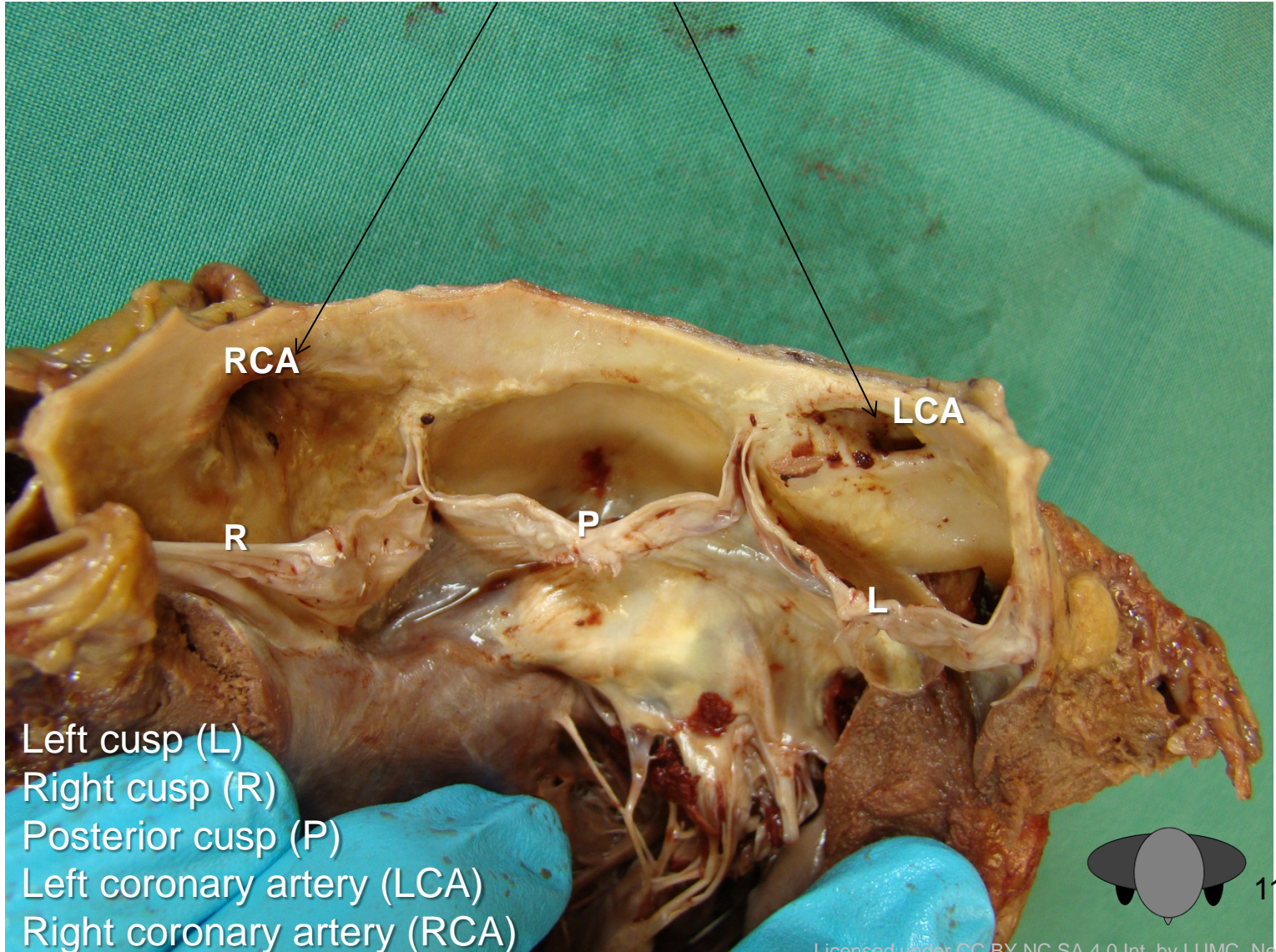


Origin of the right coronary artery from the right aortic sinus

(Probe in opening of coronary artery)



Aorta cut between left and right cusp of aortic valve
and folded open
Coronary arteries openings

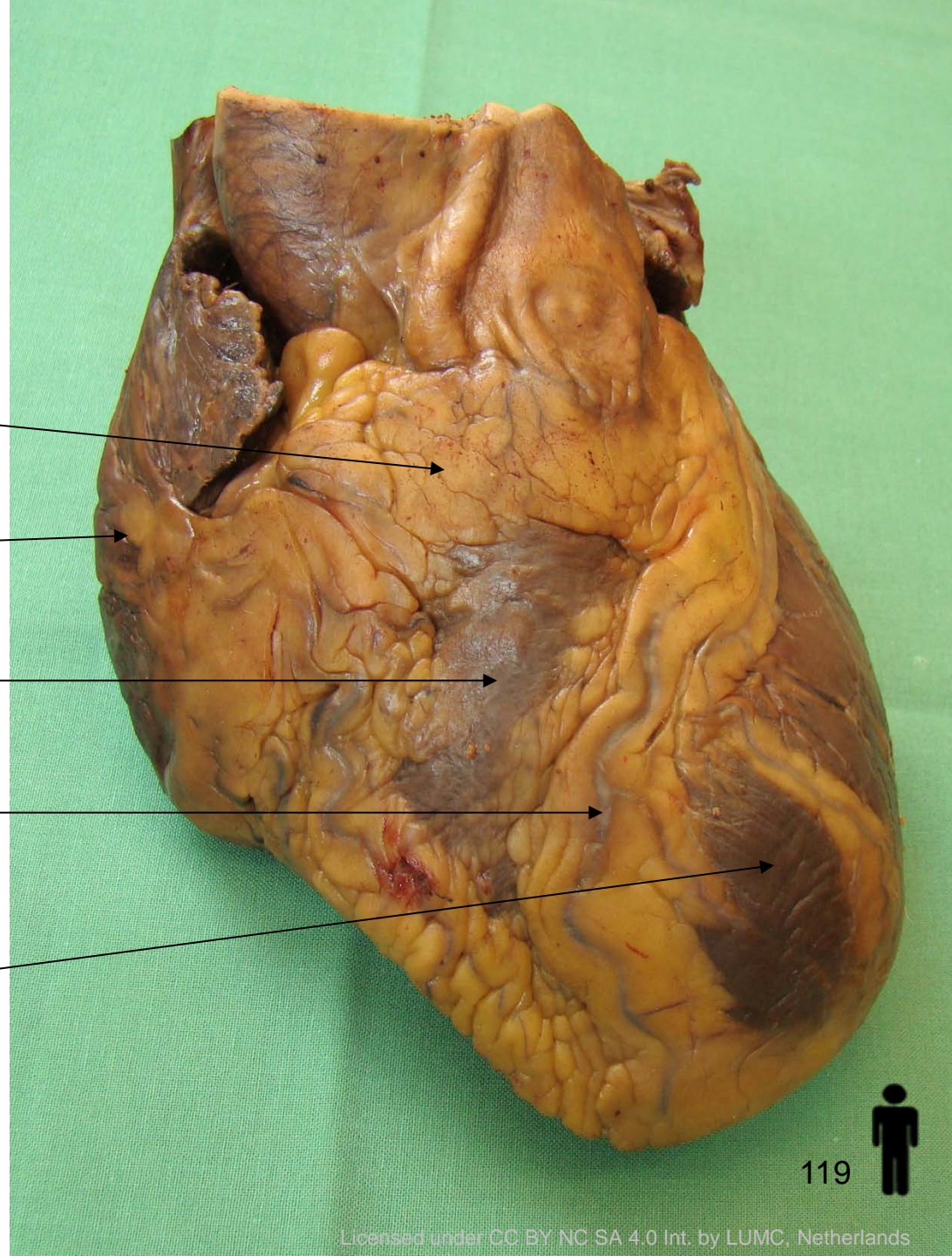


Left cusp (L)
Right cusp (R)
Posterior cusp (P)
Left coronary artery (LCA)
Right coronary artery (RCA)



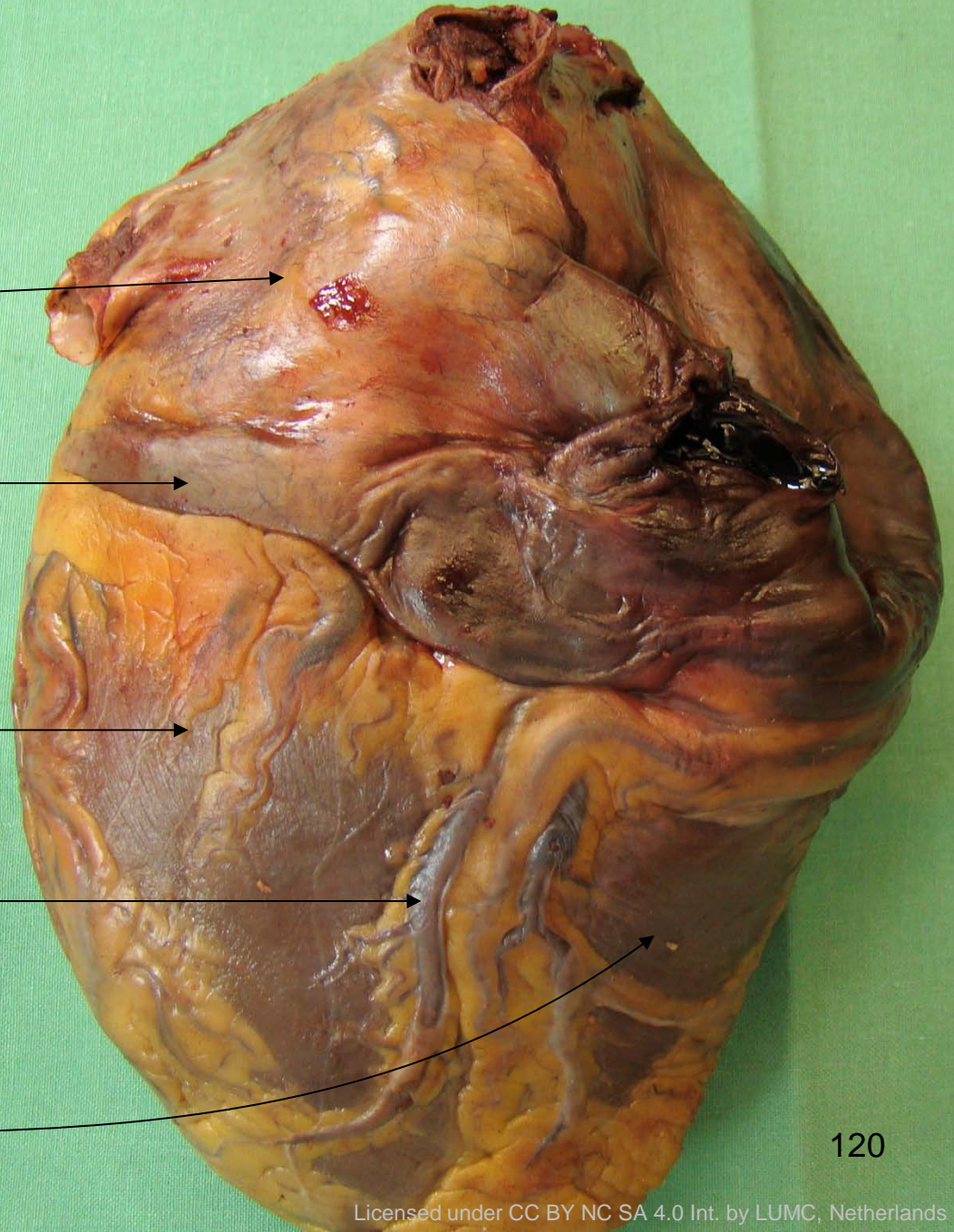
Anterior surface of the heart

- Epicardial fat
- Right atrium
- Right ventricle
- Anterior interventricular artery
- Left ventricle

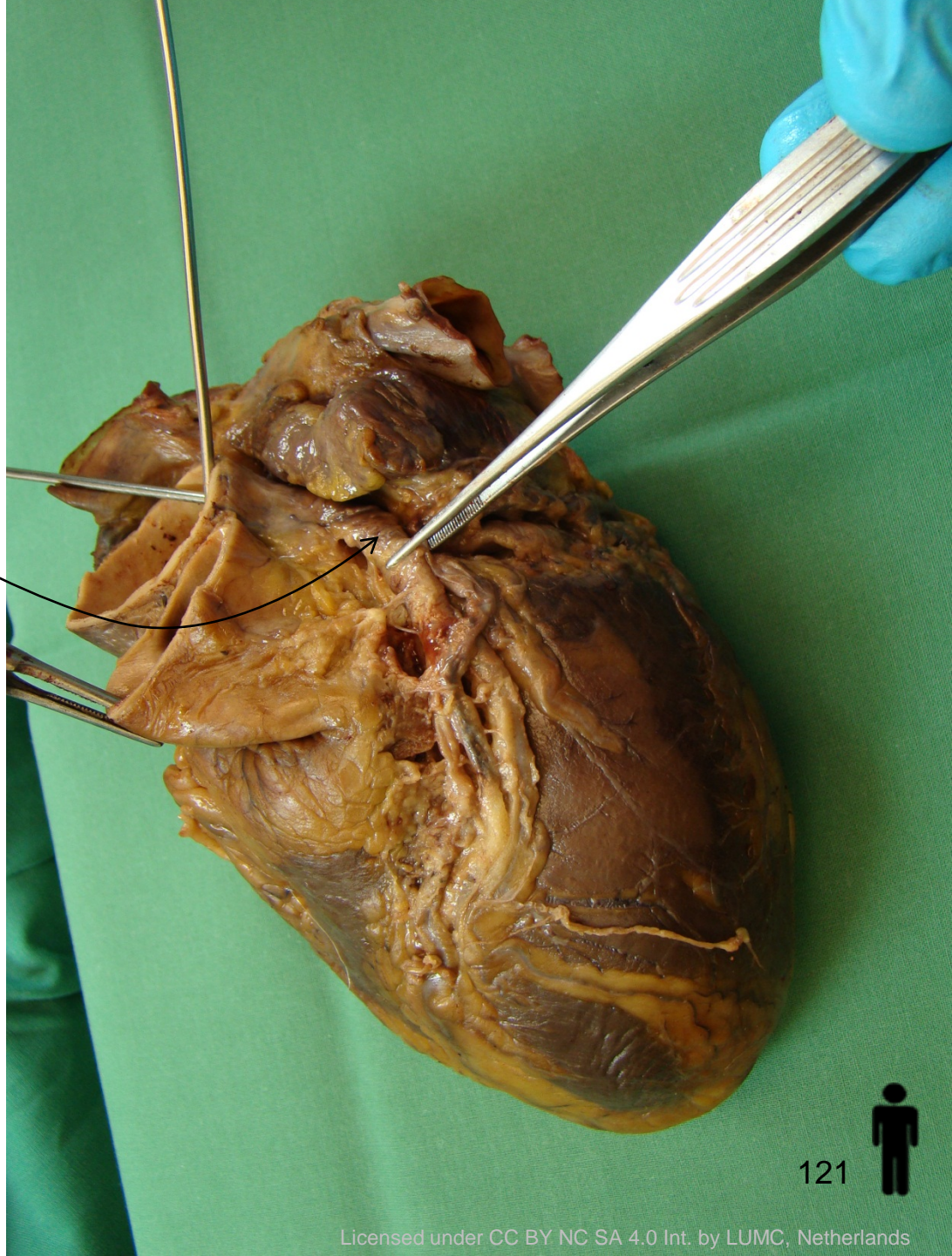


Postero-inferior surface of the heart

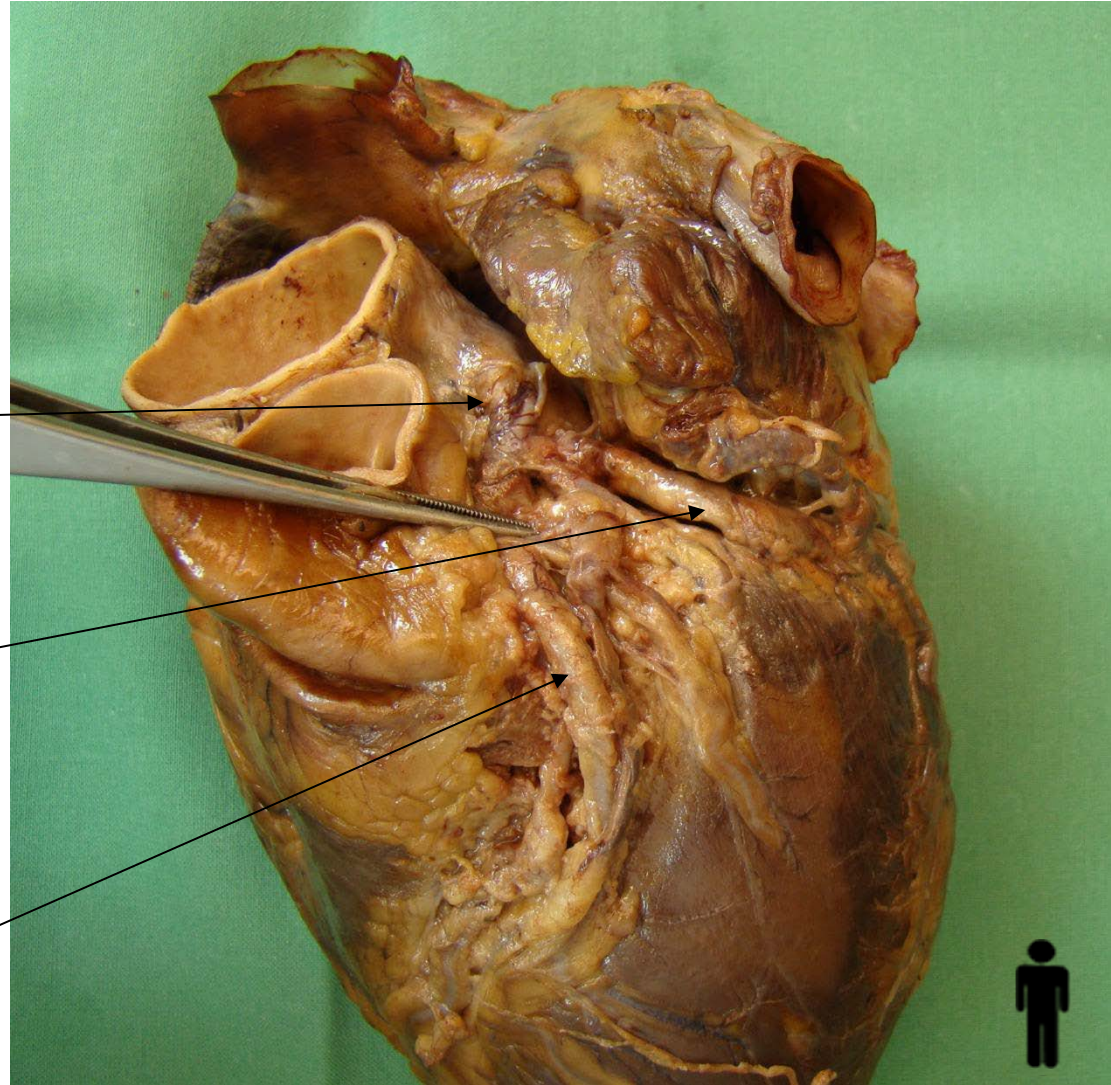
- Left atrium
- Coronary sinus
- Left ventricle
- Posterior interventricular artery
- Right ventricle



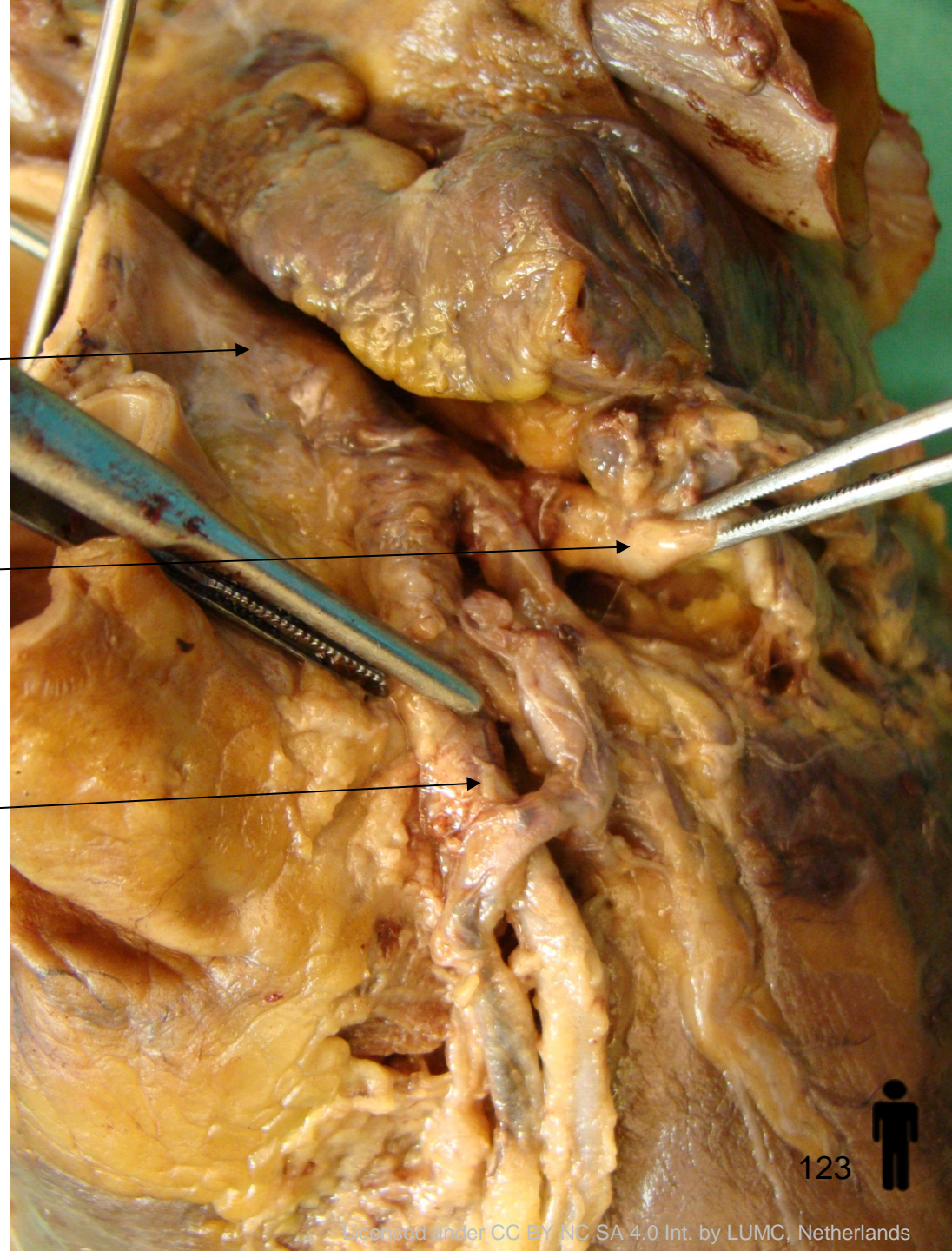
Left coronary artery



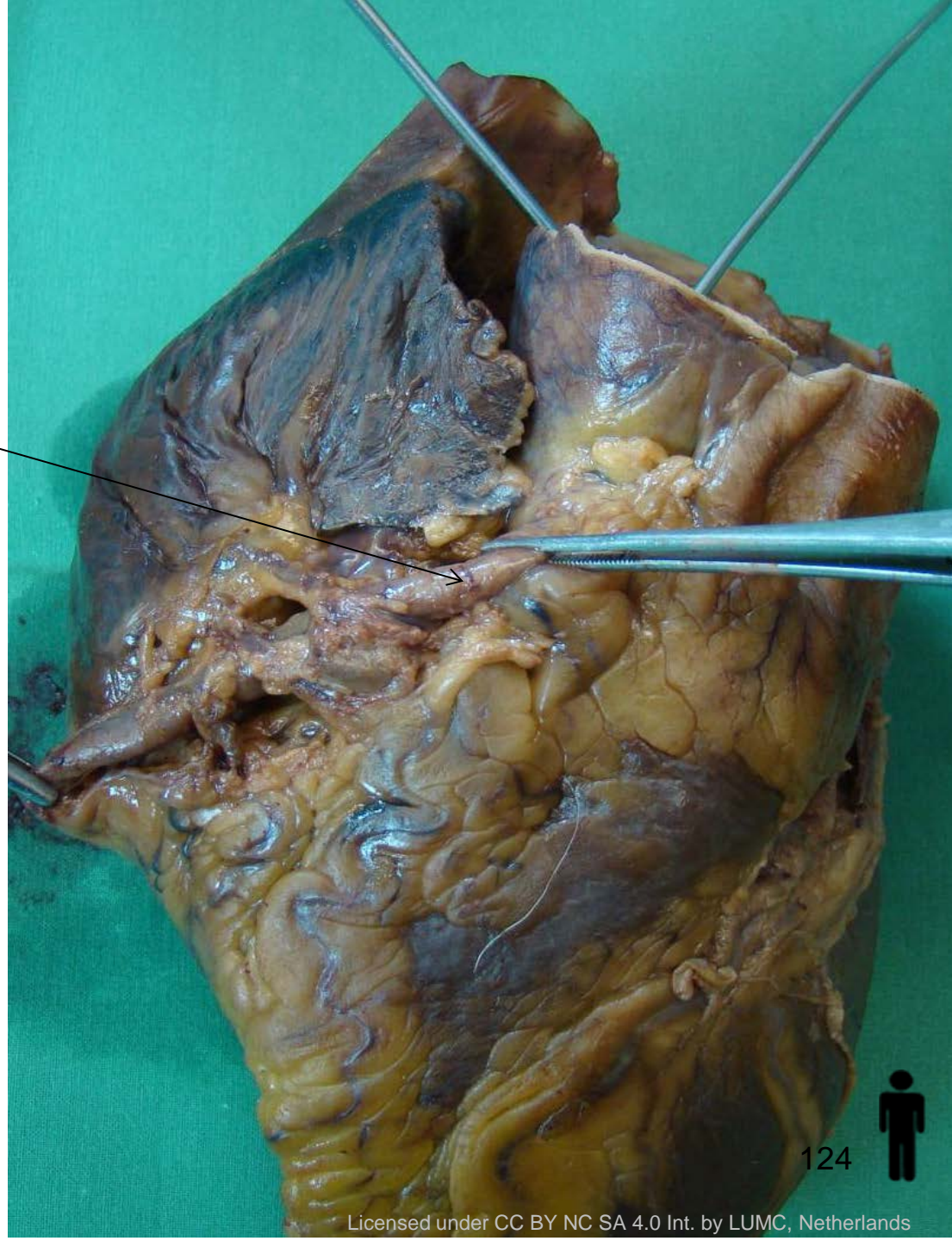
- Left coronary artery
- Circumflex branch
- Anterior interventricular branch (Left anterior descending, LAD)



- Left coronary artery
- Circumflex branch
- Anterior interventricular branch (Left anterior descending, LAD)



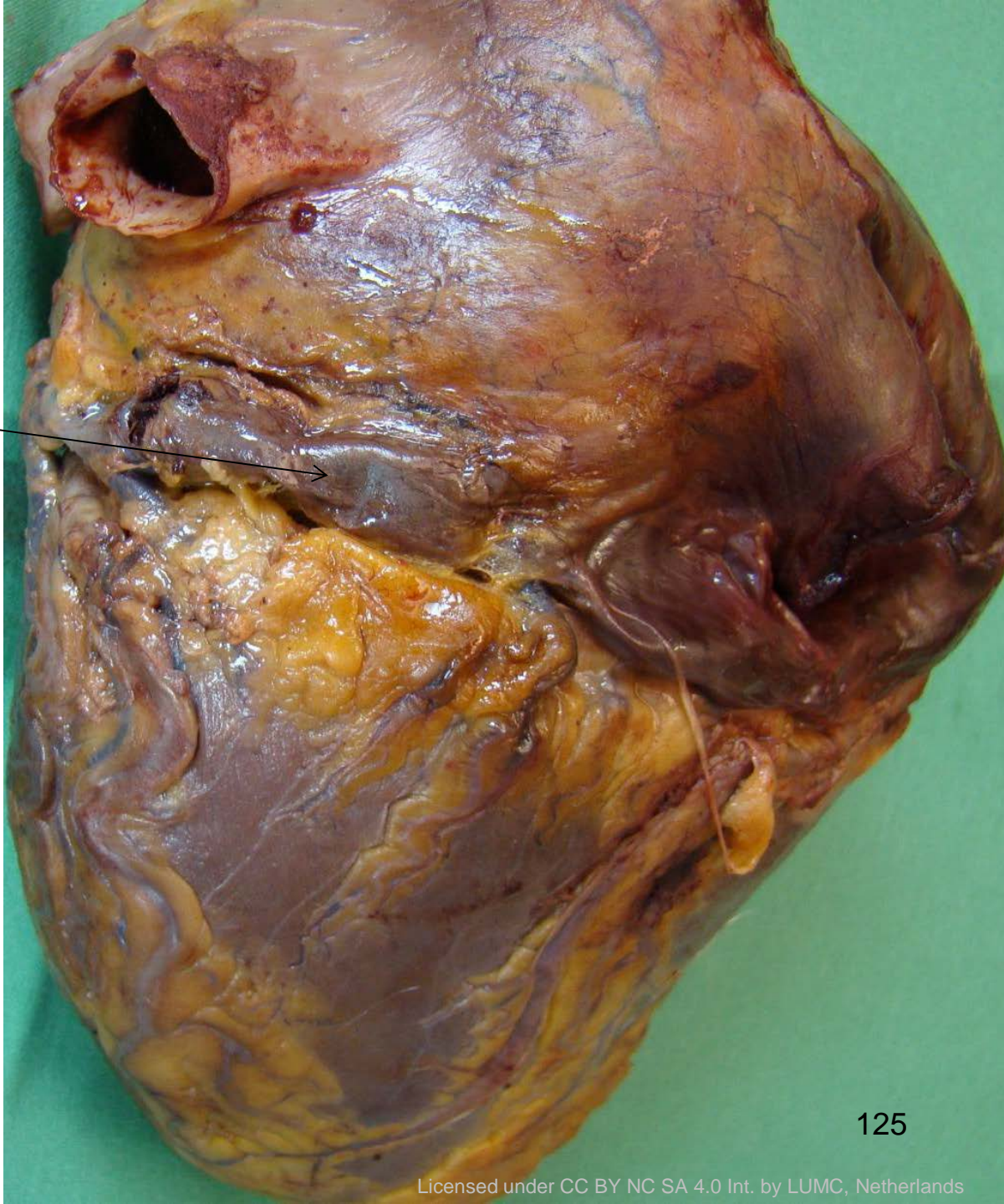
Right coronary artery



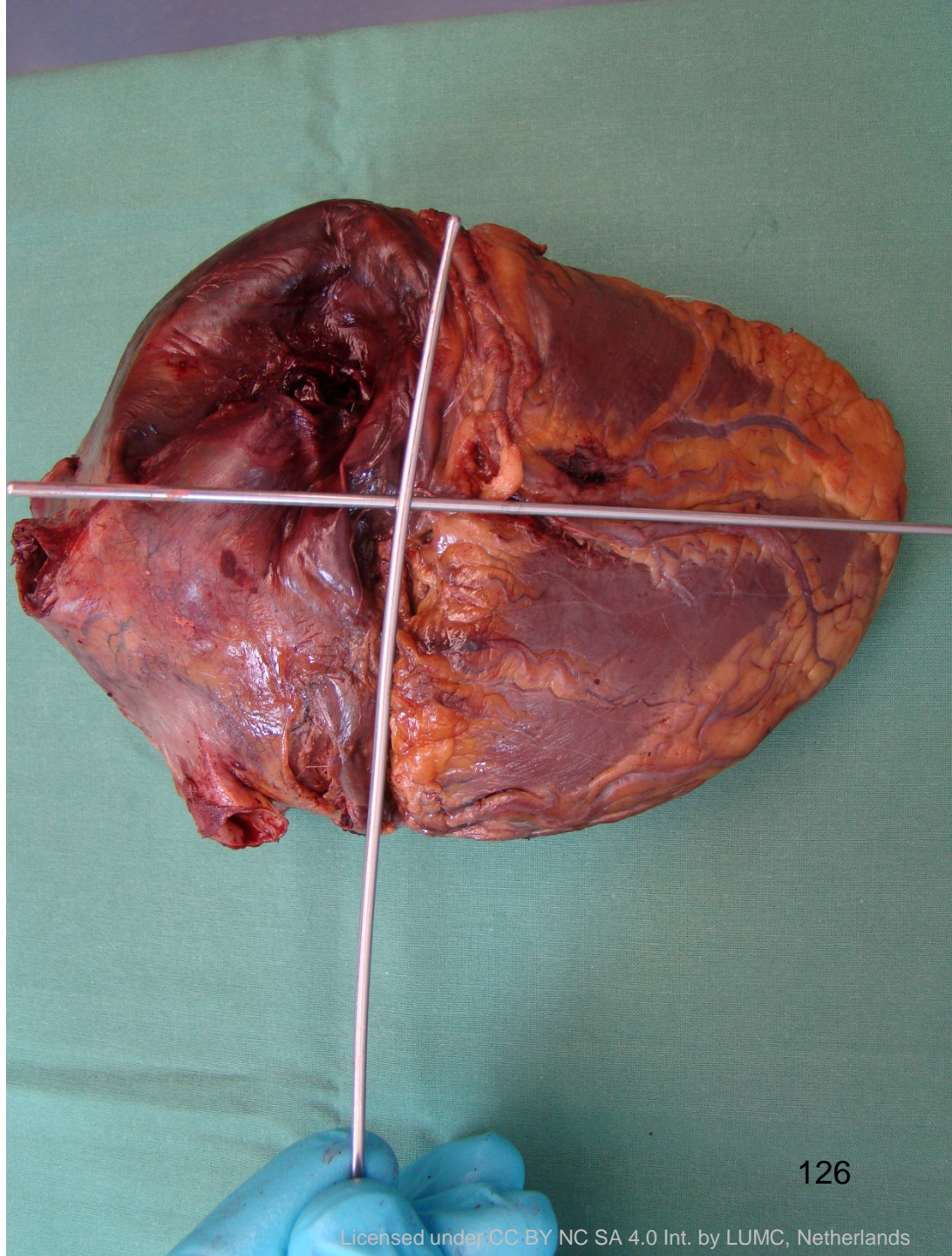
Coronary sinus



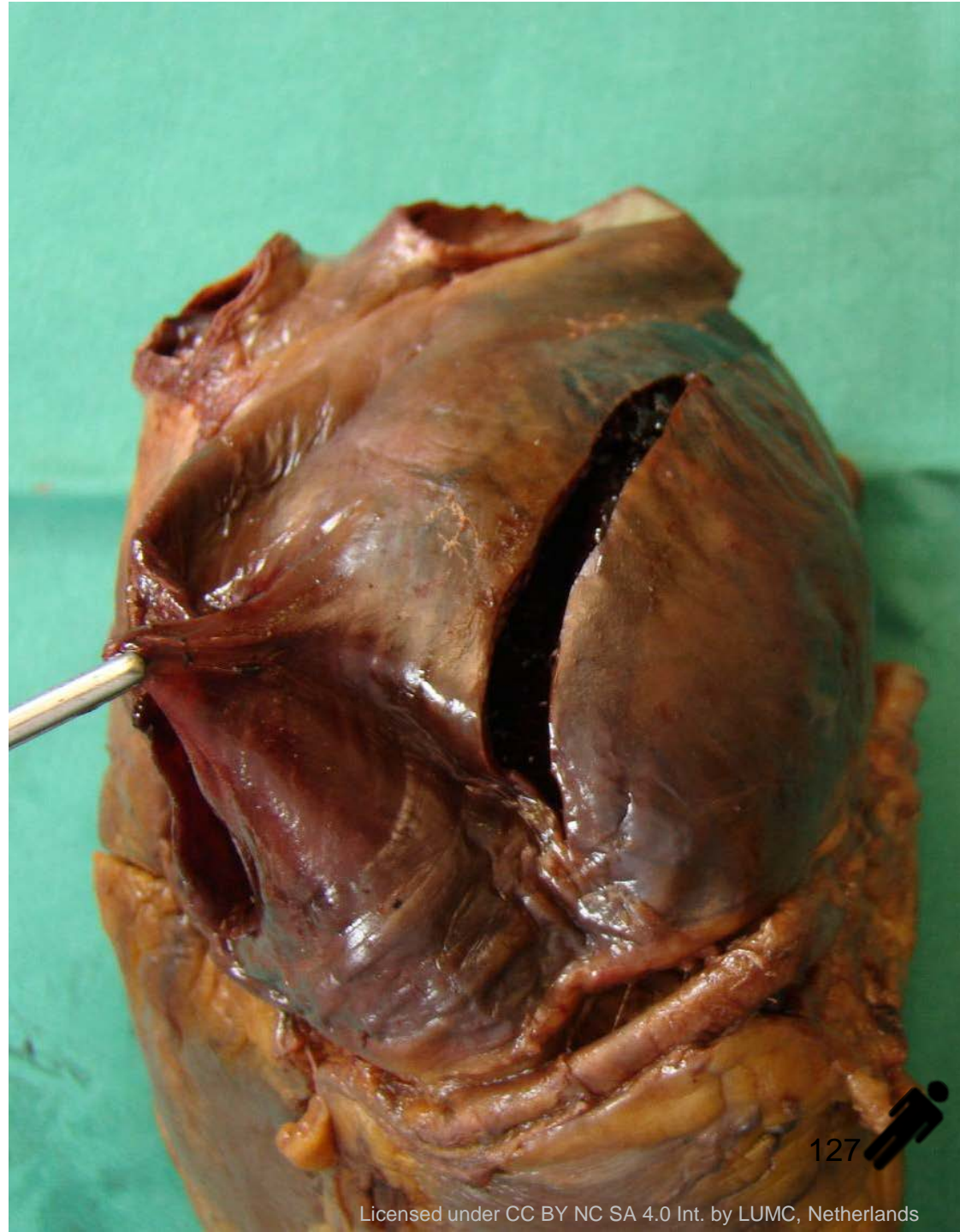
Postero-inferior view



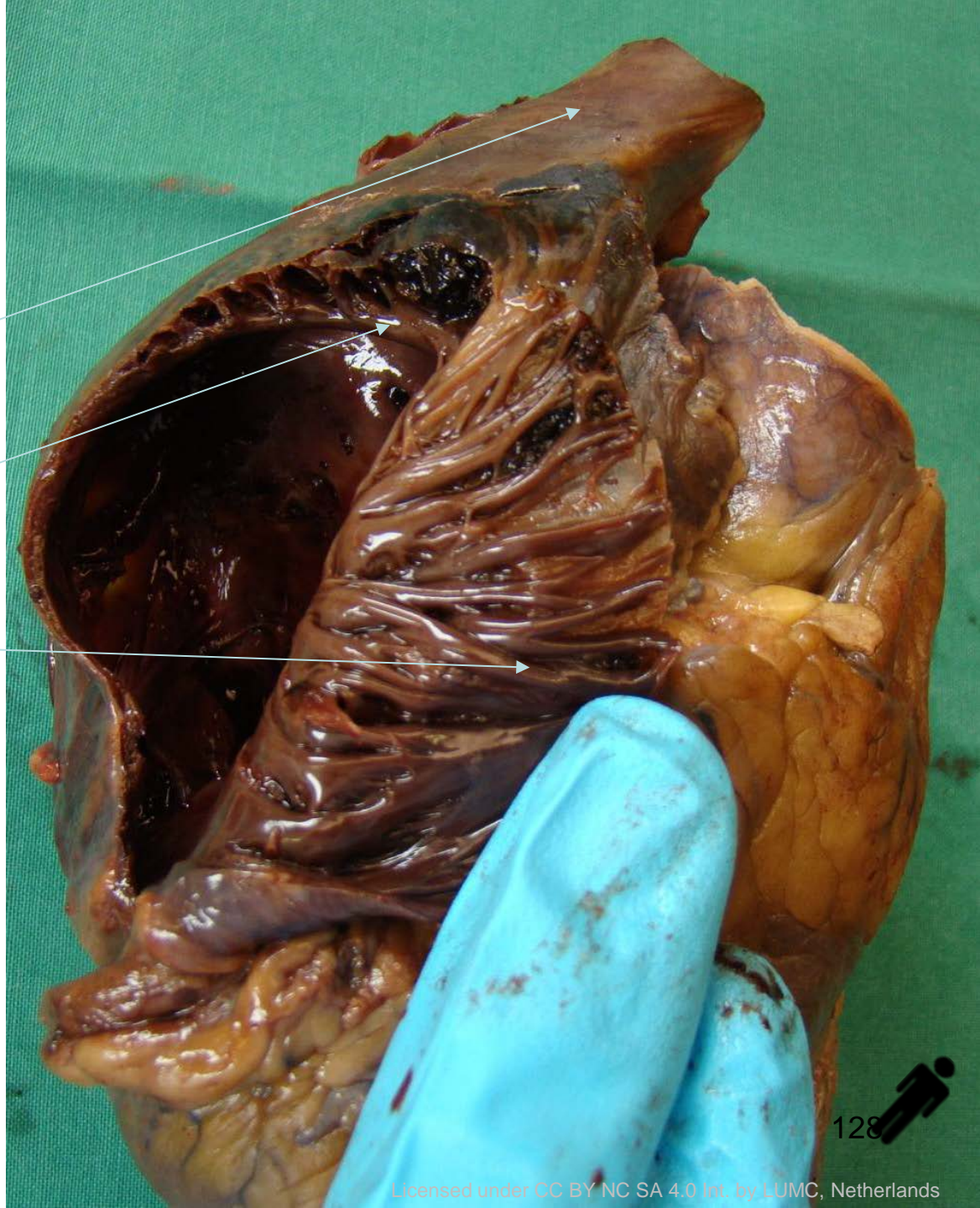
The crux cordis



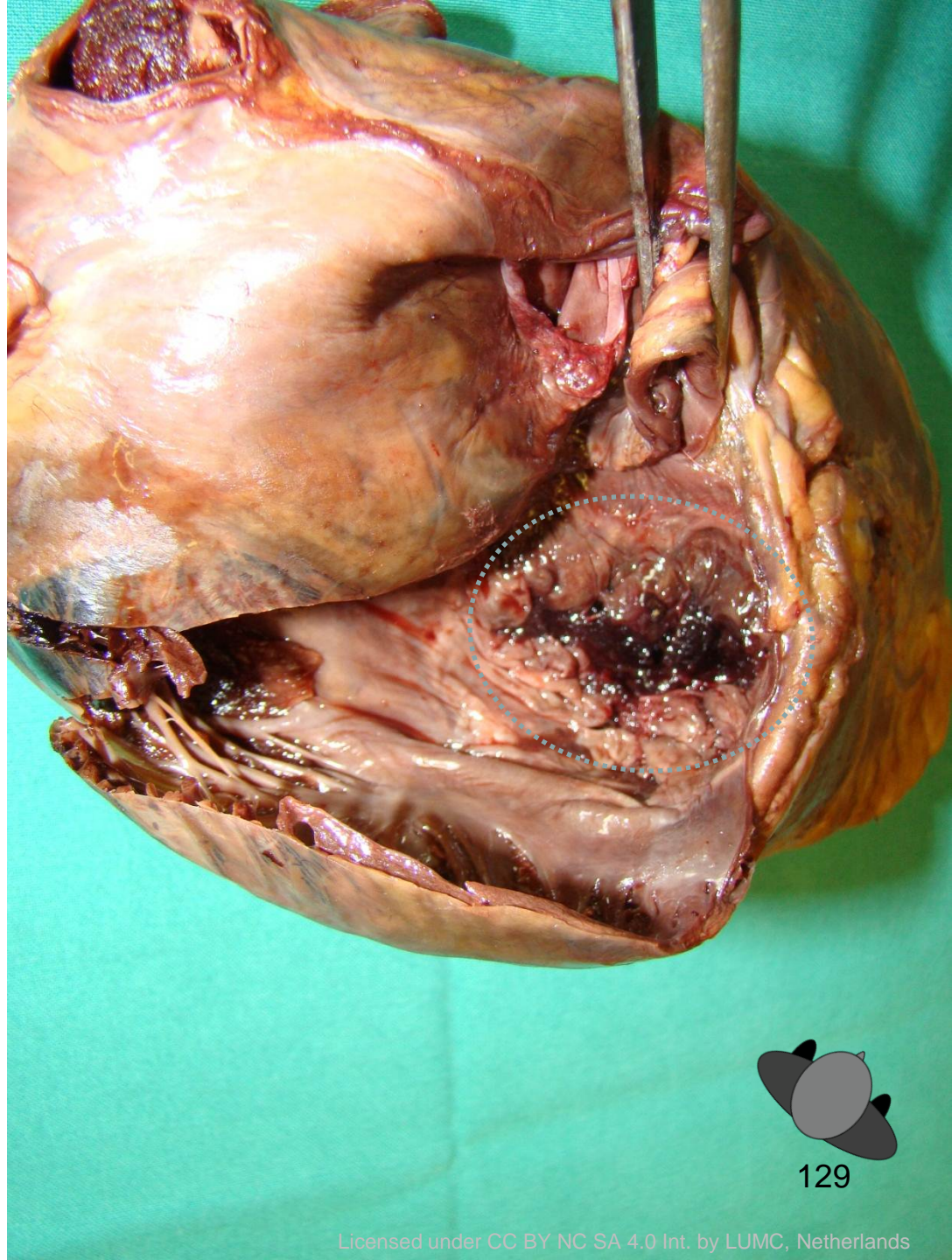
Opening the
right atrium



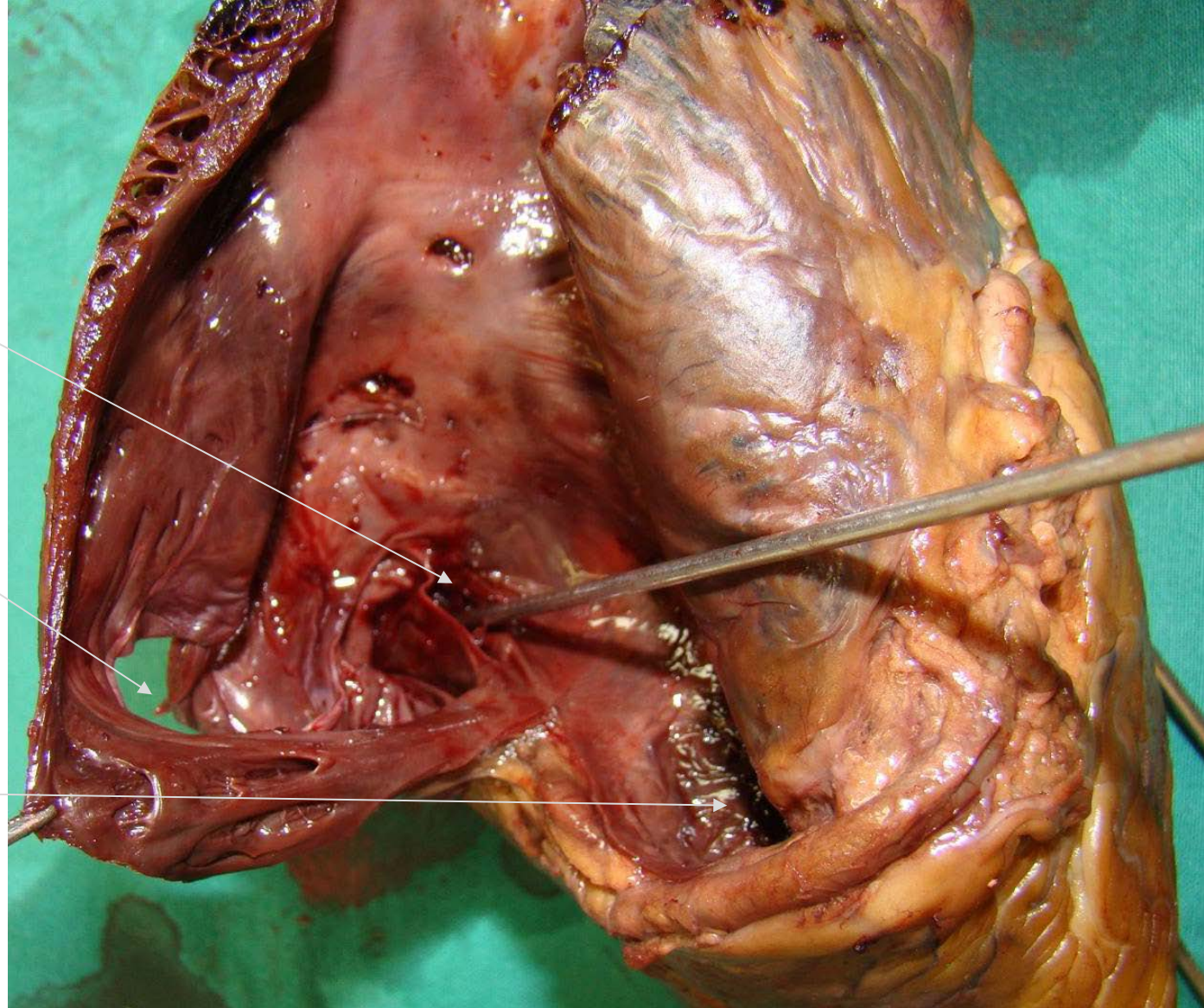
- Superior vena cava
- Crista terminalis
- Pectinate muscles



- Tricuspid valve

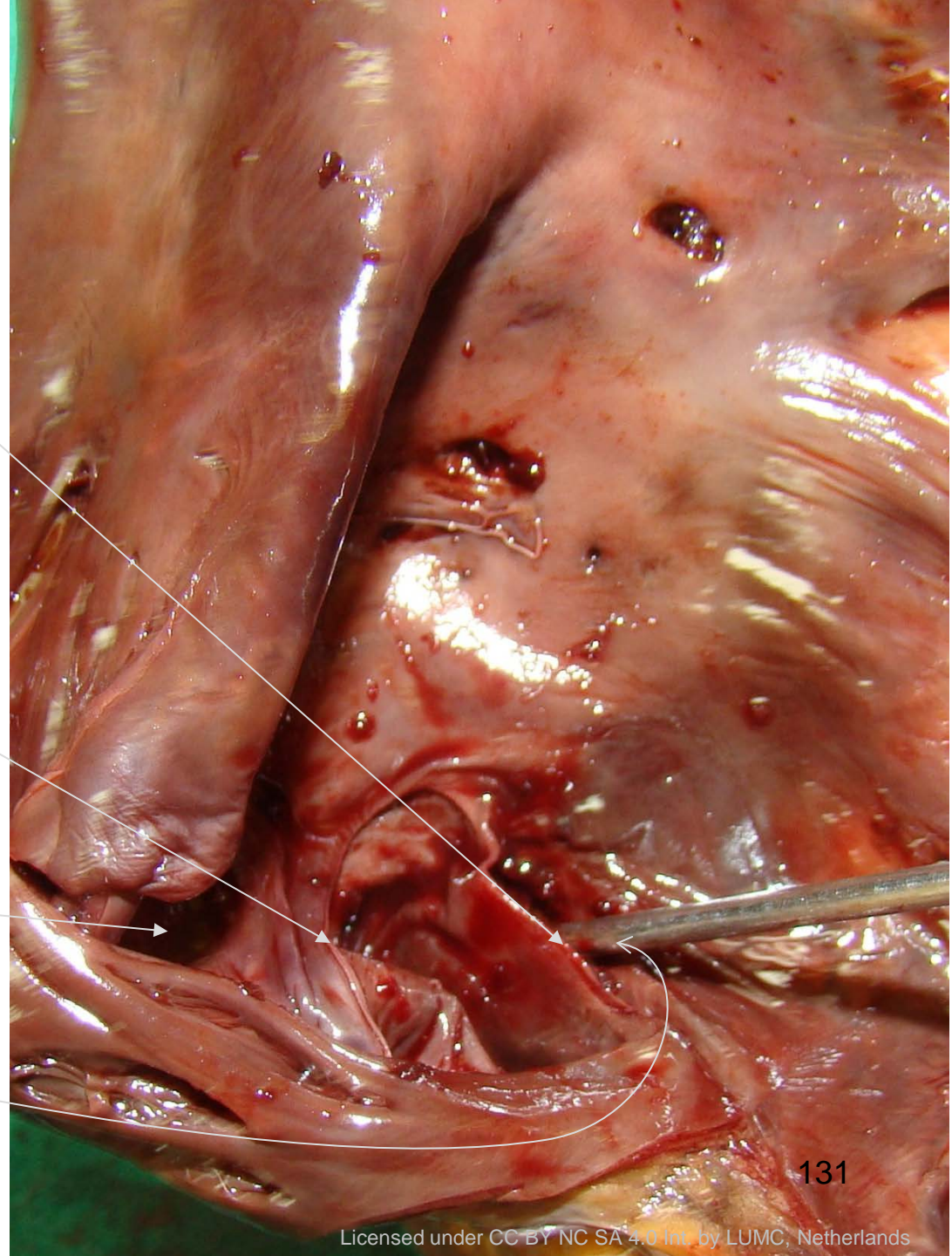


- Coronary sinus opening
- Inferior vena cava
- Tricuspid valve



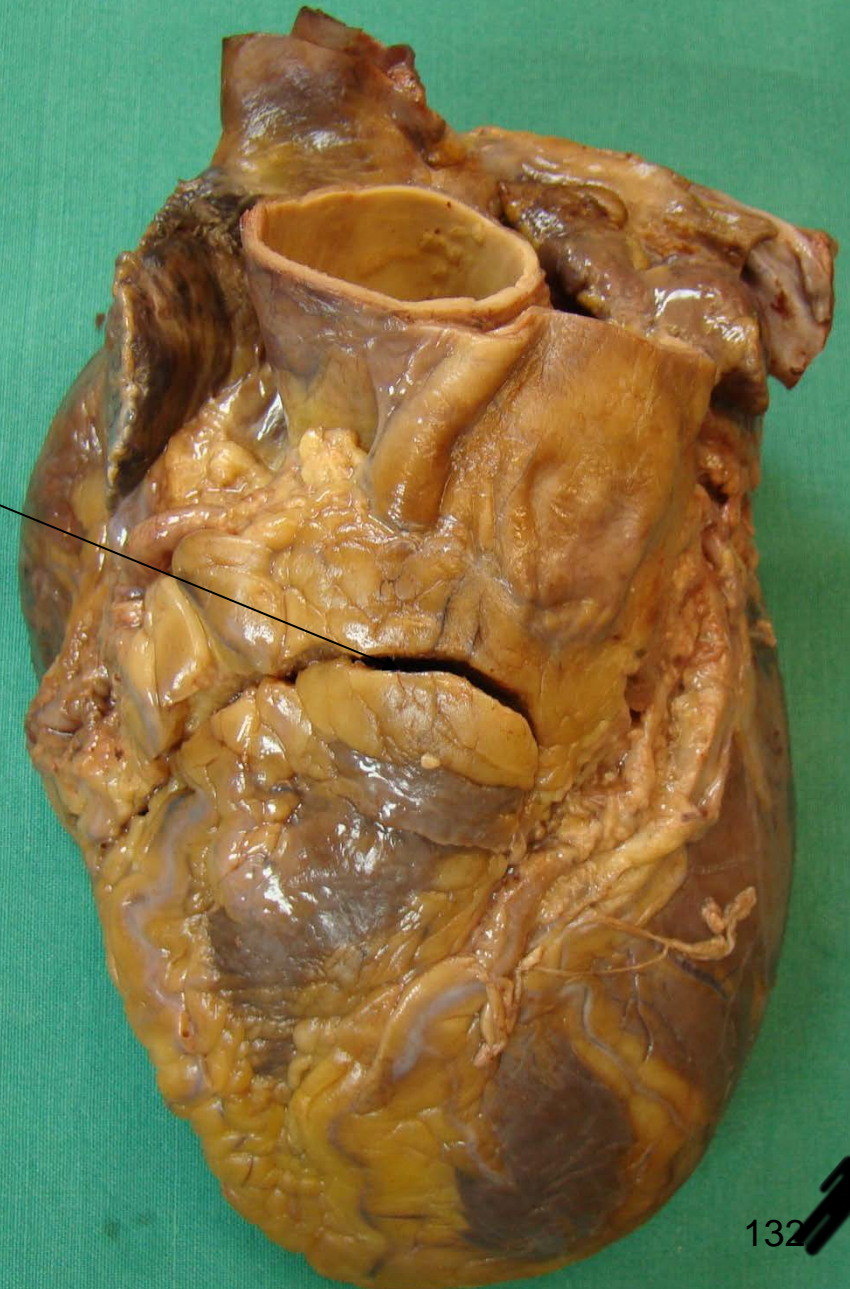
View from the right

- Valve (Thebesian) of coronary sinus
- Valve (Eustachian) of inferior vena cava
- Inferior vena cava
- Coronary sinus opening

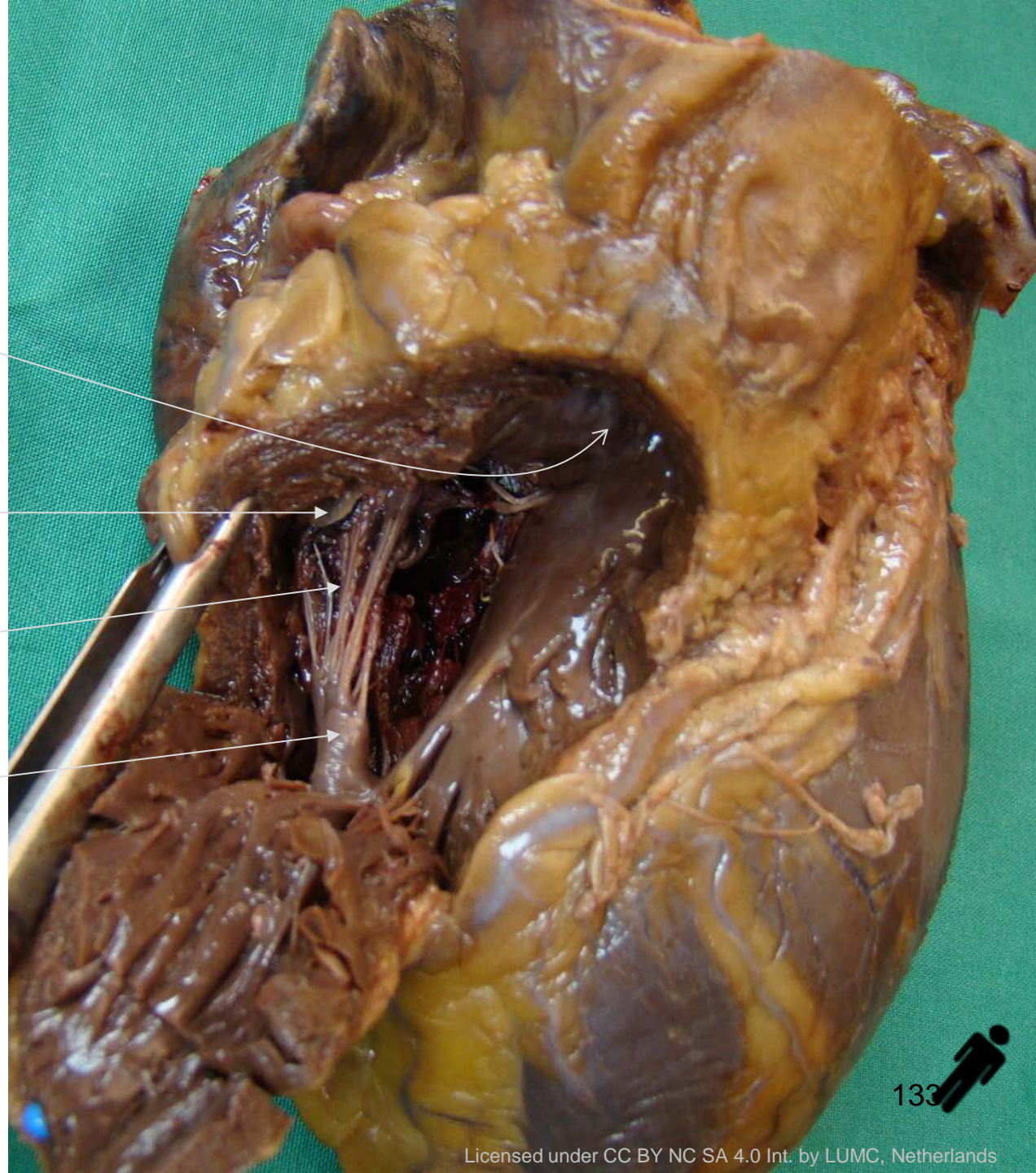


View from the right

Opening the
right ventricle

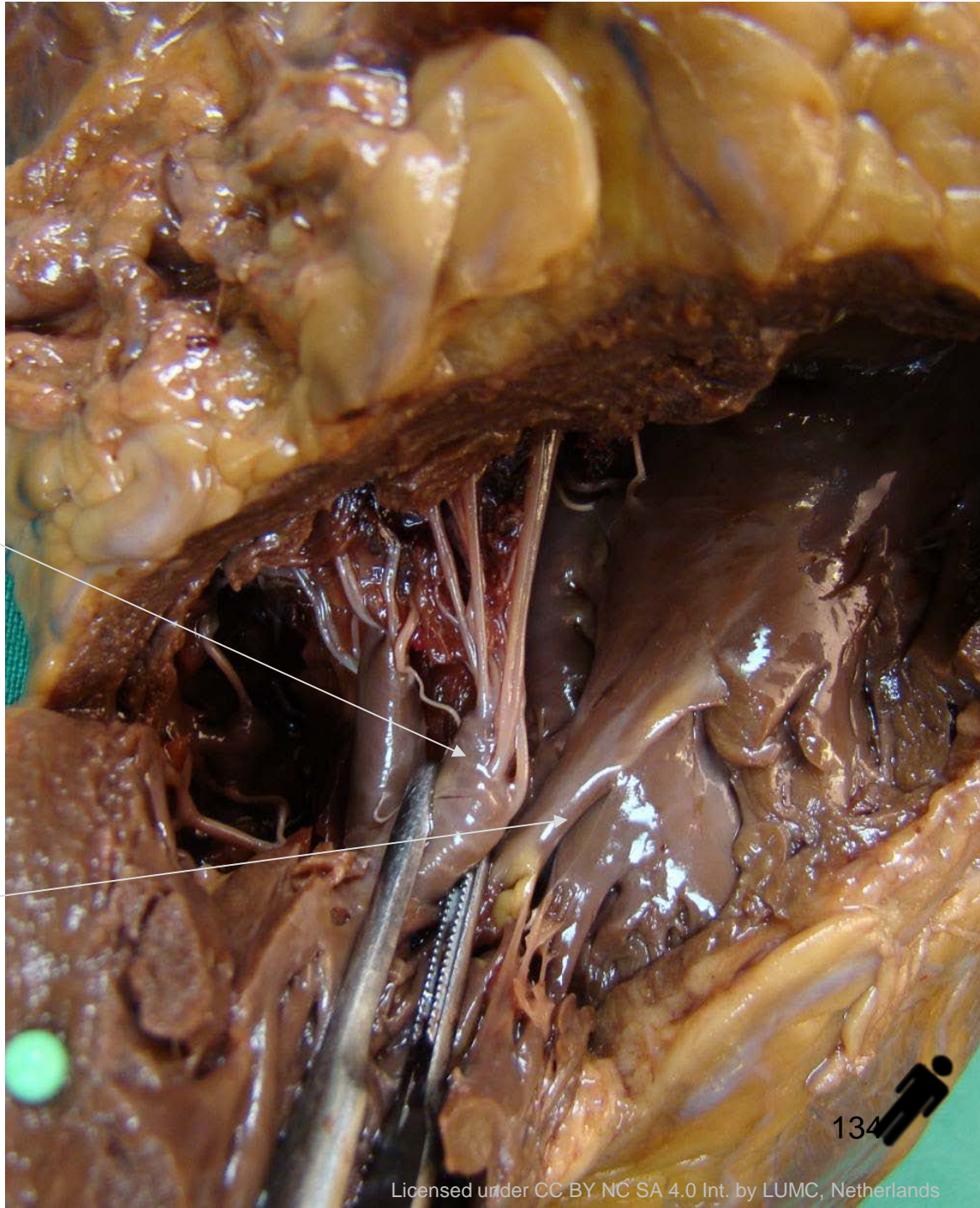


- Infundibulum (conus arteriosus)
- Tricuspid valve
- Chordae tendinea
- Papillary muscle

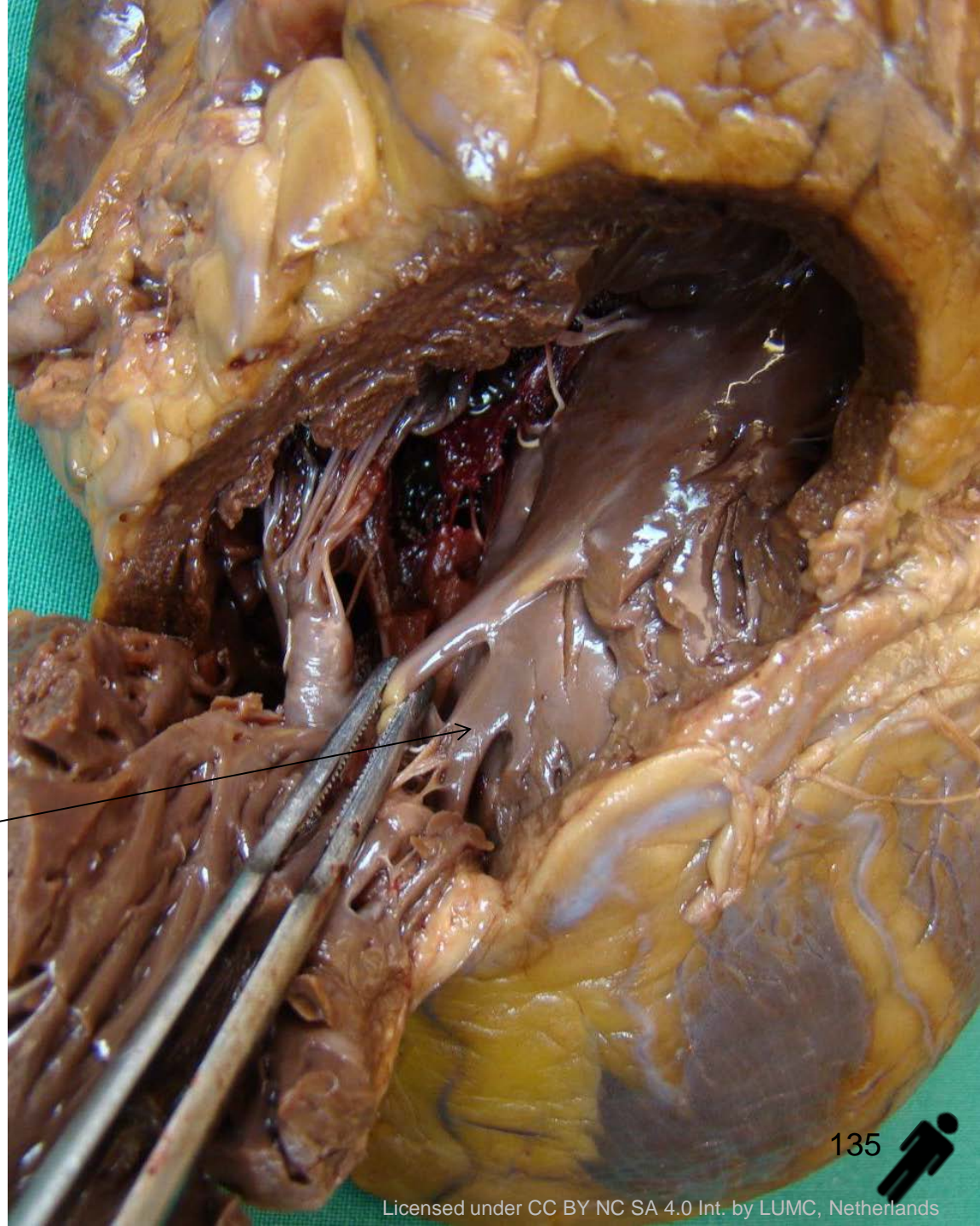


Tricuspid valve

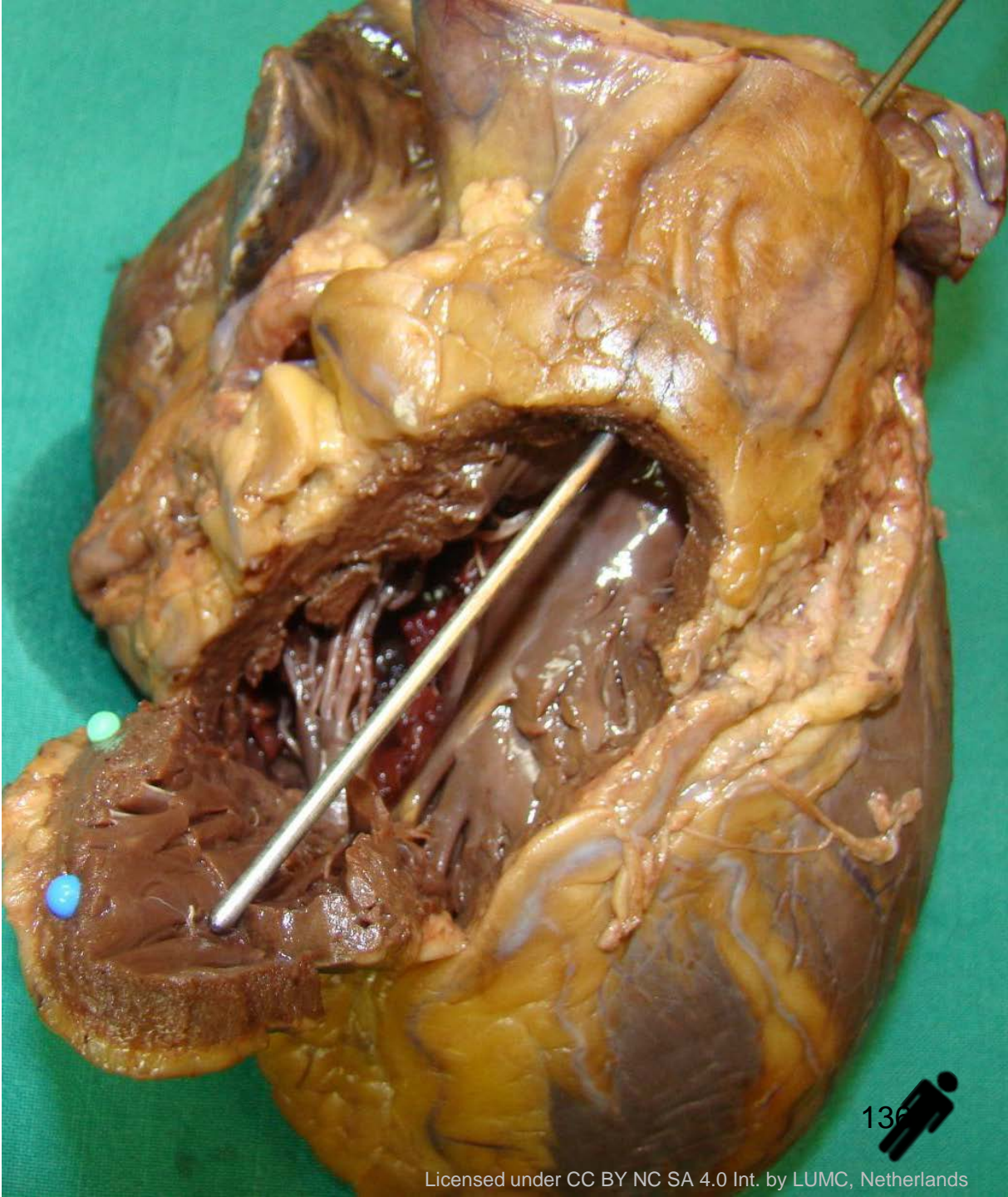
- Anterior papillary muscle
- Moderator band (Septomarginal trabecula)



Moderator band
(Septomarginal
trabecula)

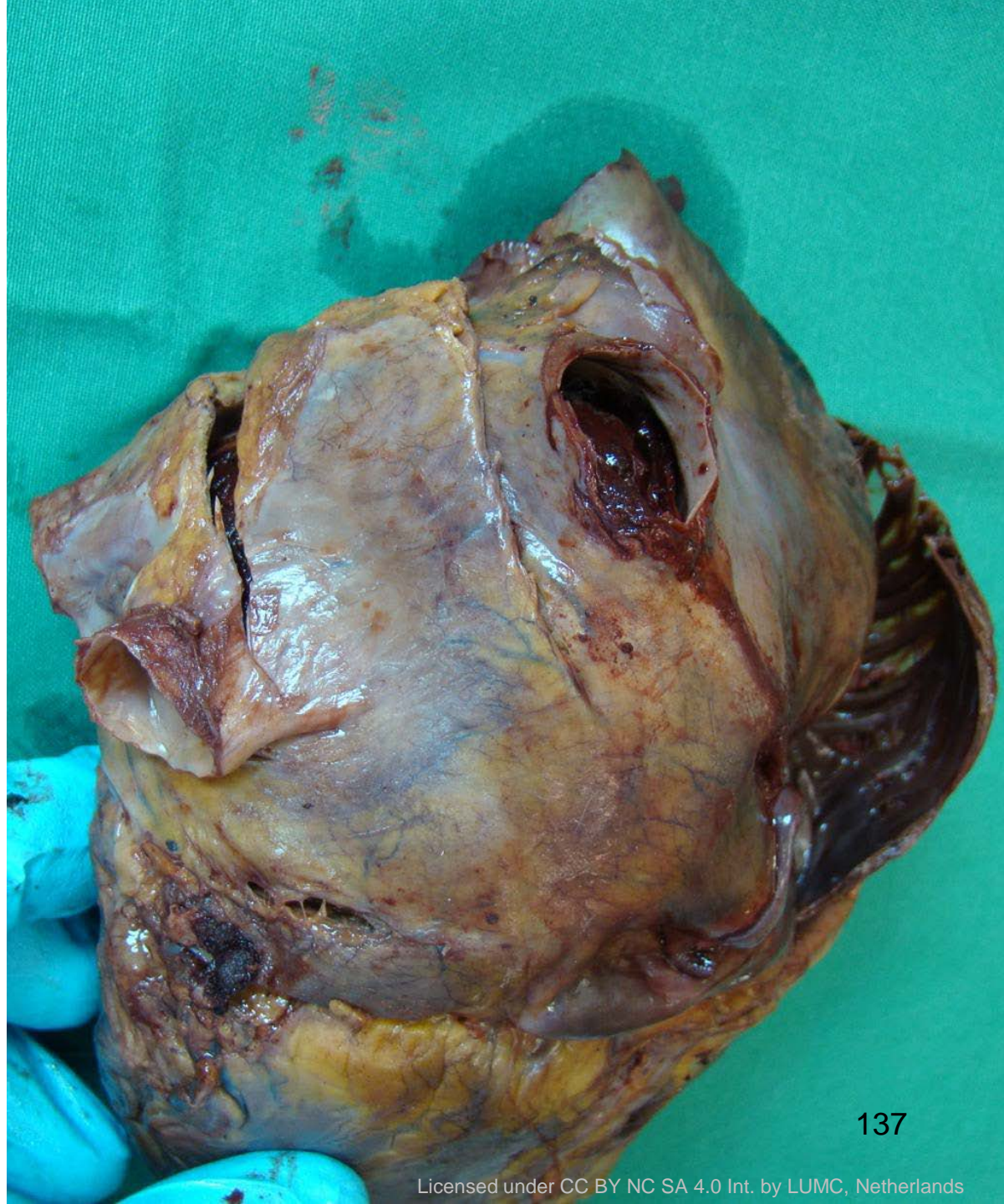

Pulmonary trunk

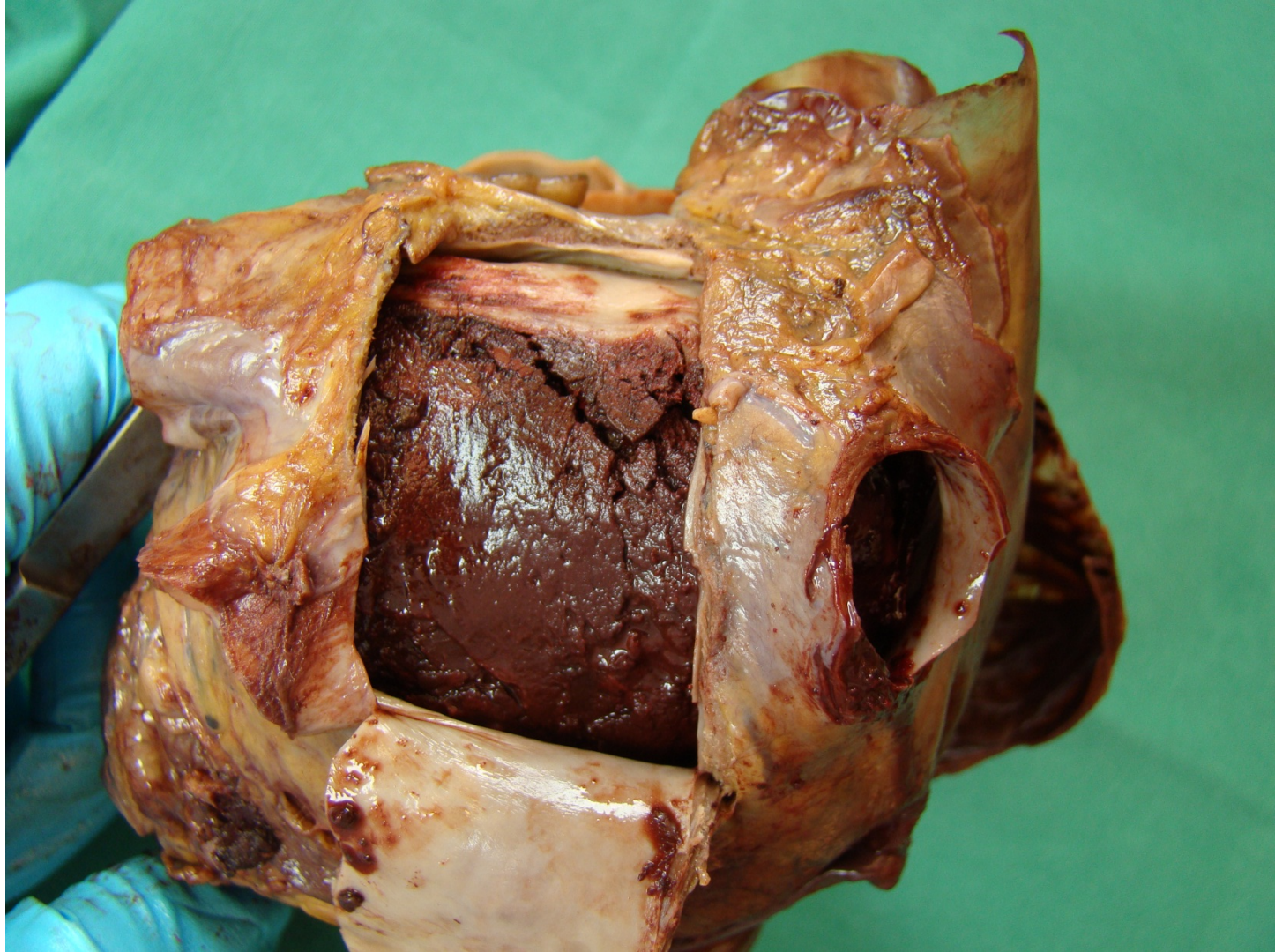


Opening the left atrium

Postero-inferior view

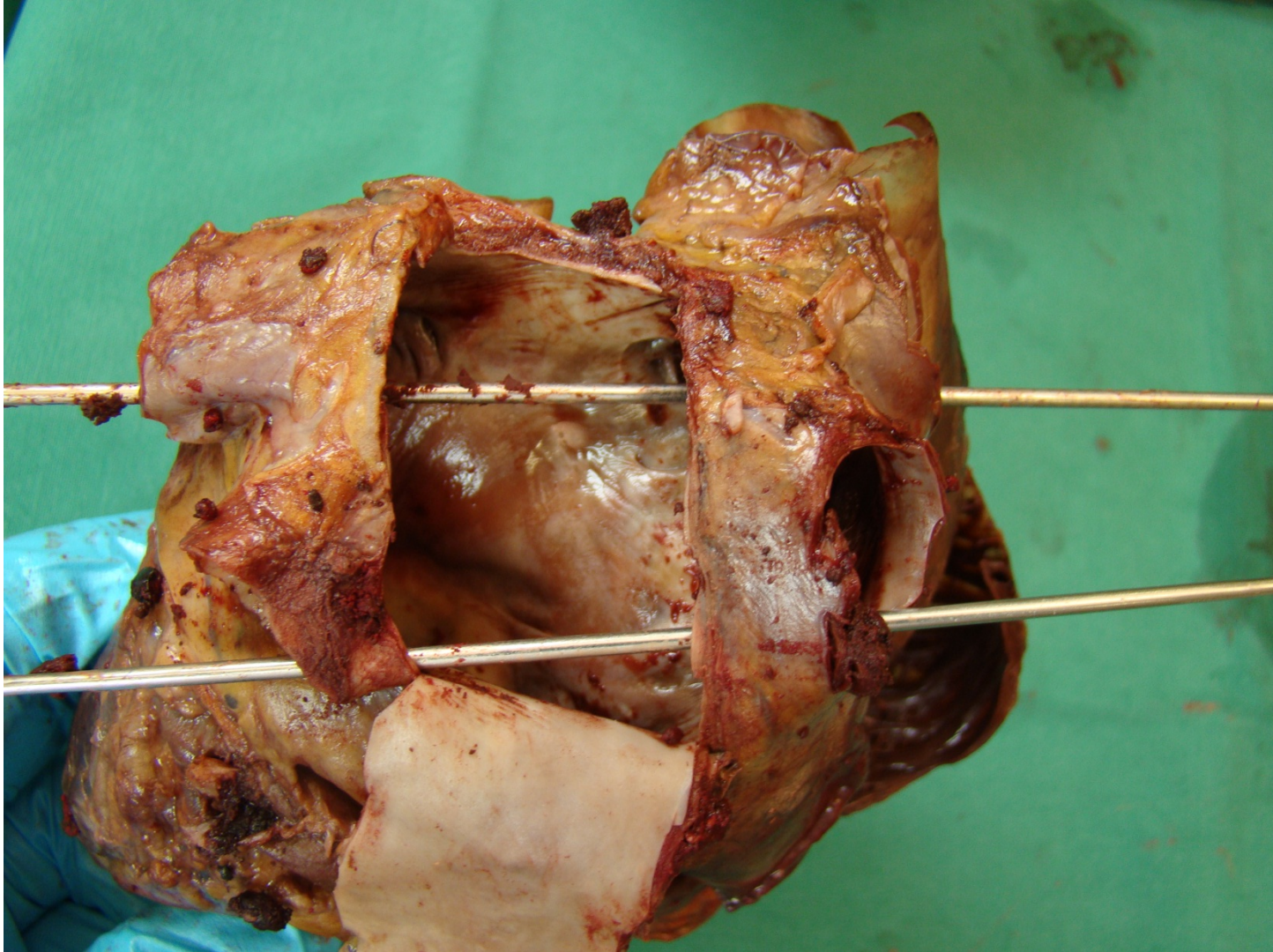


Blood clots
inside the
atrium



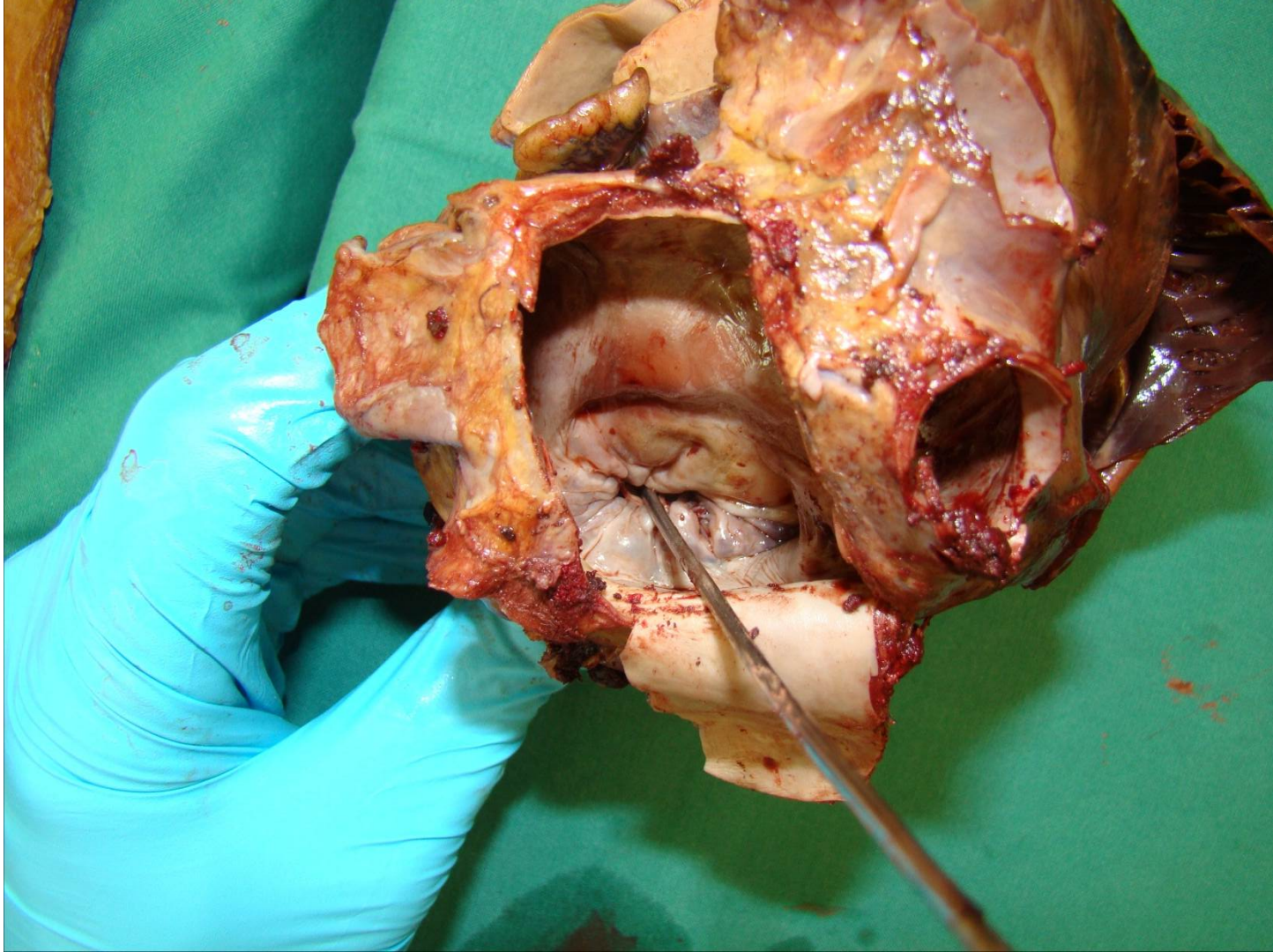
Postero-inferior view

Pulmonary
veins



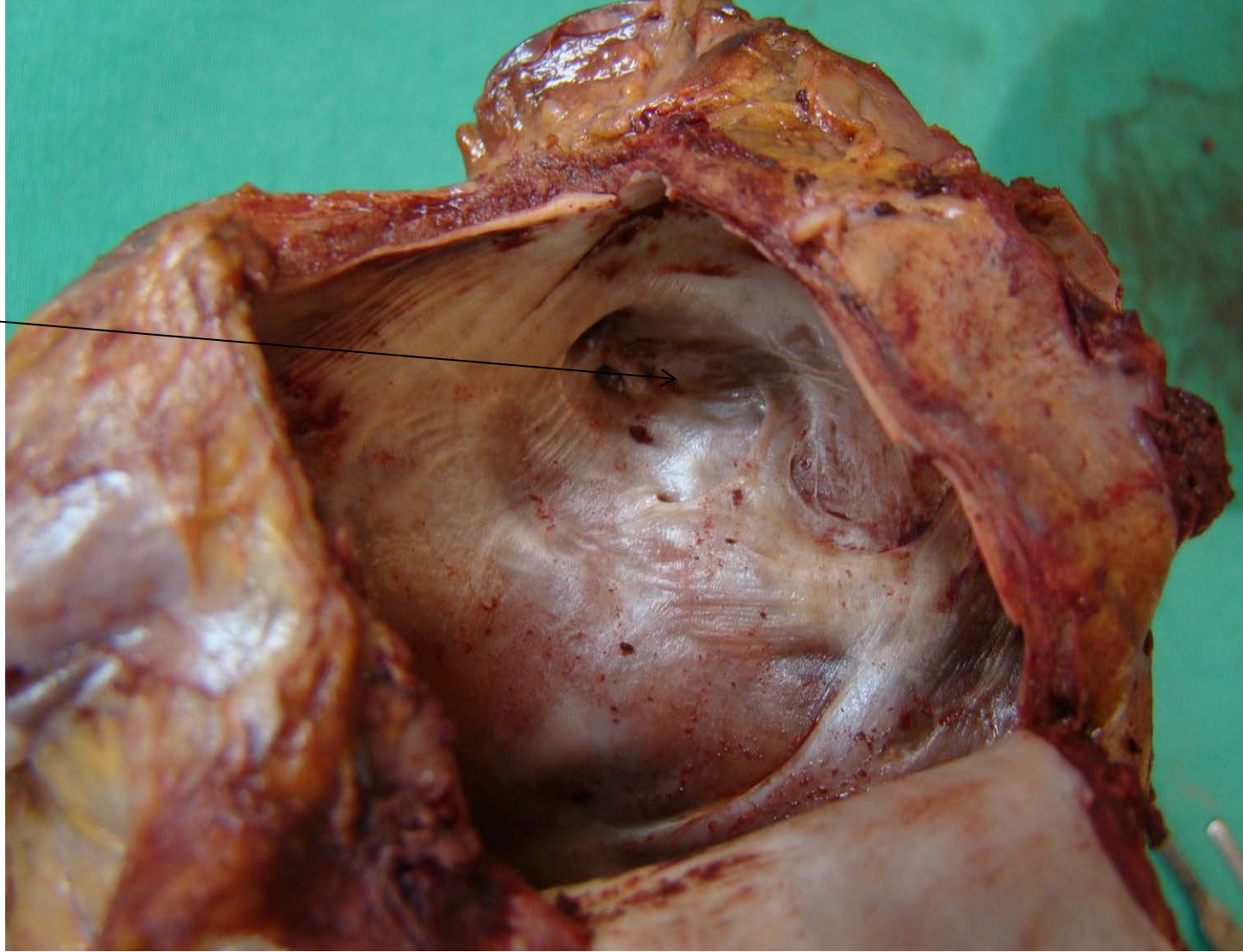
Postero-inferior view

Mitral valve



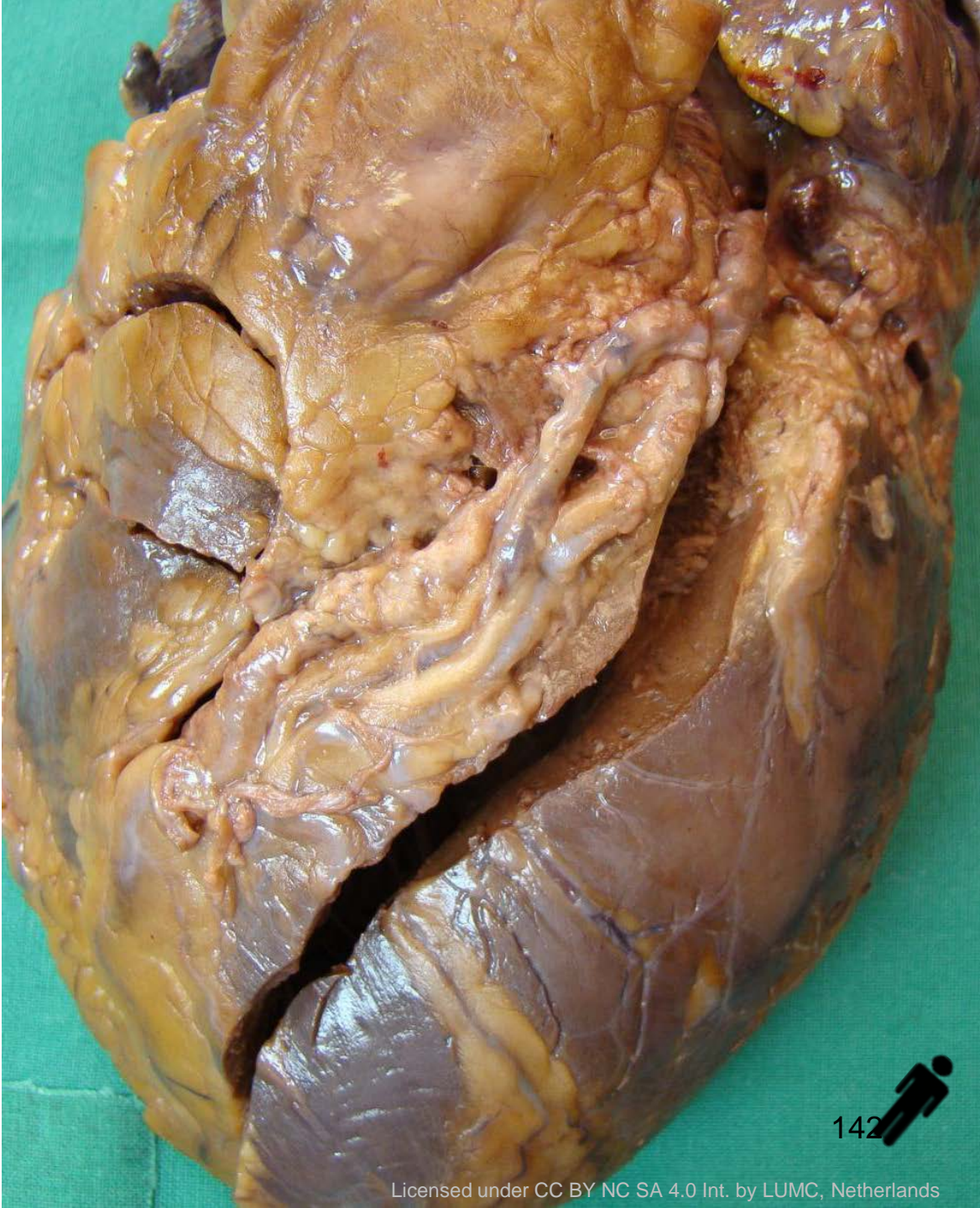
Postero-superior view

Fossa ovalis

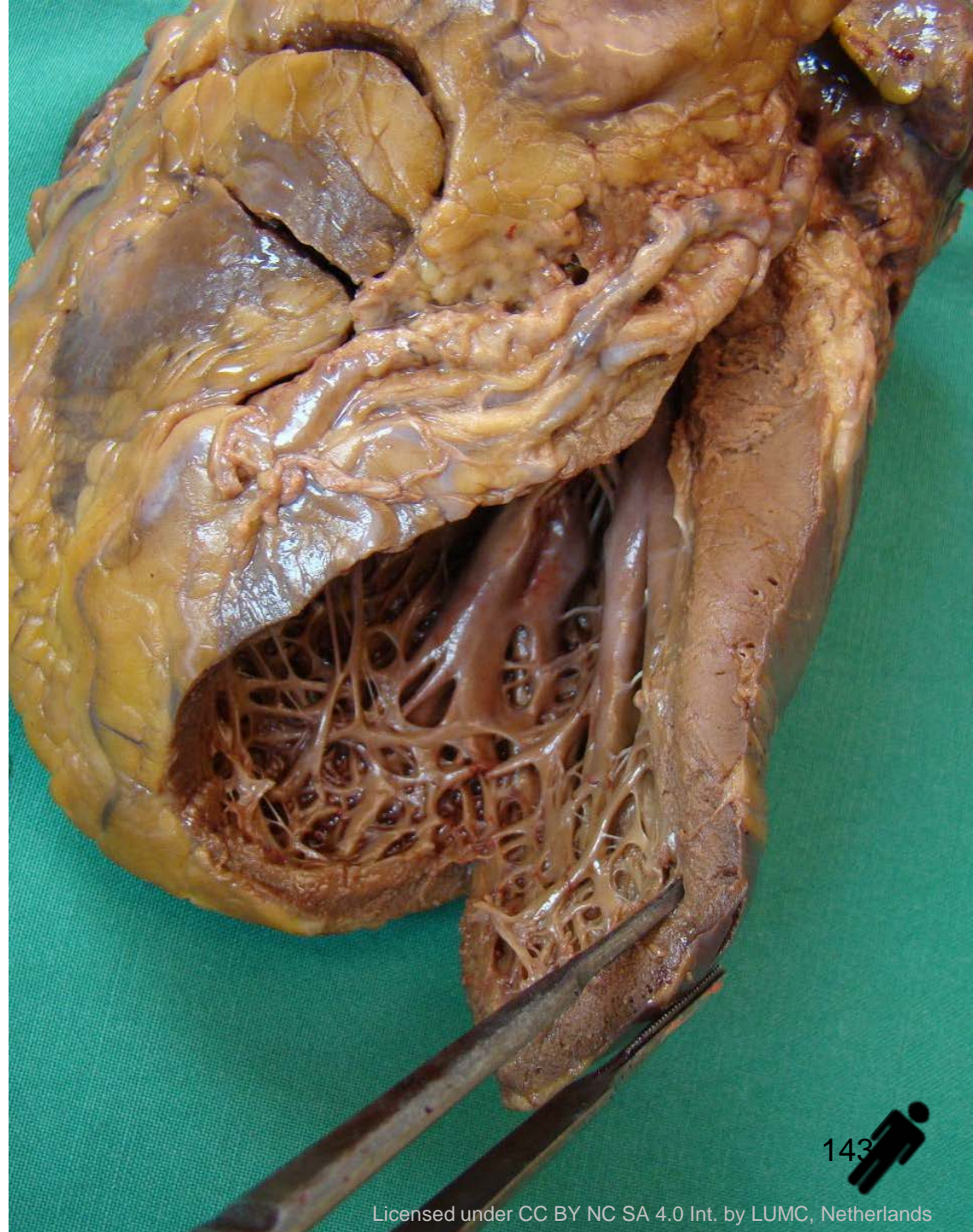


View from the left

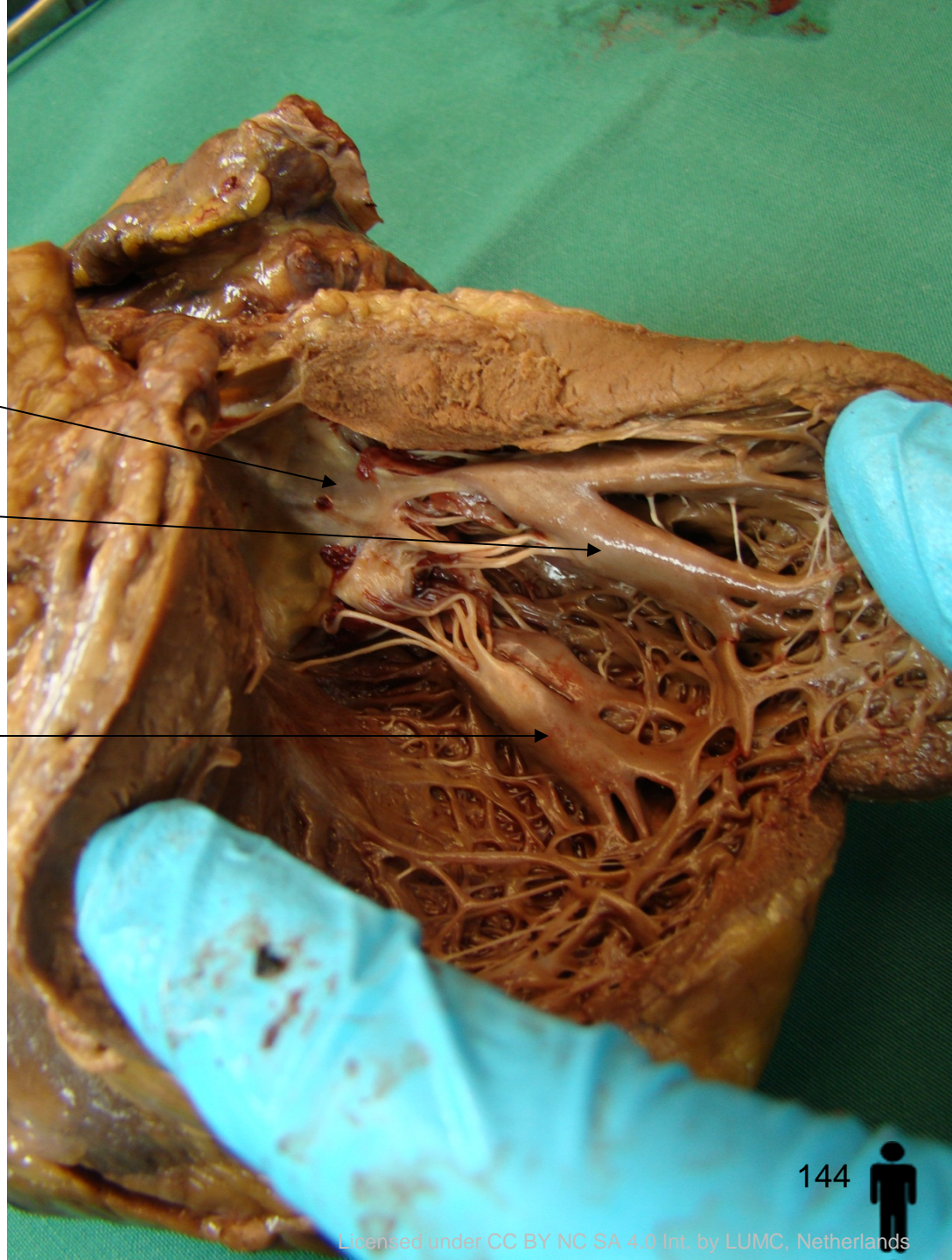
Opening of the left ventricle



Left ventricle



- Mitral valve
- Anterior papillary muscle
- Posterior papillary muscle

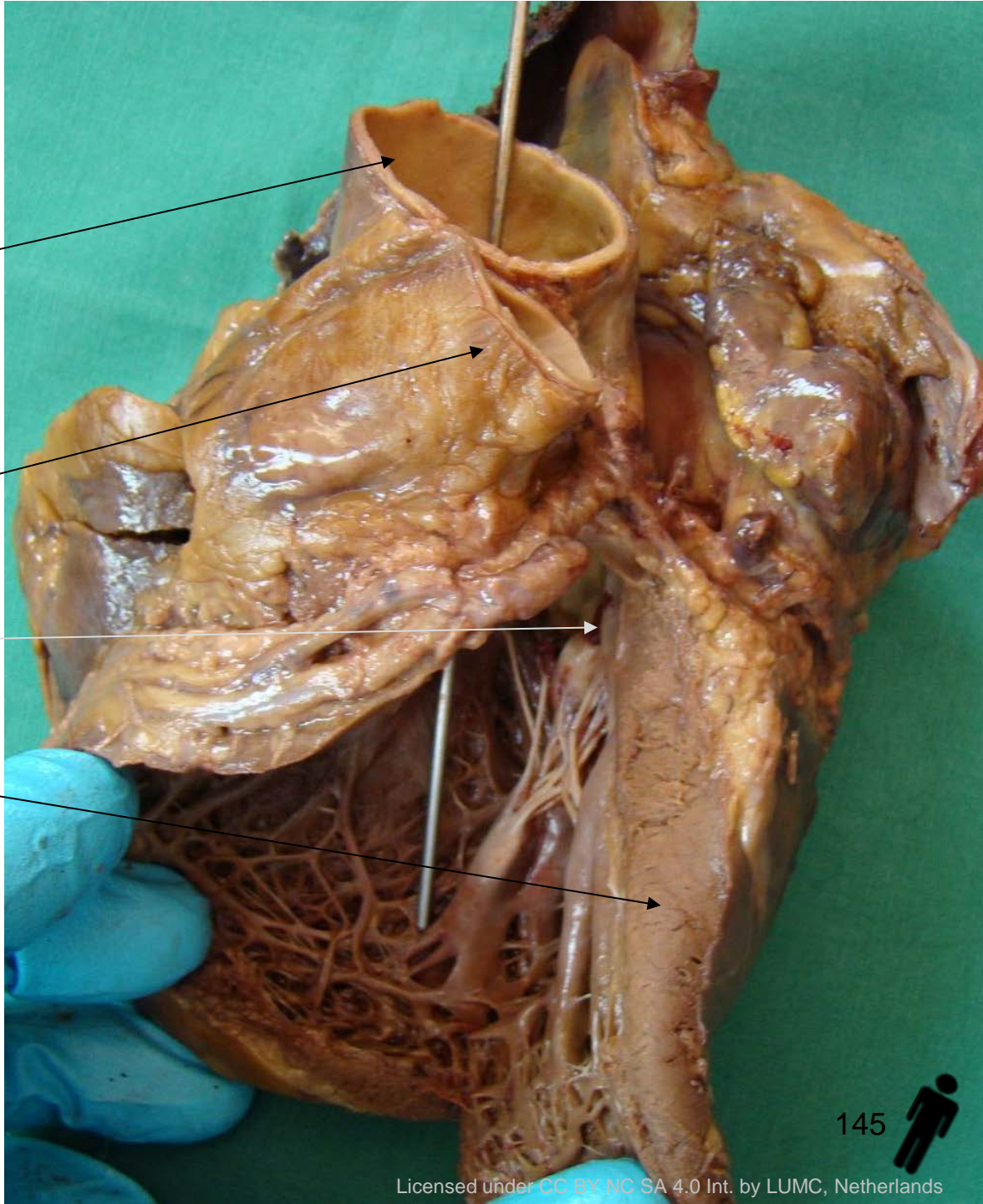


- Aorta

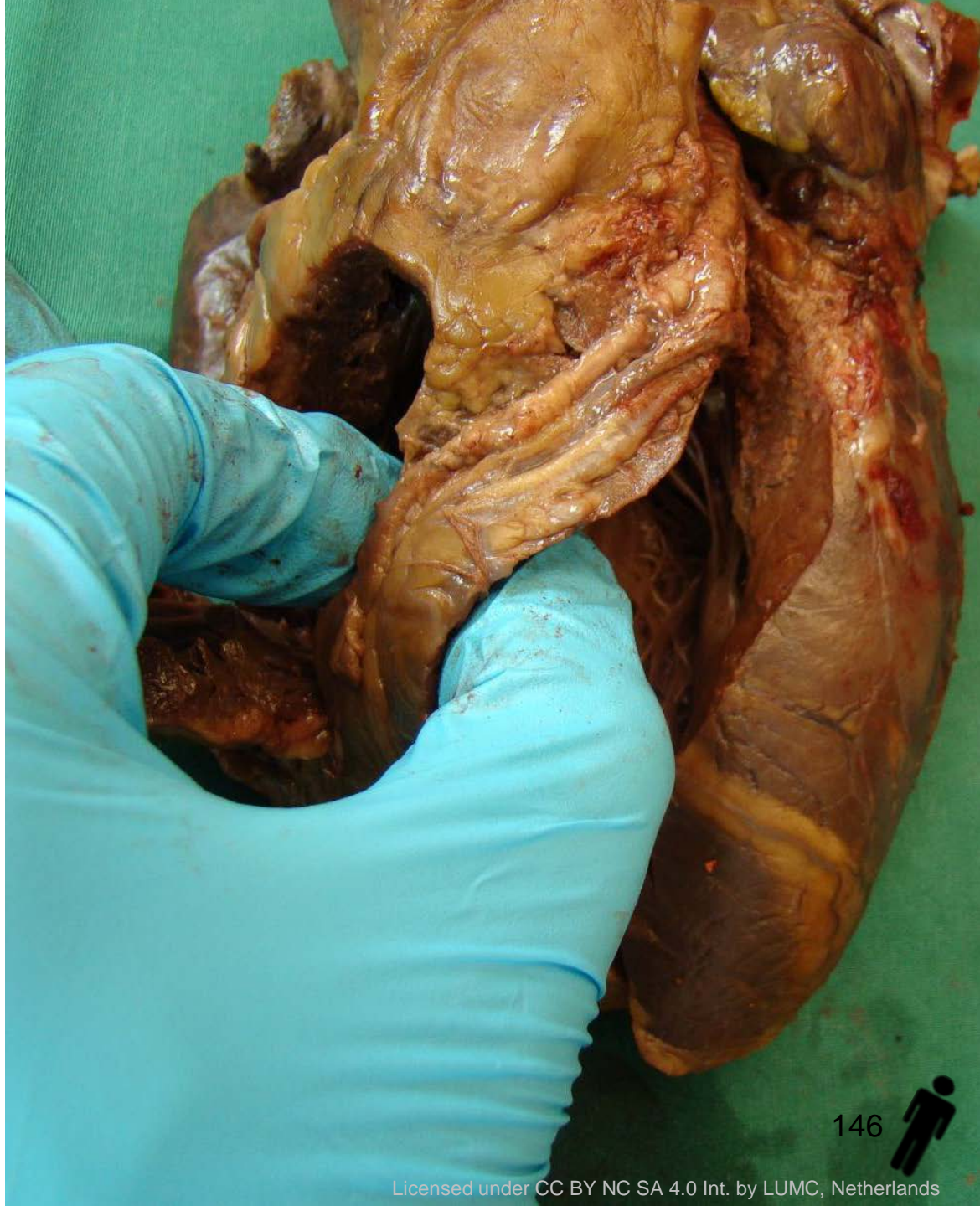- Pulmonary trunk

- Mitral valve

- Left ventricle wall



Interventricular wall (septum)

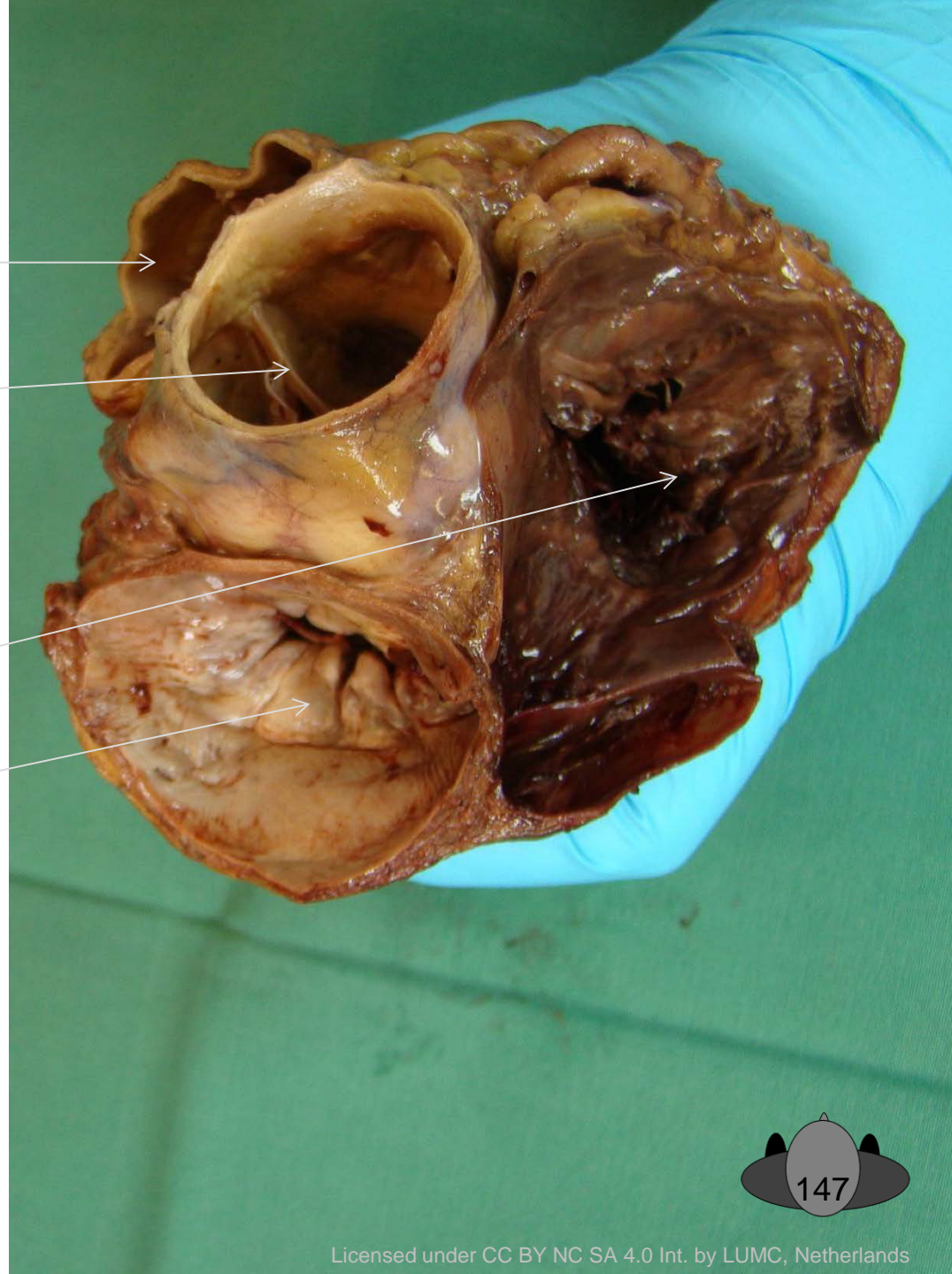


Pulmonary valve

Aortic valve

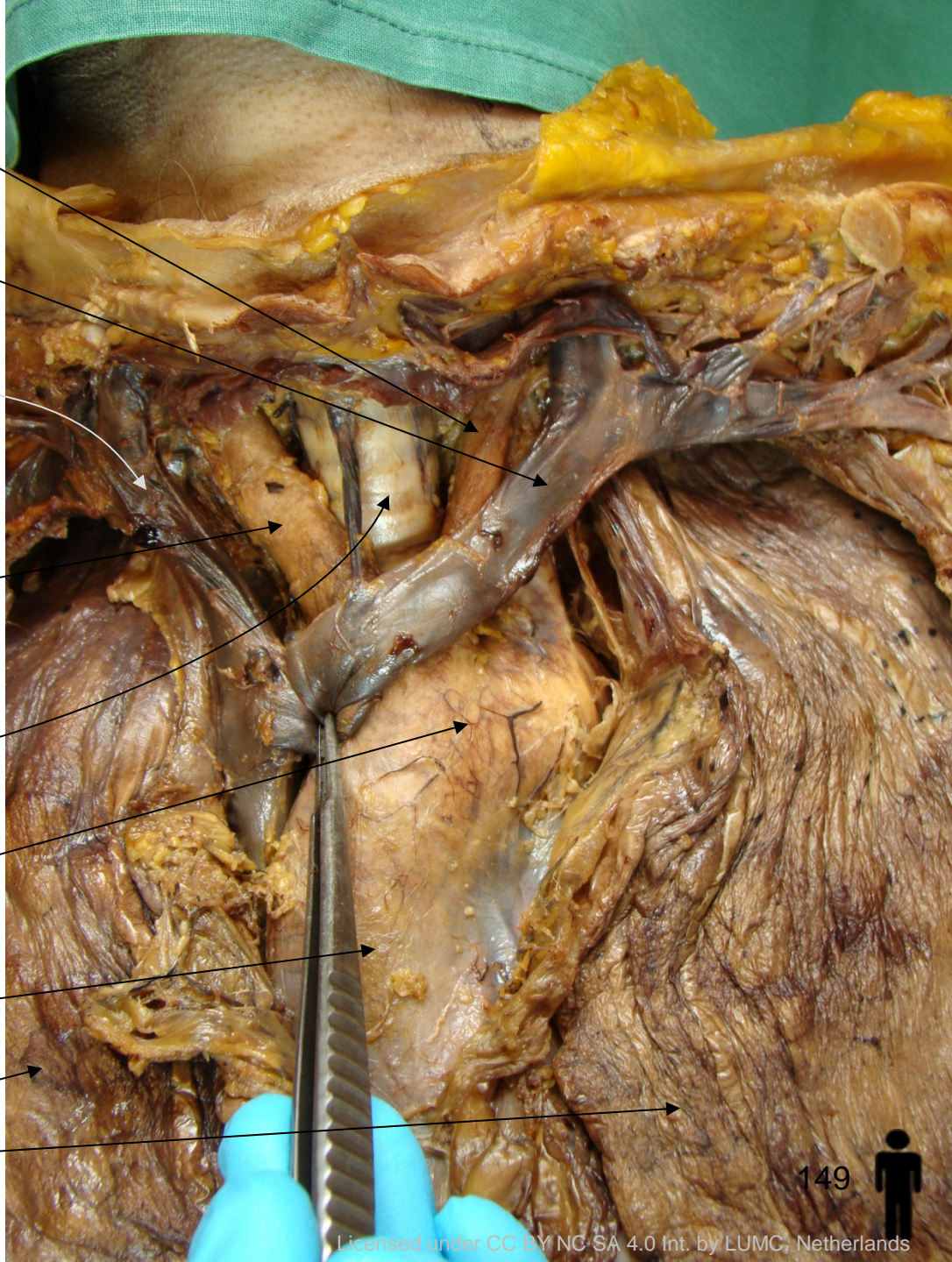Tricuspid valve

Mitral valve



Mediastinum

- Left common carotid artery
- Left brachiocephalic vein
- Right brachiocephalic vein
- Right brachiocephalic trunk (artery)
- Trachea
- Aortic arch
- Ascending aorta
- Lungs

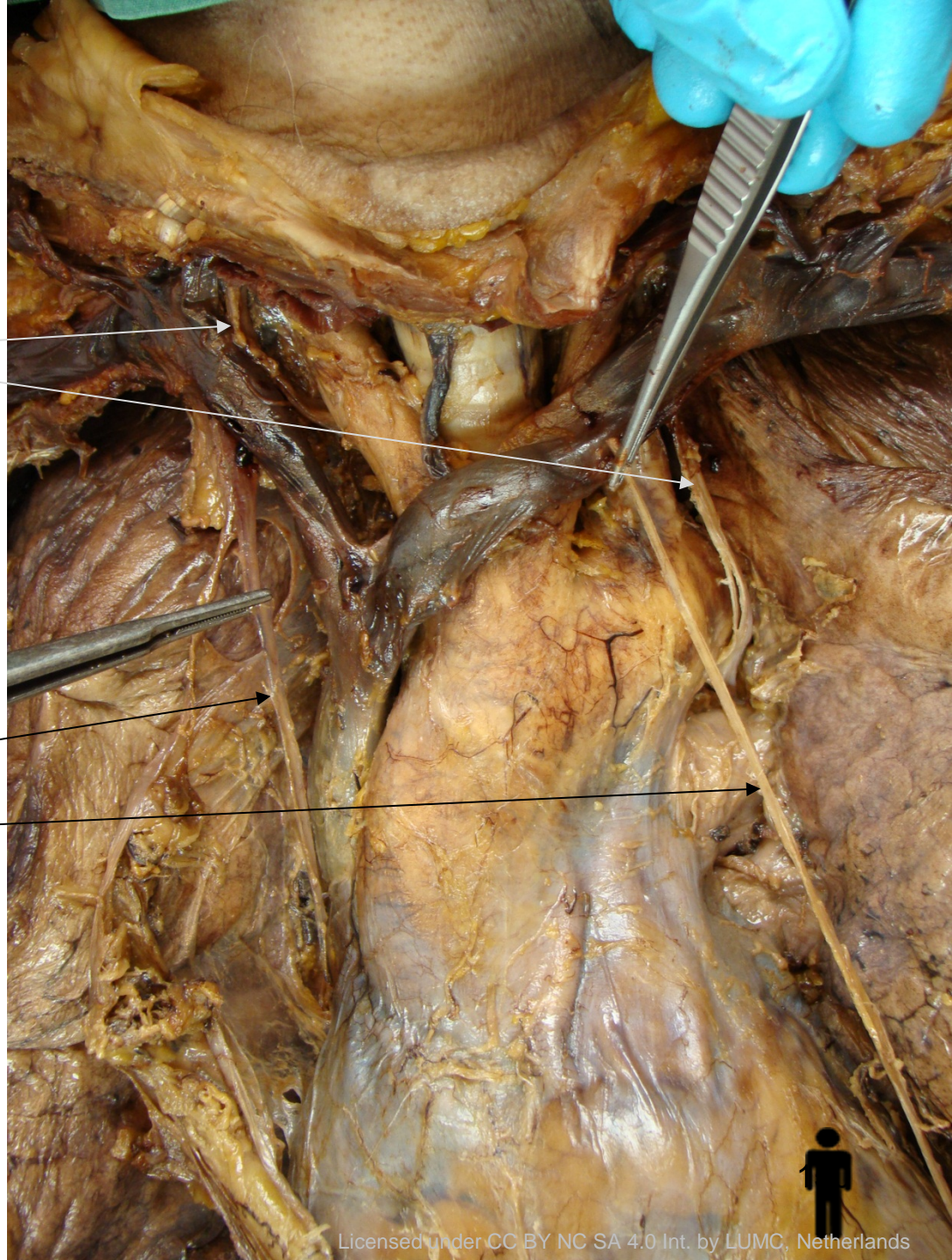

- Vagus nerves

- Right phrenic nerve

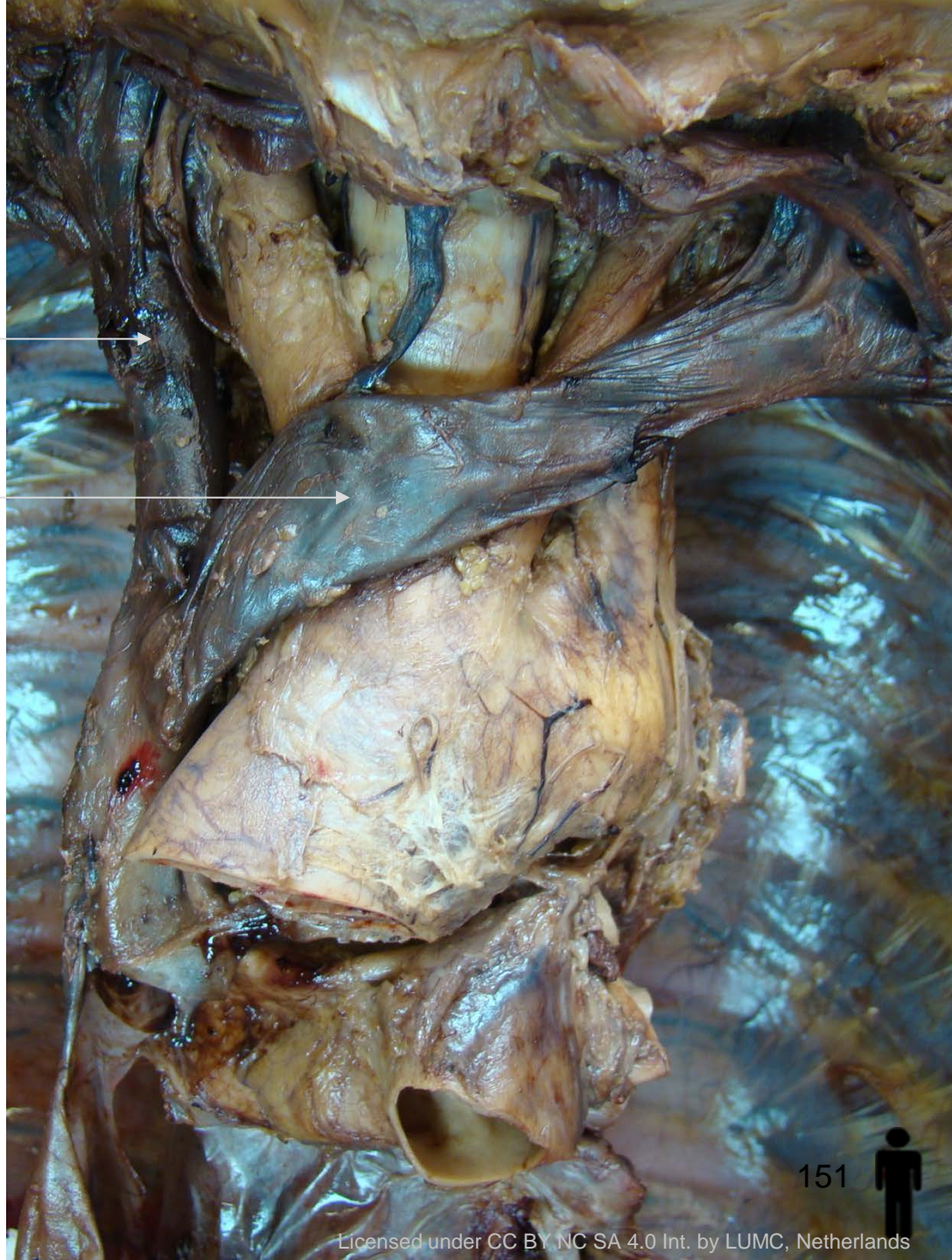
- Left phrenic nerve

(Note: is held medially displaced by the pinchers, normally courses laterally of vagus nerve)



Right brachiocephalic vein

Left brachiocephalic vein

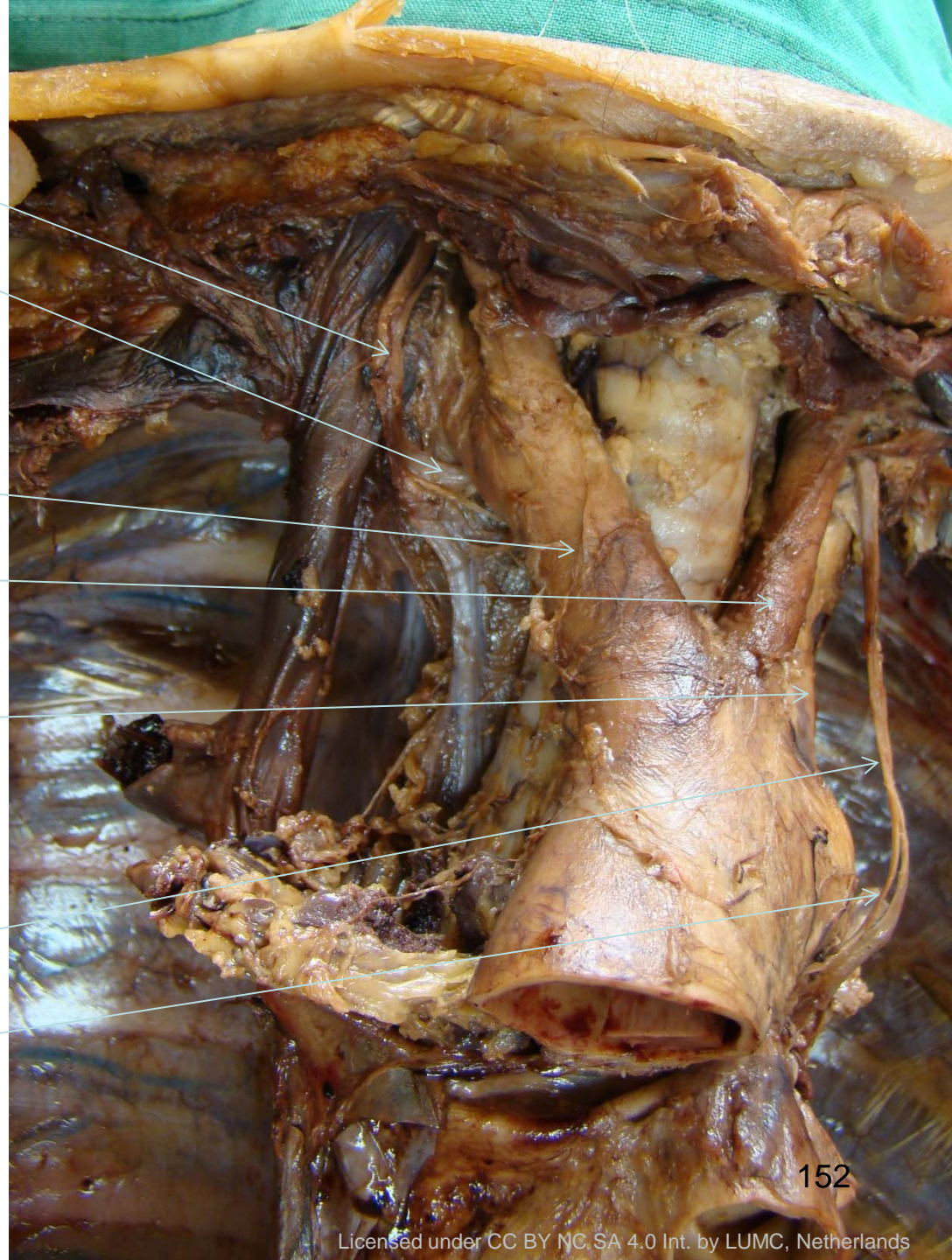

Right vagus nerve
Right recurrent laryngeal nerve

Brachiocephalic trunk
Left common carotid artery
Left subclavian artery

Left vagus nerve
Left recurrent laryngeal nerve

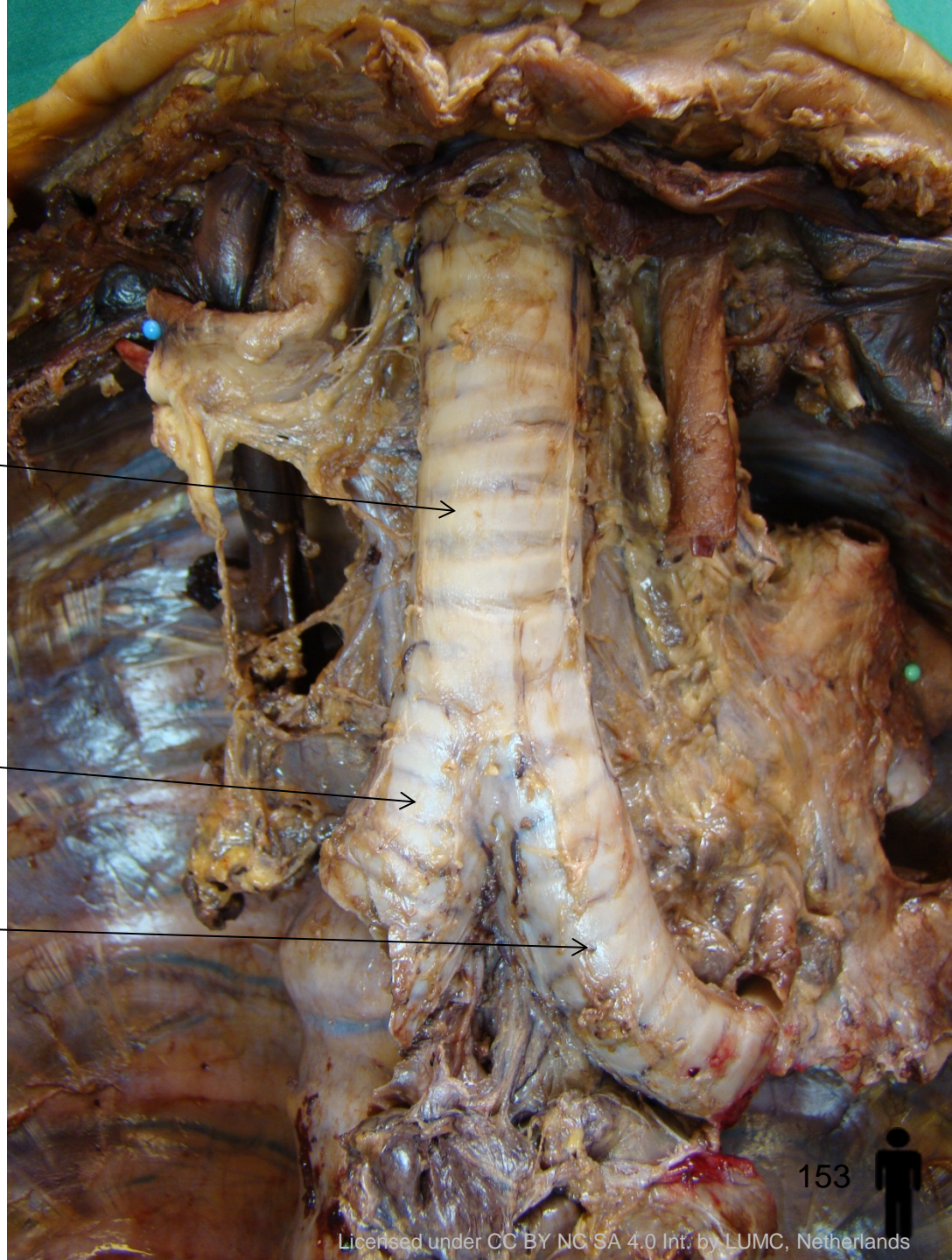View slightly from the right



Trachea

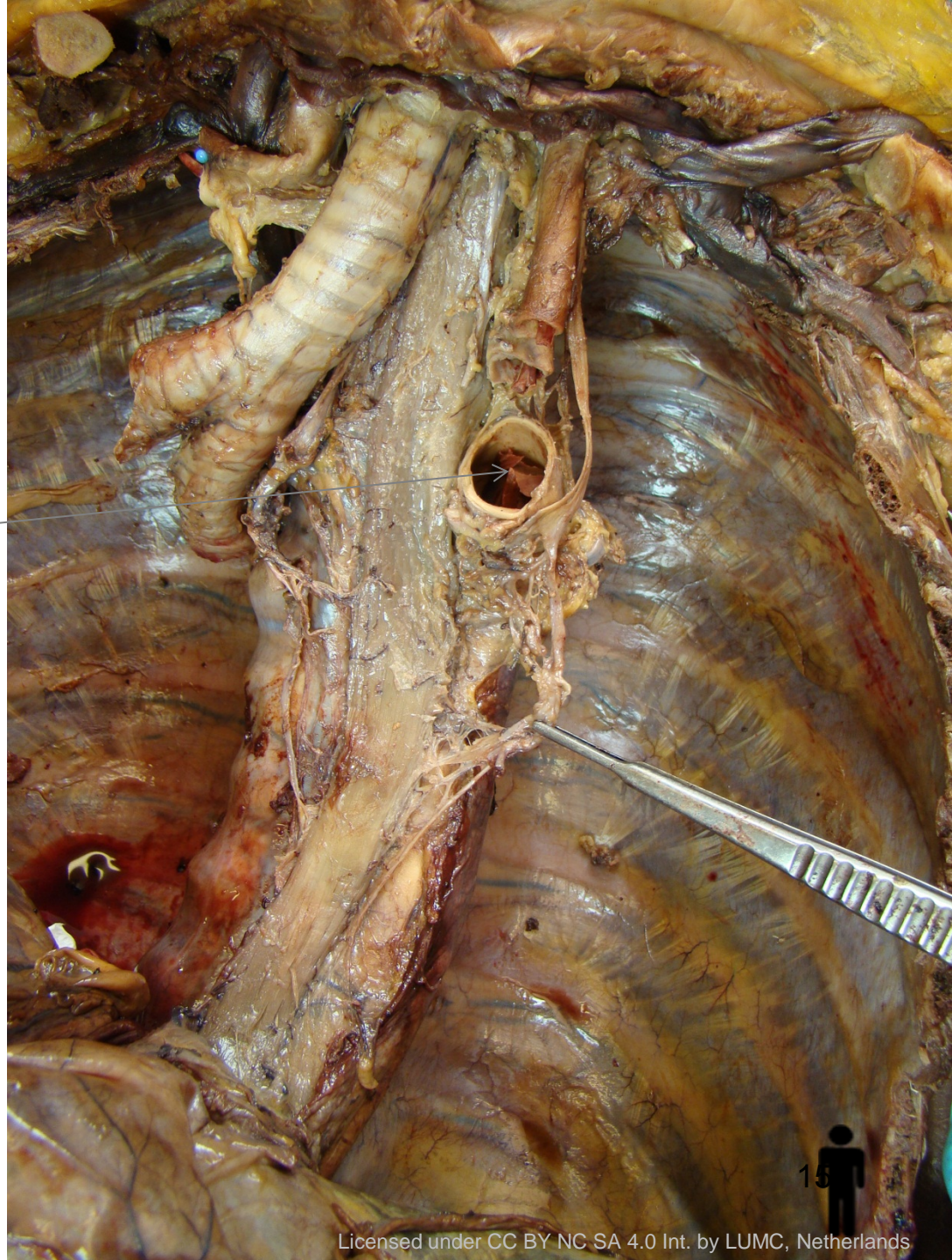Right main bronchus

Left main bronchus



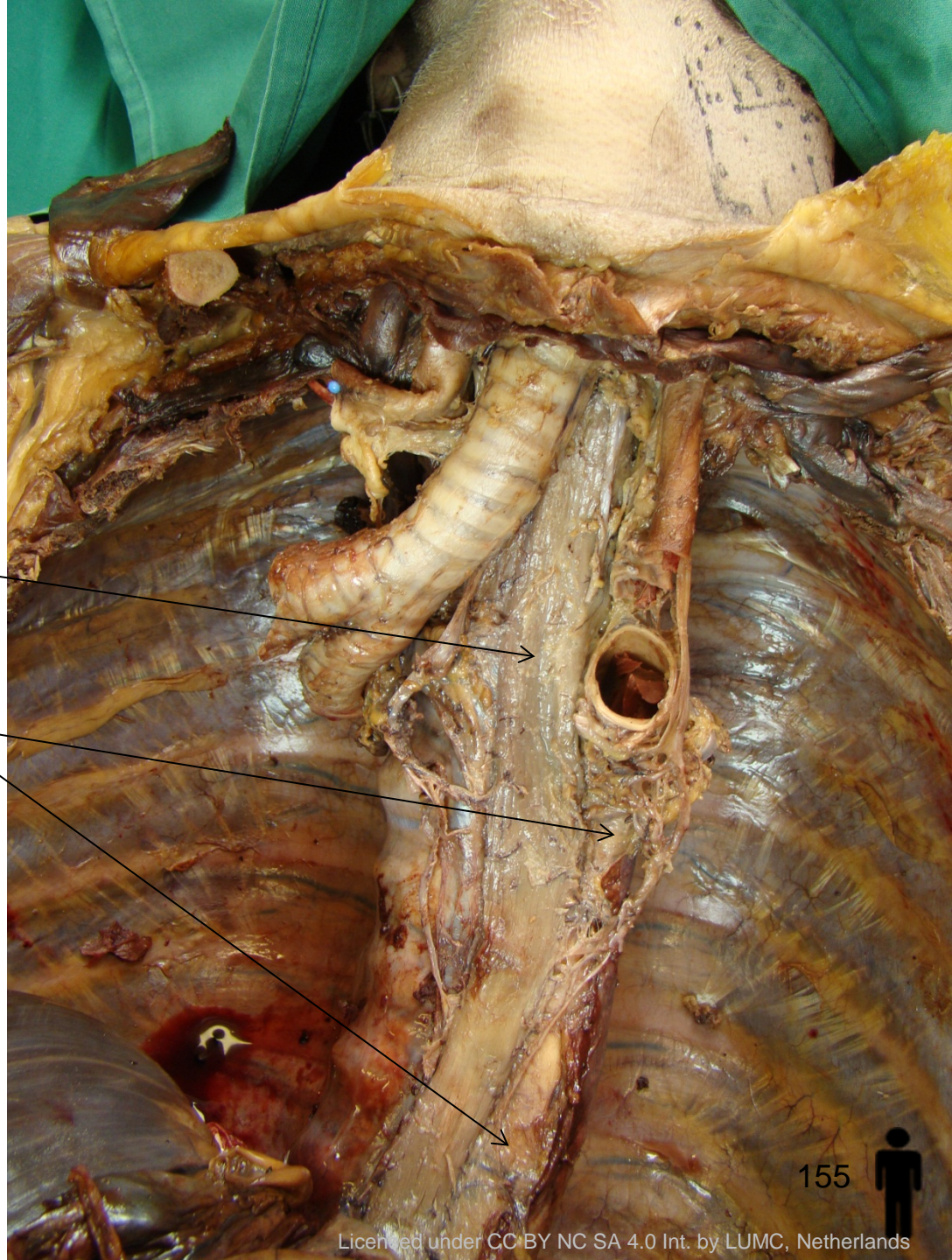Both vagus nerves are
behind the lung's hilum

cut aorta



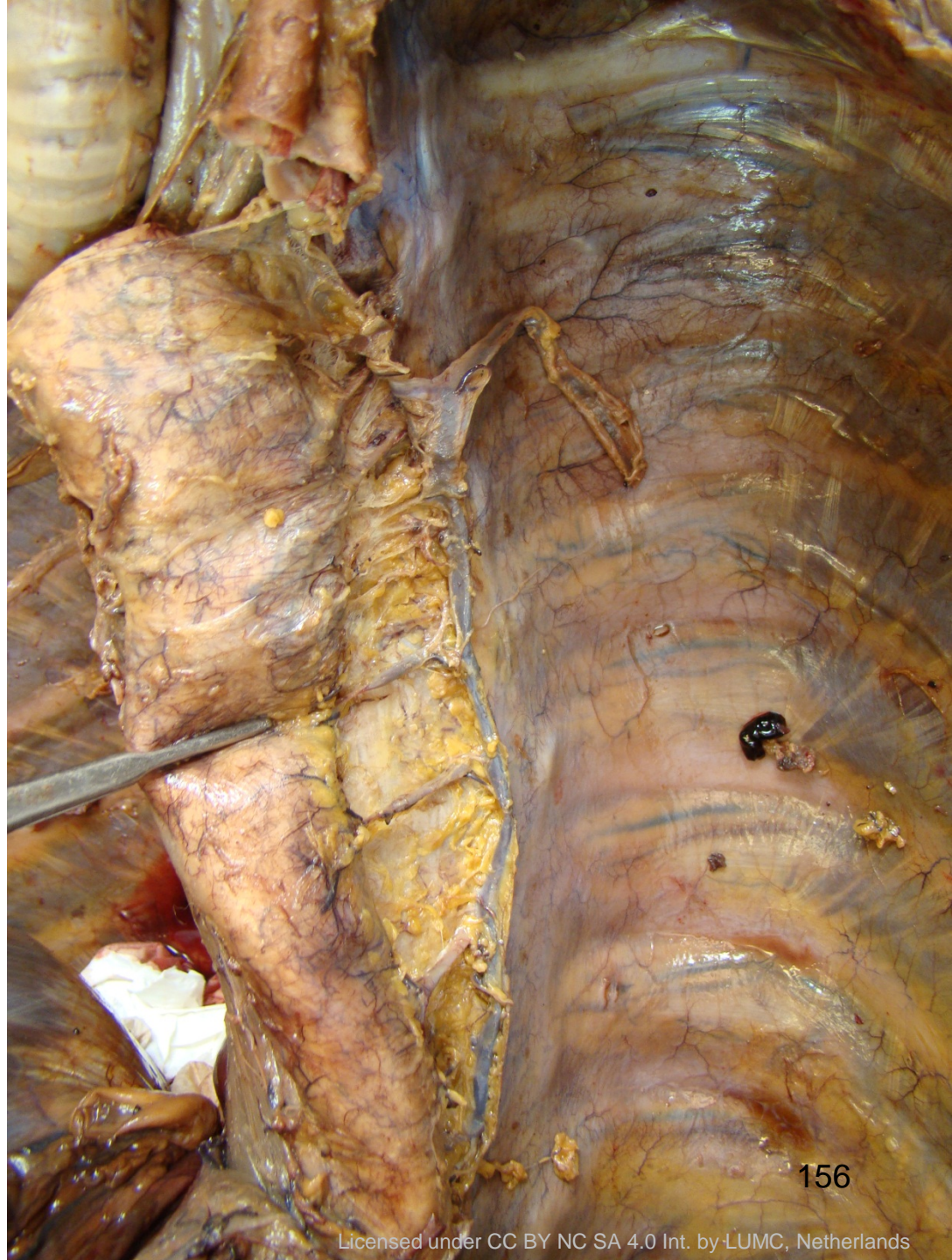Esophagus

Descending aorta



Posterior intercostal arteries

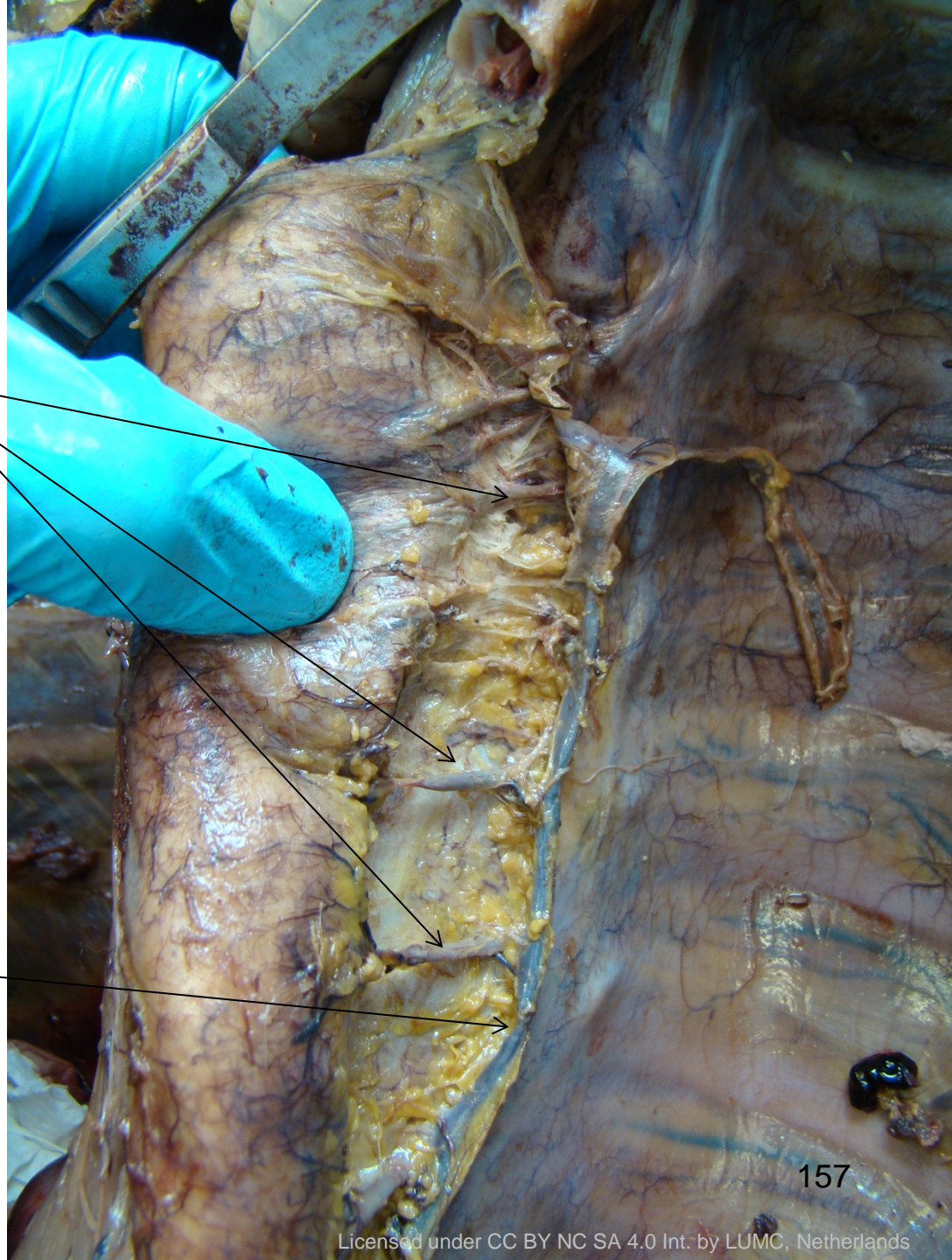View at left side of aorta



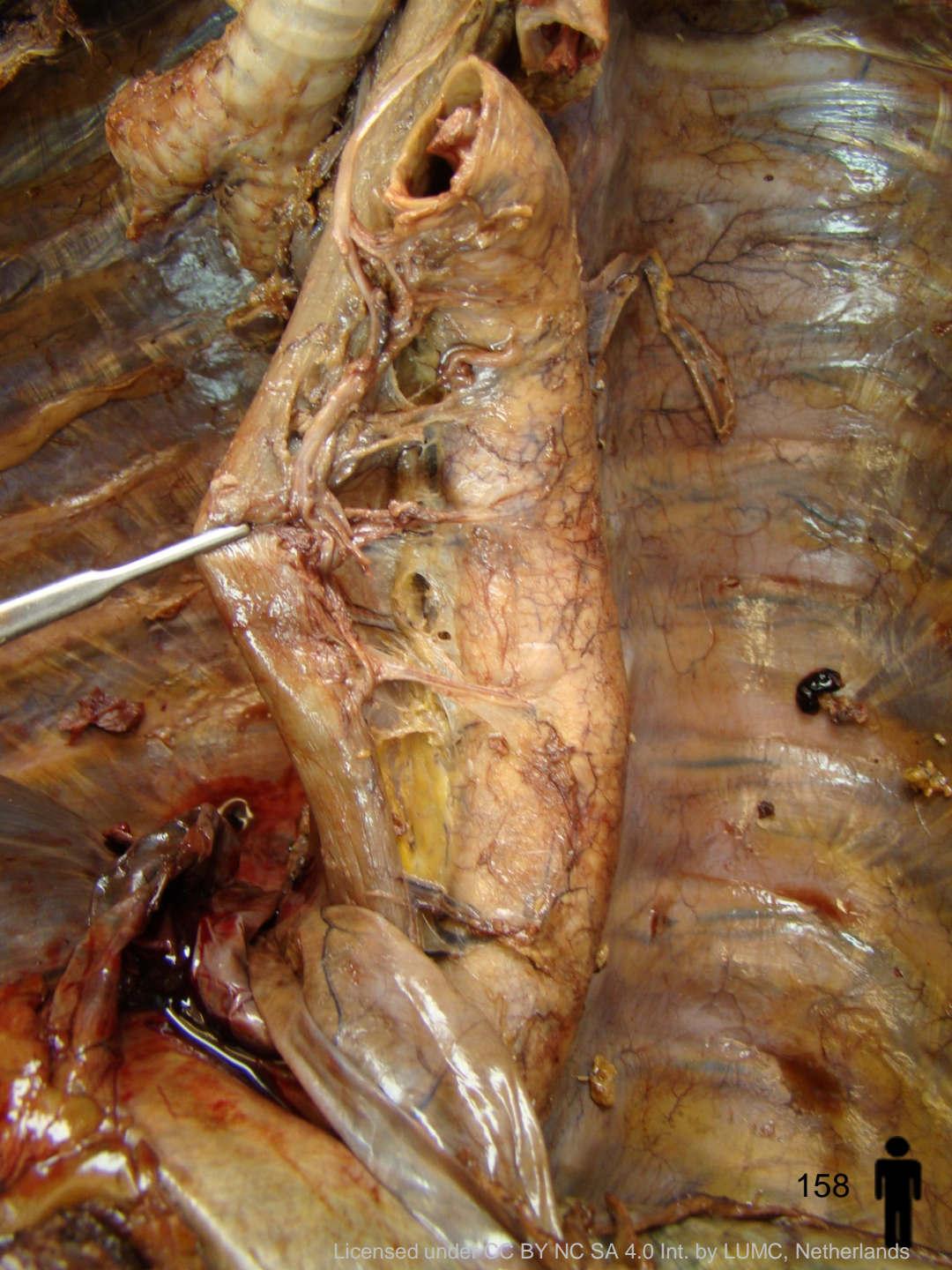Posterior intercostal
arteries

Superior hemi azygos
vein

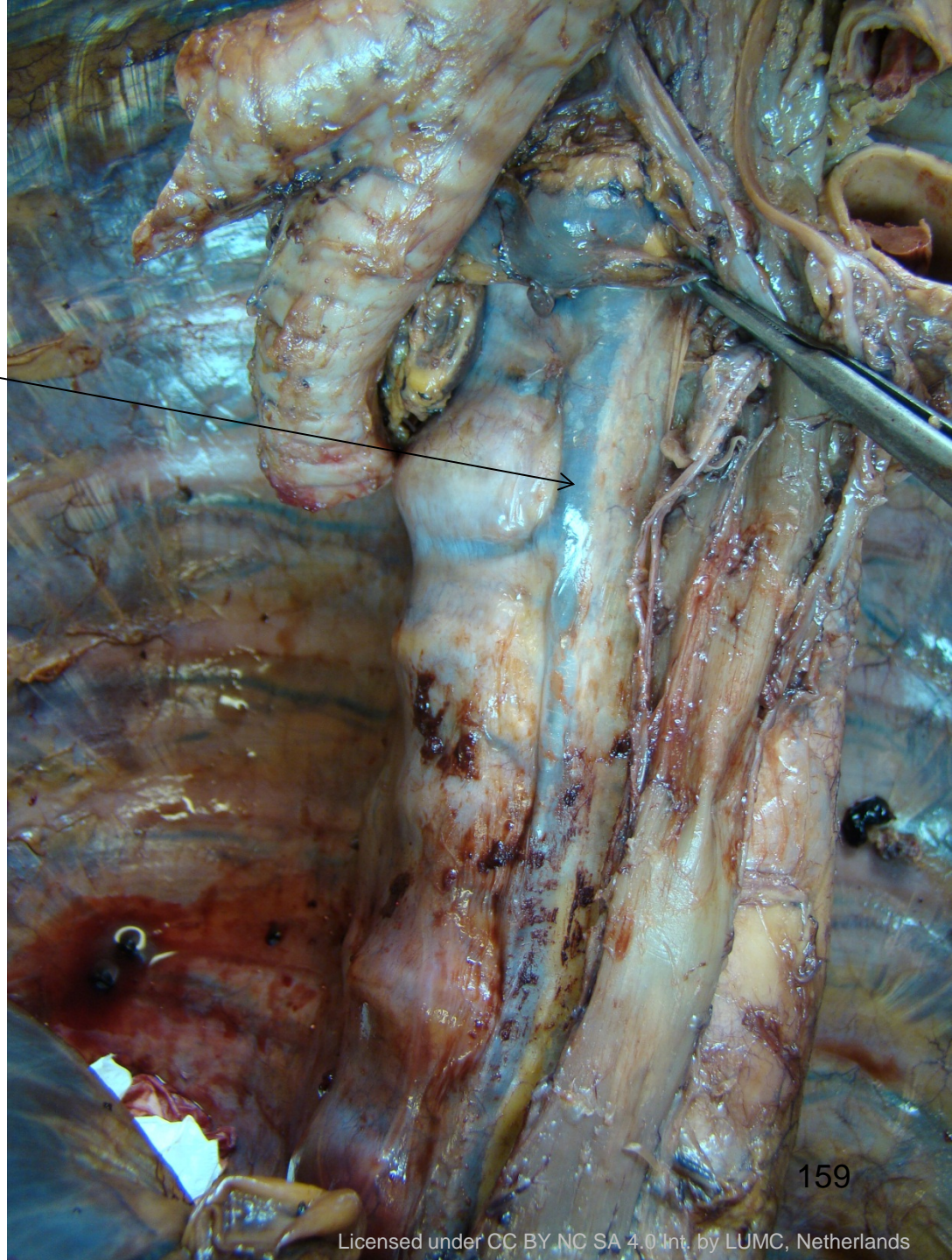
View at left side of aorta



Esophageal arteries

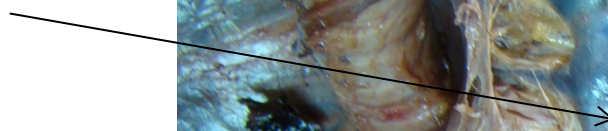


Azygos vein

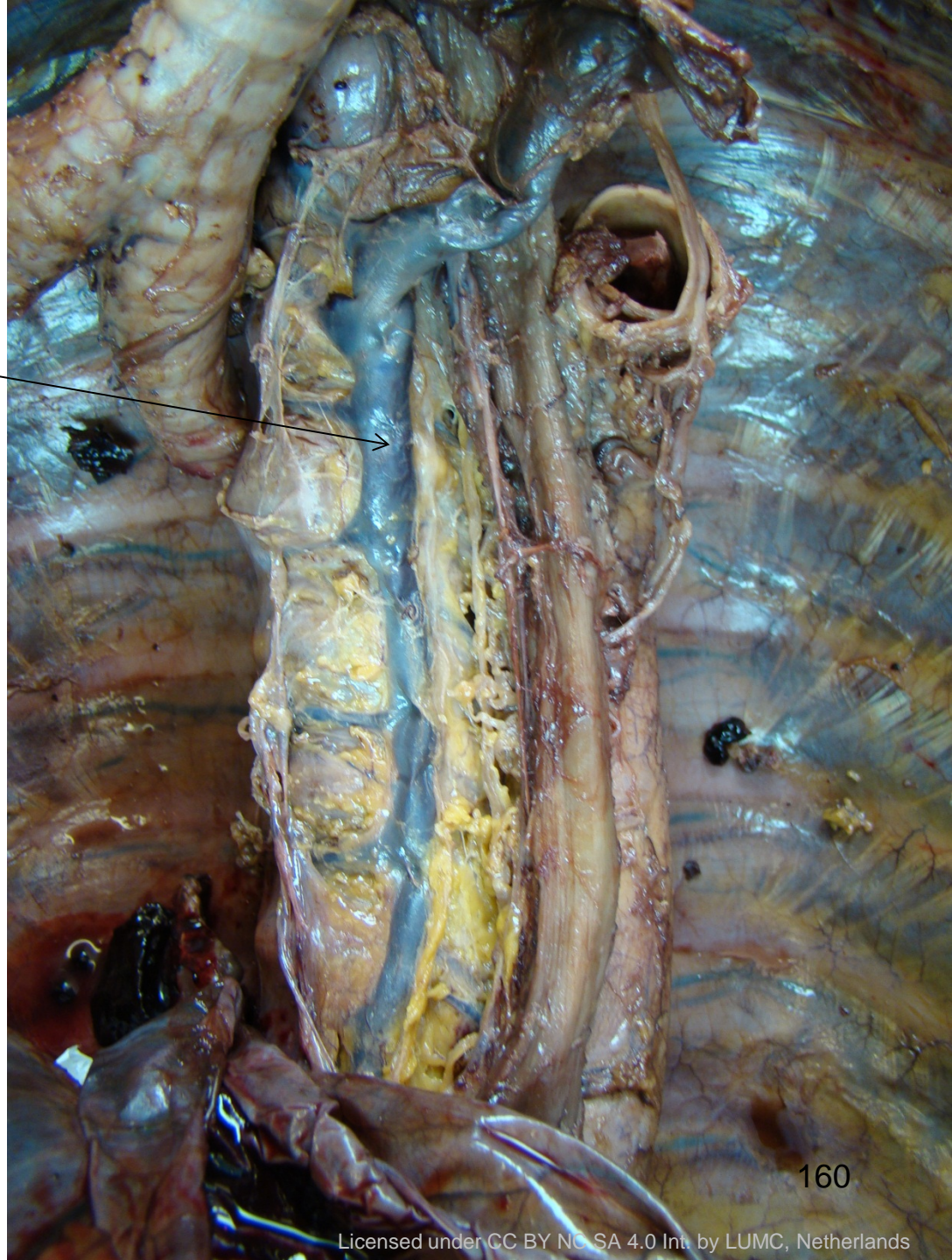

View at right side of
vertebral column

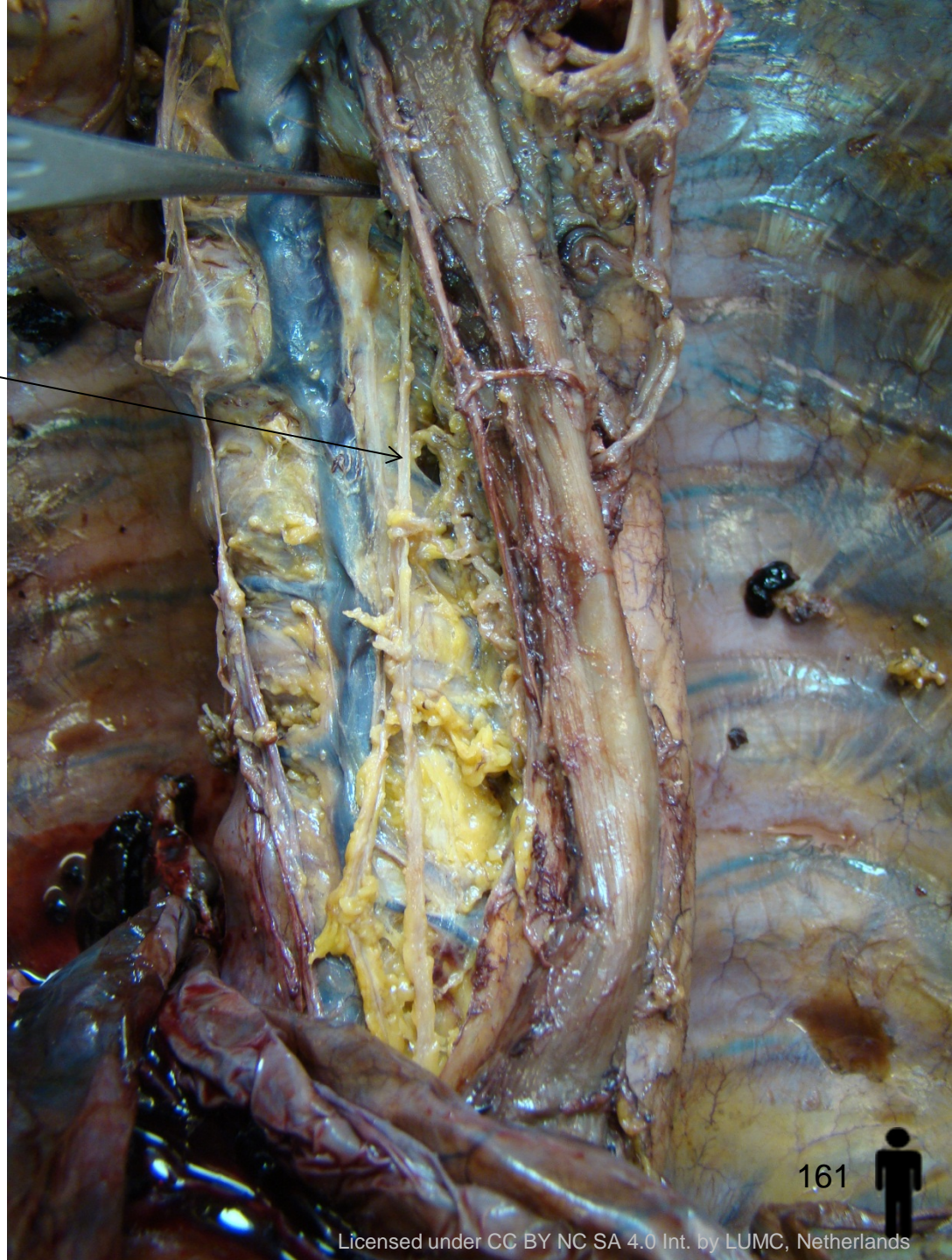Azygos vein



View at right side of
vertebral column



Thoracic duct



We gratefully thank the people
who were willing to donate
their bodies for medical
teaching.

They enable us to see the
anatomy in reality.