



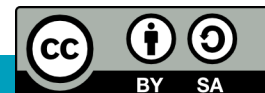
Leids Universitair
Medisch Centrum

Pelvis - bony parts, ligaments and passways

O. Paul Gobée, M.D.

Dept. Anatomy & Embryology

LEIDEN UNIVERSITY MEDICAL CENTER



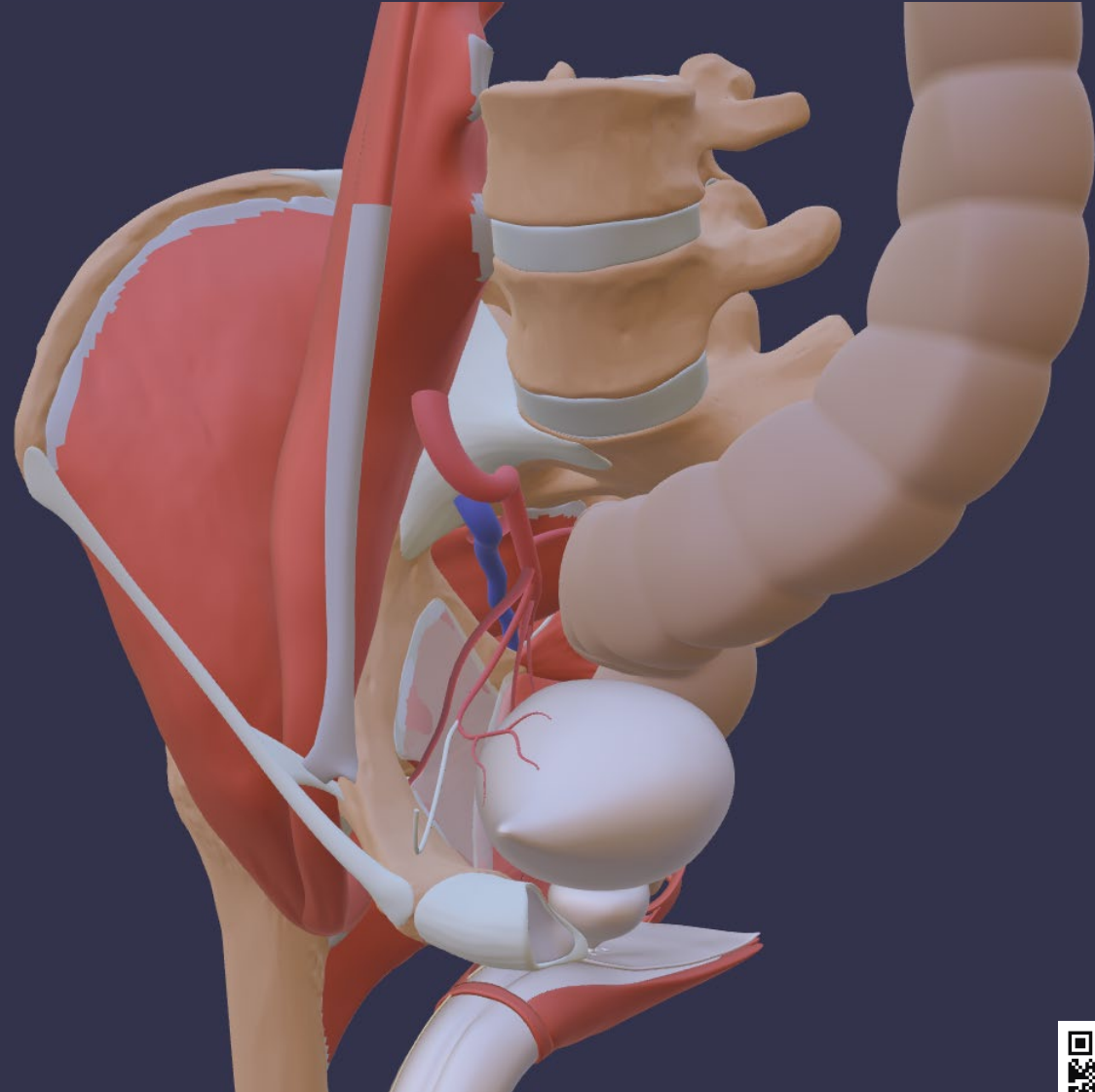
Open anatomical 3D model

Images in this presentation are retrieved from the *Sub model 'Pelvic floor and perineum' (untextured)* by Marco C. DeRuiter, Eungyeol Lee, Daniël Jansma and Paul Gobée (all at LUMC). It is licensed under Creative Commons Attribution ShareAlike (CC BY SA).

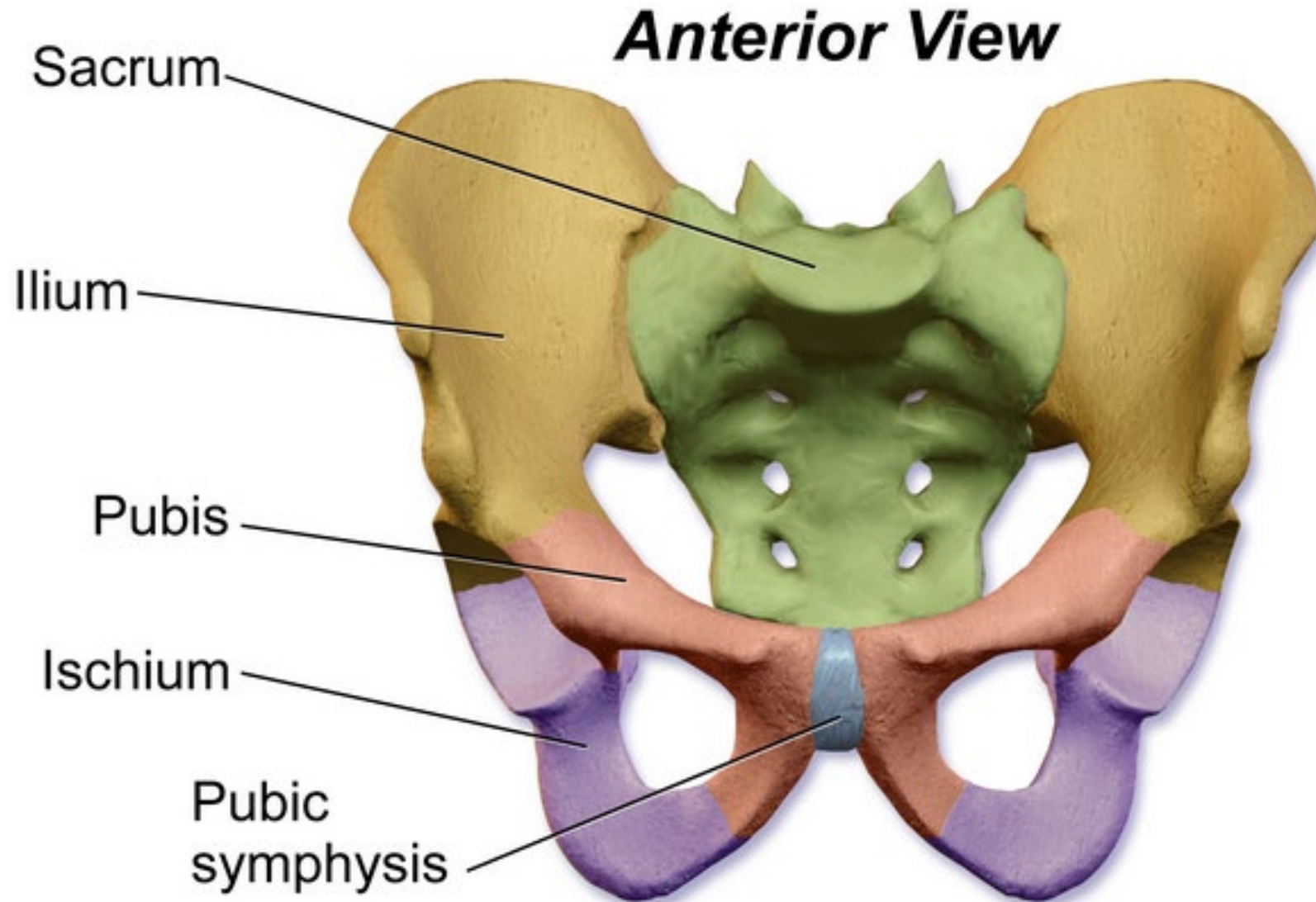
<https://anatomytool.org/content/open3danatomy-3d-model-pelvic-floor-and-perineum-english-labels>



This is a sub model of the ***Open Anatomical 3D model***, which was developed by LUMC, UMCU, UM and KU Leuven, with an initial grant of the Dutch Ministry of Education, Culture & Science. It was based on predecessor models BodyParts and Z-Anatomy, which are licensed under Creative Commons Attribution ShareAlike (CC BY SA).

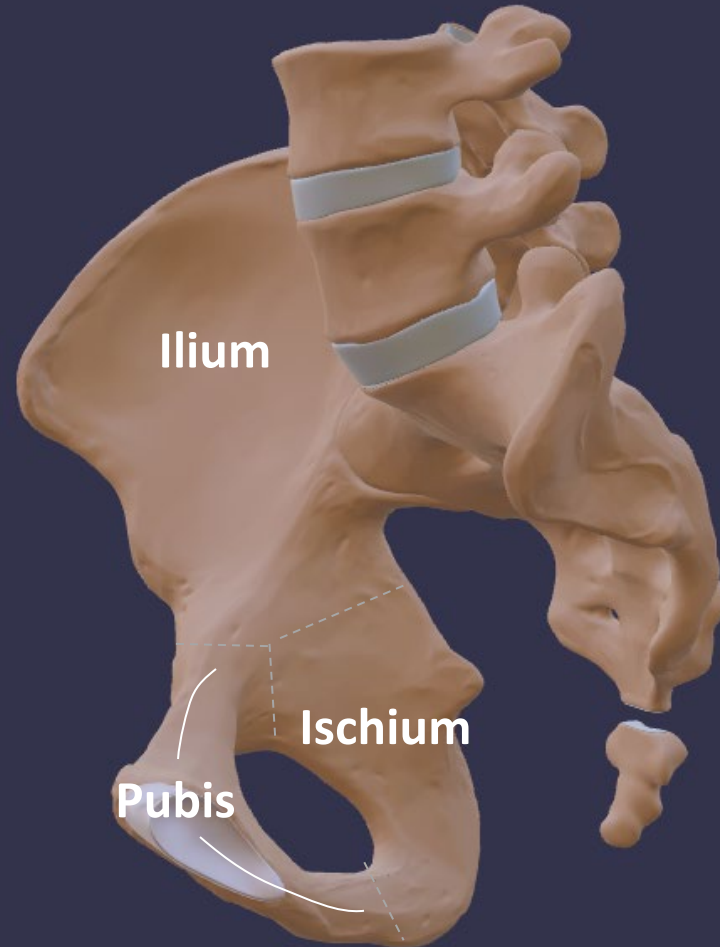


Bones



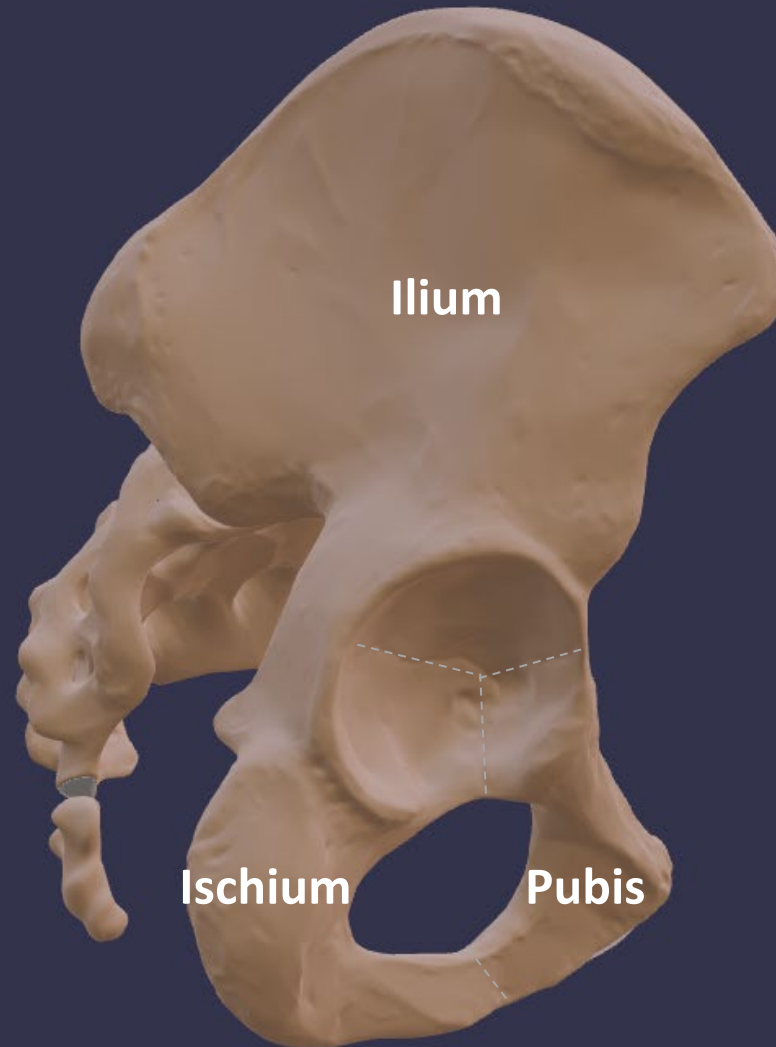
Bony parts

(medial view)



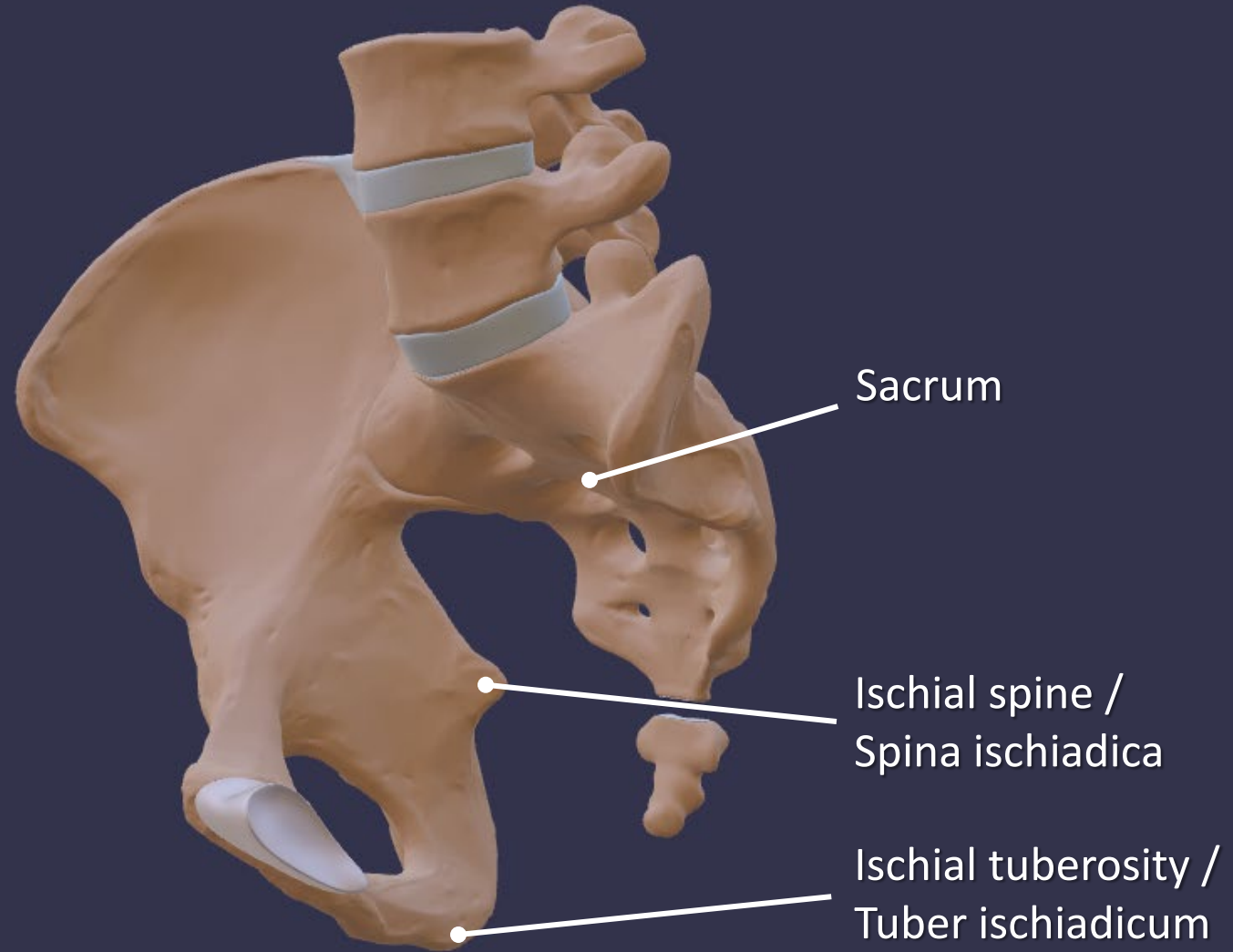
Bony parts

(lateral view)



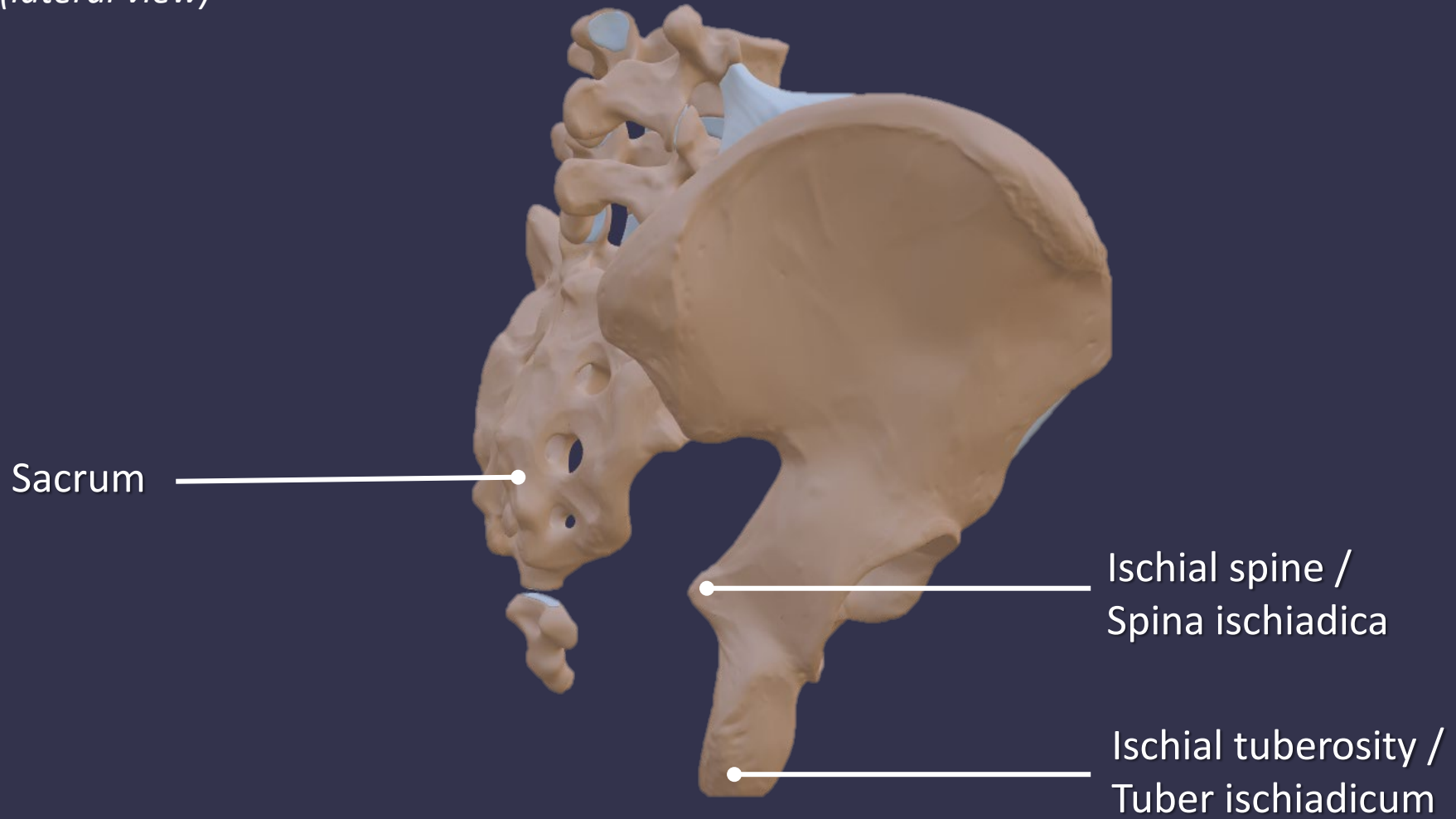
Bony parts

(medial view)



Bony parts

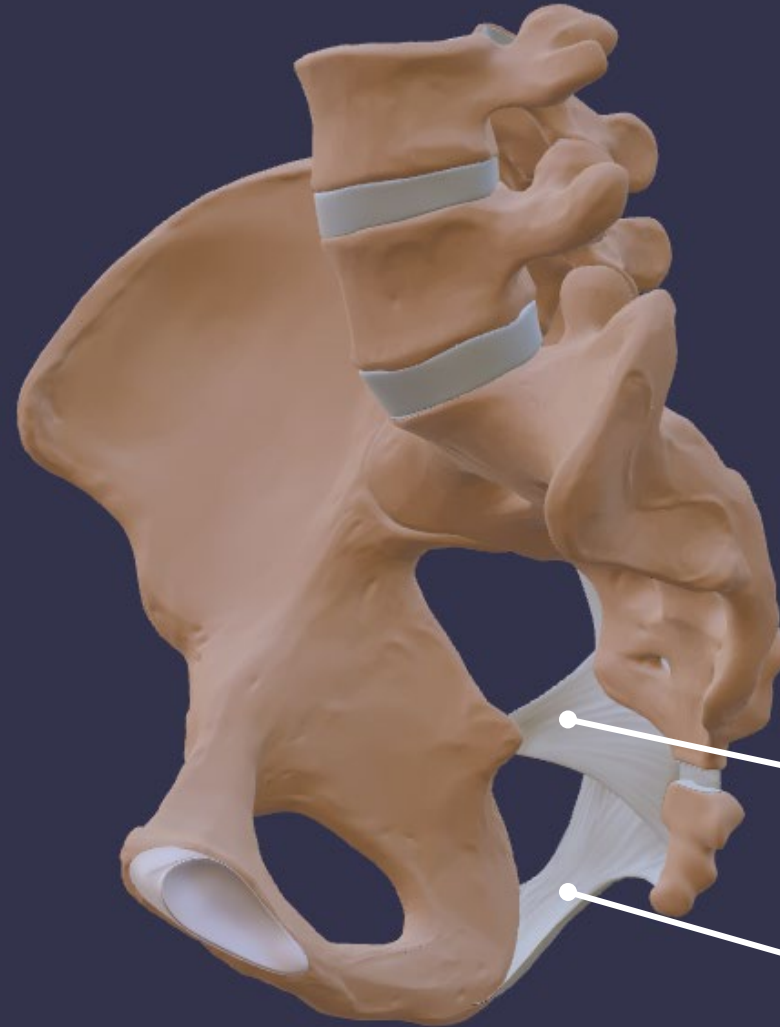(lateral view)



Ligaments

Ligaments

(medial view)



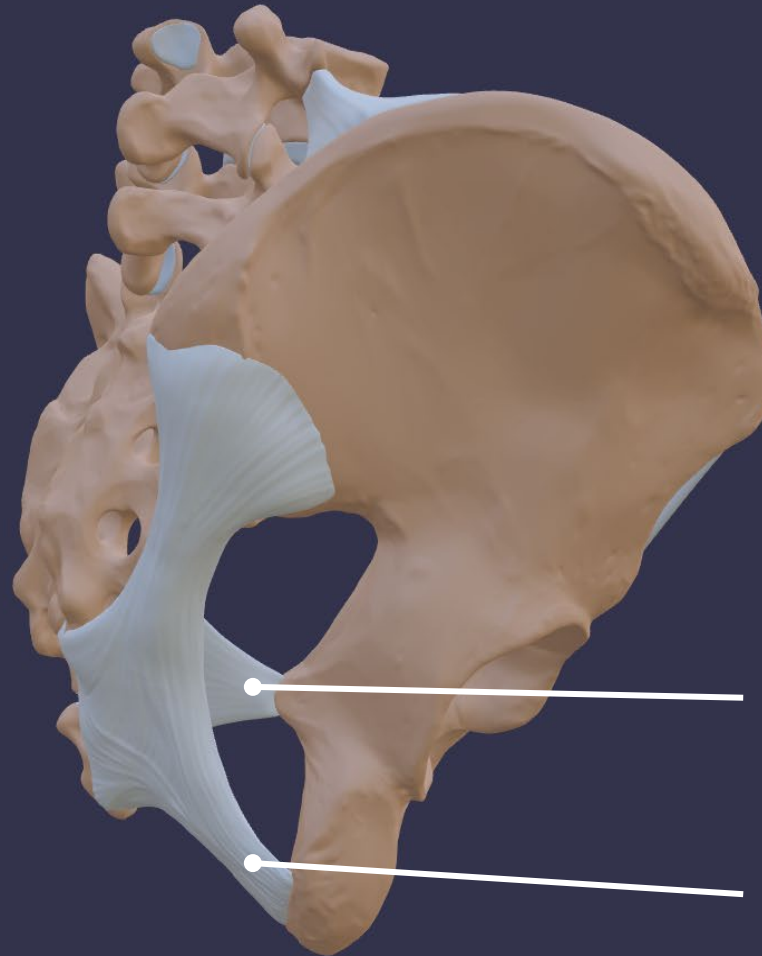
Sacrospinal ligament /
lig. sacrospinale
(sacrum - spina ischiadica)

Sacrotuberal ligament /
lig. sacrotuberale
(sacrum - tuber ischiadicum)



Ligaments

(lateral view)



Sacrospinal ligament /
lig. sacrospinale
(sacrum - spina ischiadica)

Sacrotuberous ligament /
lig. sacrotuberale
(sacrum - tuber ischiadicum)



Passways

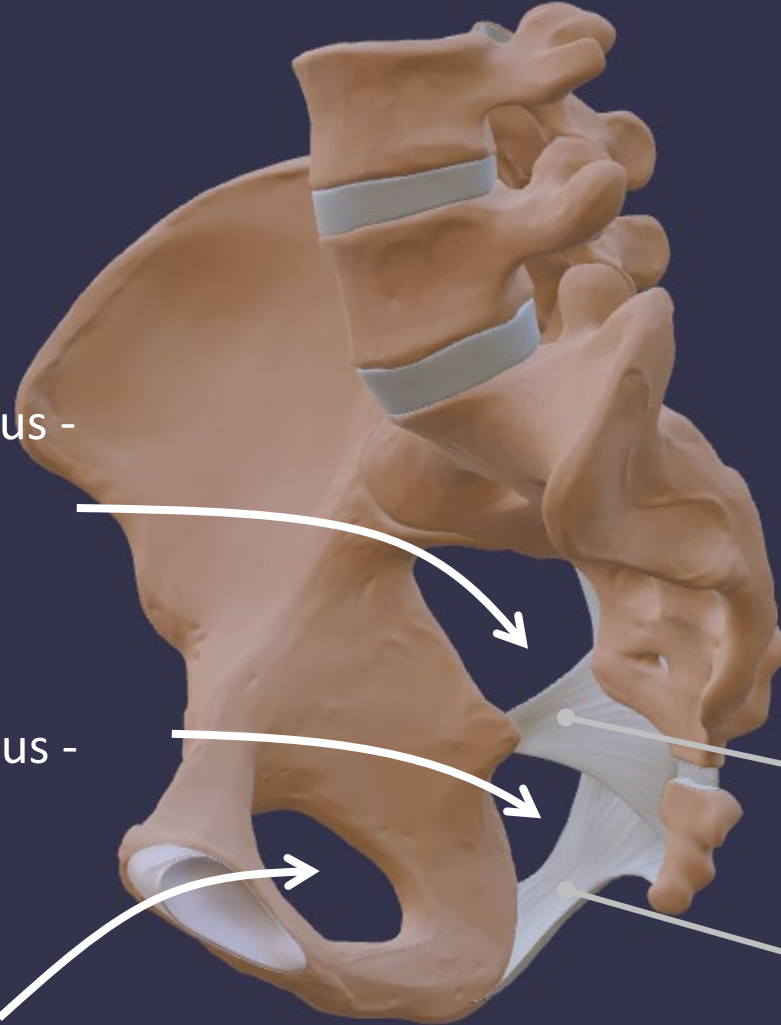
Passways

(medial view)

Greater sciatic foramen /
Foramen ischiadicum majus -
passway to the thigh

Lesser sciatic foramen /
Foramen ischiadicum minus -
passway to the perineum

Obturator foramen /
Foramen obturatum



Sacrospinal ligament /
lig. sacrospinale
(sacrum - spina ischiadica)

Sacrotuberal ligament /
lig. sacrotuberale
(sacrum - tuber ischiadicum)

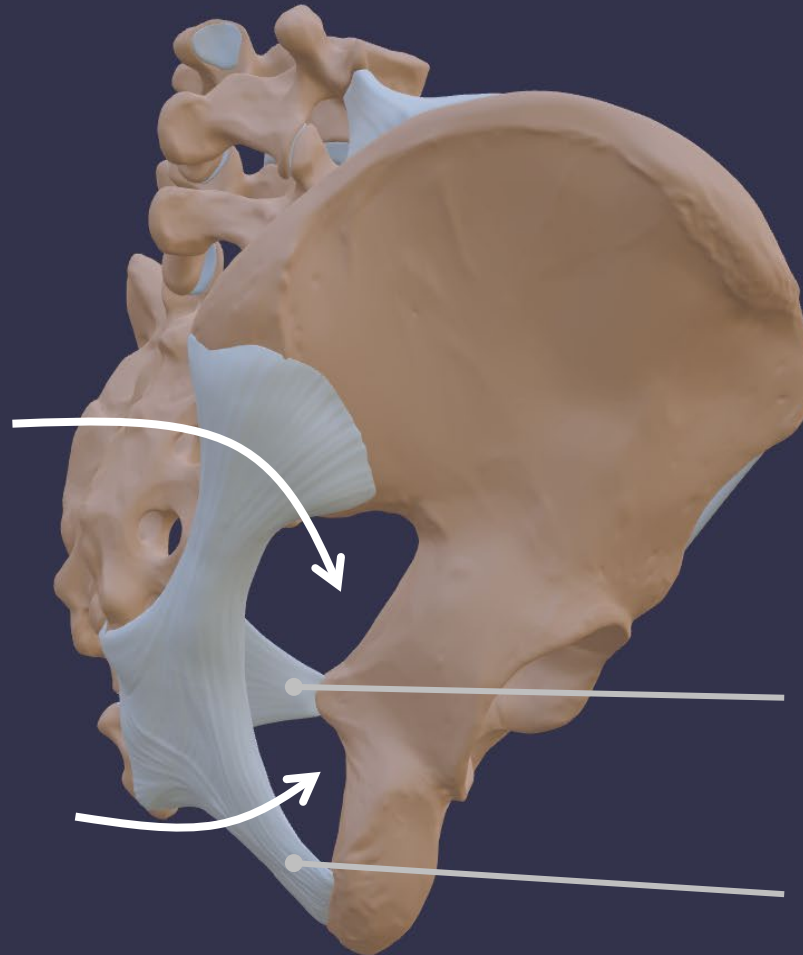


Passways

(lateral view)

Greater sciatic foramen /
Foramen ischiadicum majus -
passway to the thigh

Lesser sciatic foramen /
Foramen ischiadicum minus -
passway to the perineum



Sacrospinal ligament /
lig. sacrospinale
(sacrum - spina ischiadica)

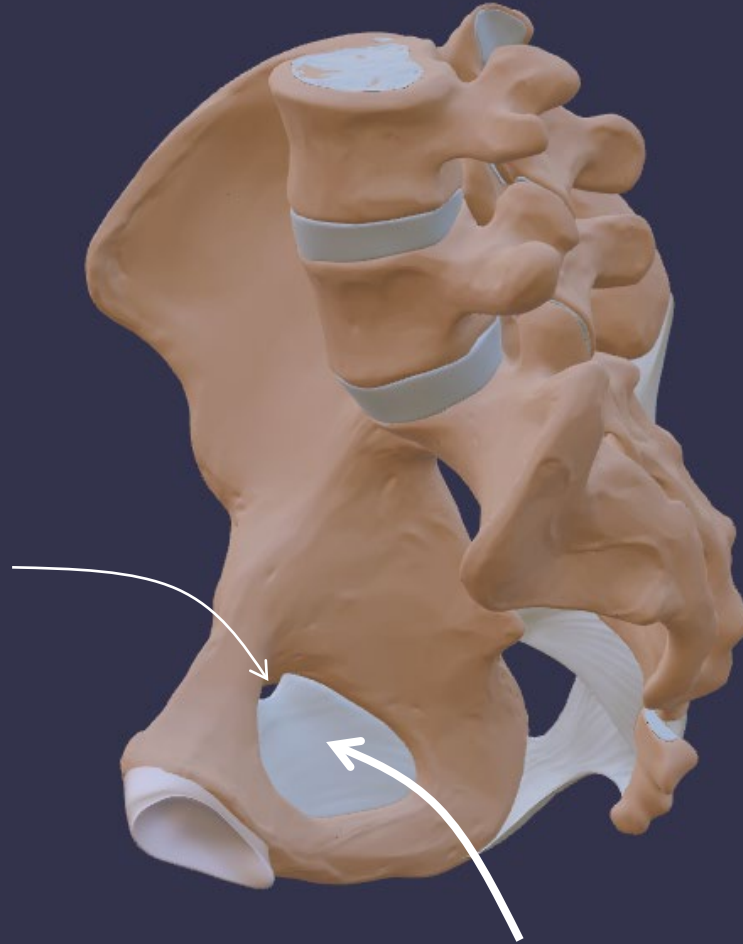
Sacrotuberous ligament /
lig. sacrotuberale
(sacrum - tuber ischiadicum)



Passways

(medial view)

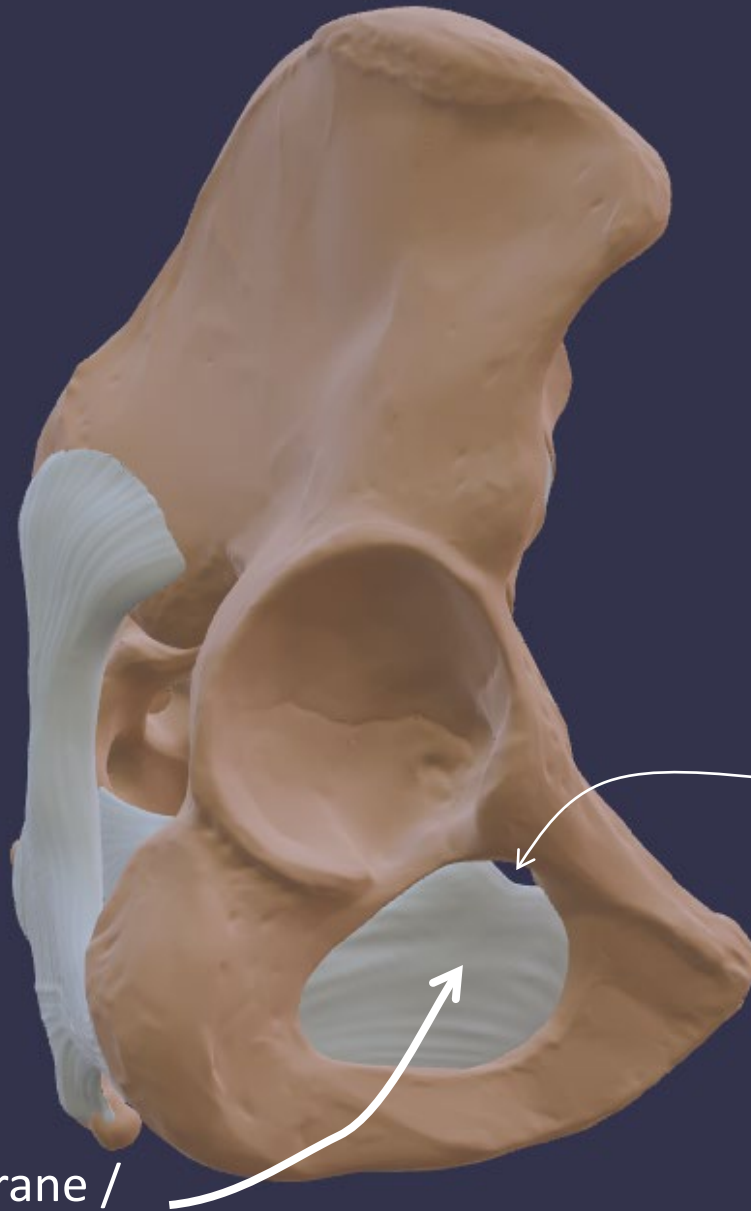
Obturator canal /
Canalis obturatorius



Obturator membrane /
Membrana obturatoria



Passways
(lateral view)



Obturator canal /
Canalis obturatorius

Obturator membrane /
Membrana obturatoria

