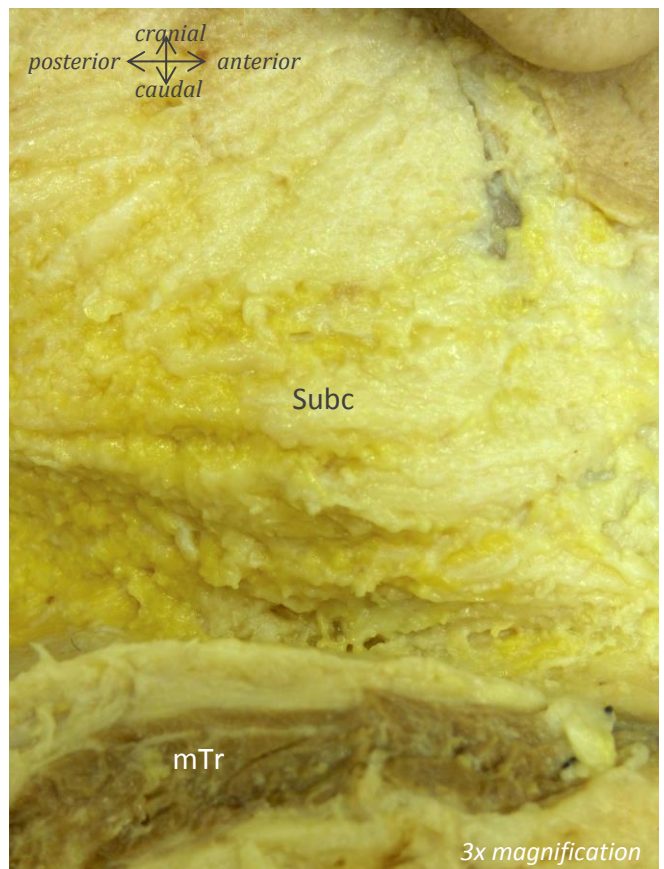
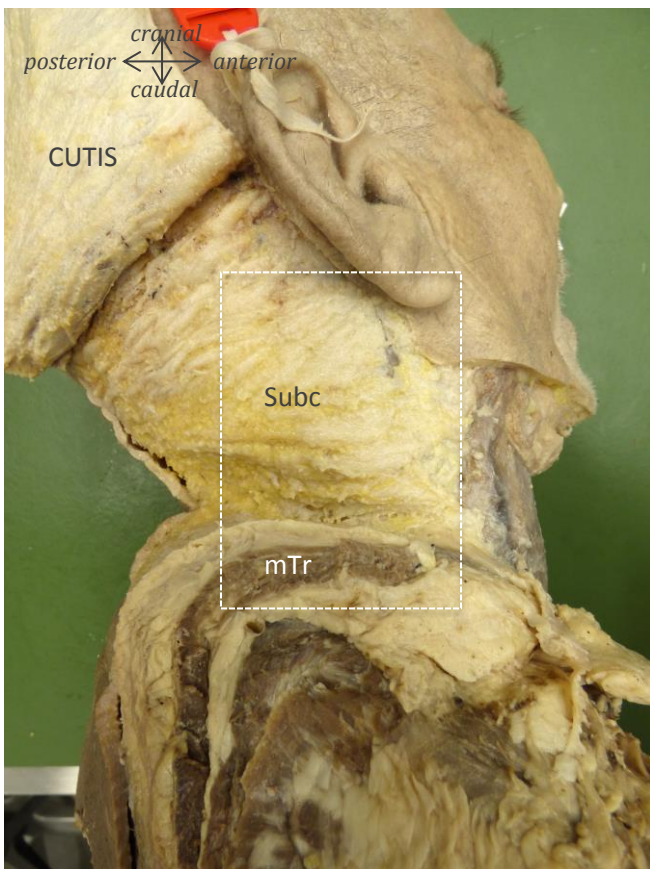
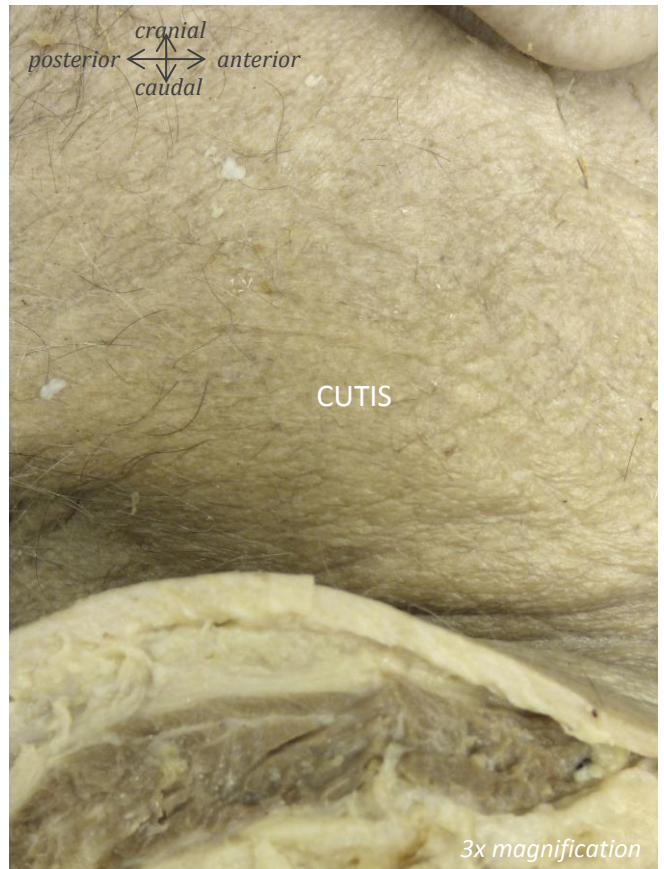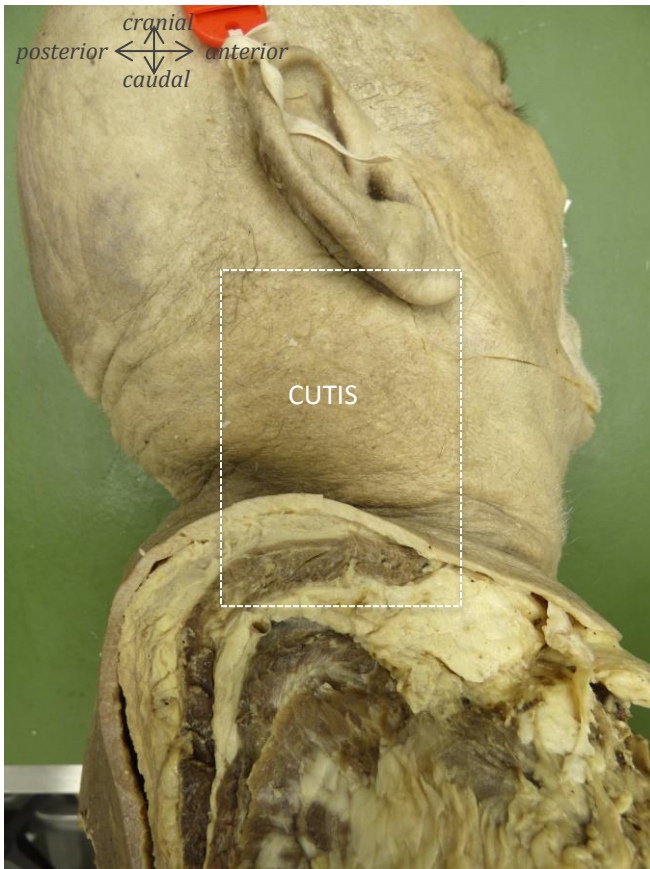


A dorsolateral dissection of the cervical neck

*dissection from skin to facet joints of the
cervical region, documented stepwise by high
resolution pictures with all relevant structures
labeled*

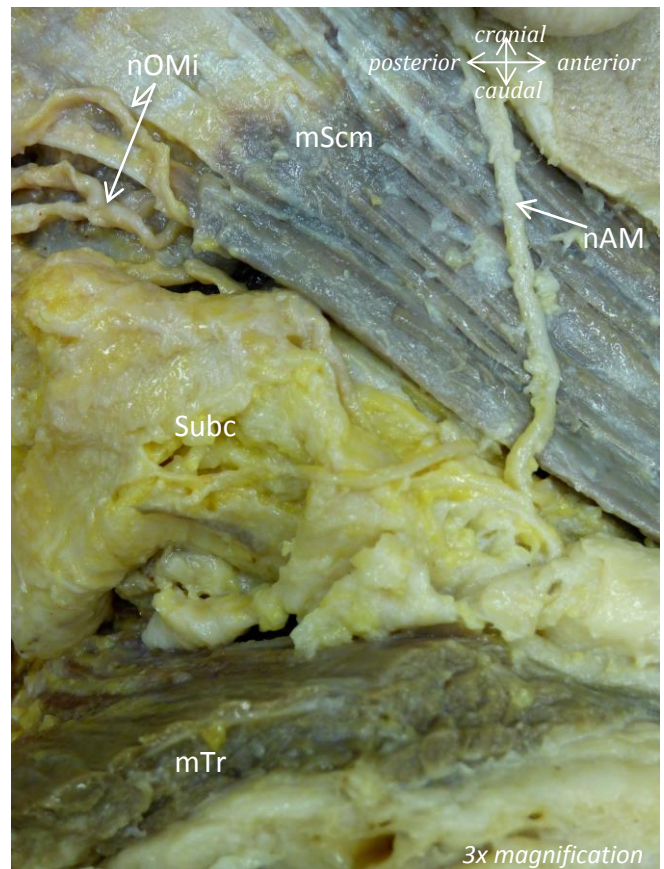
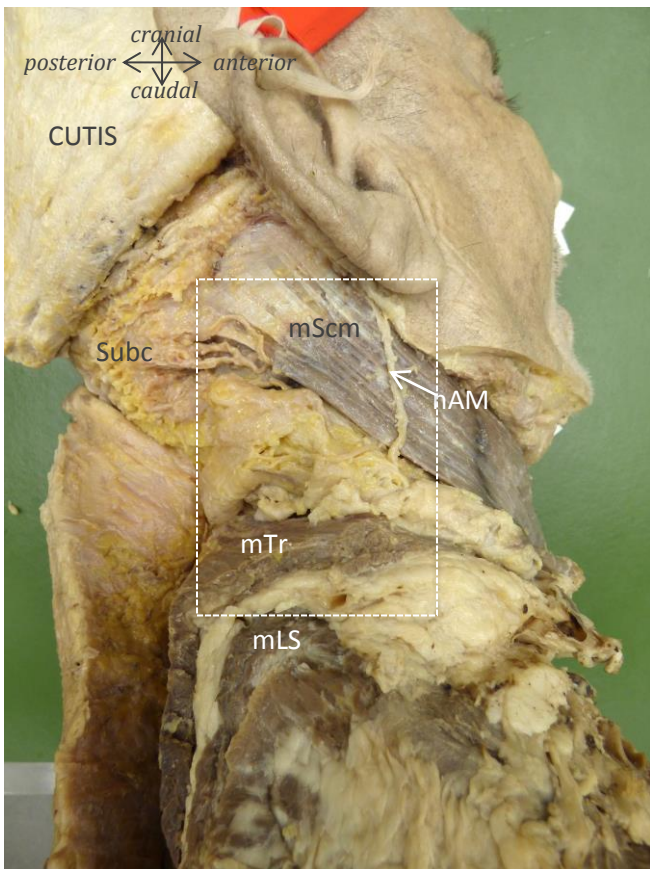
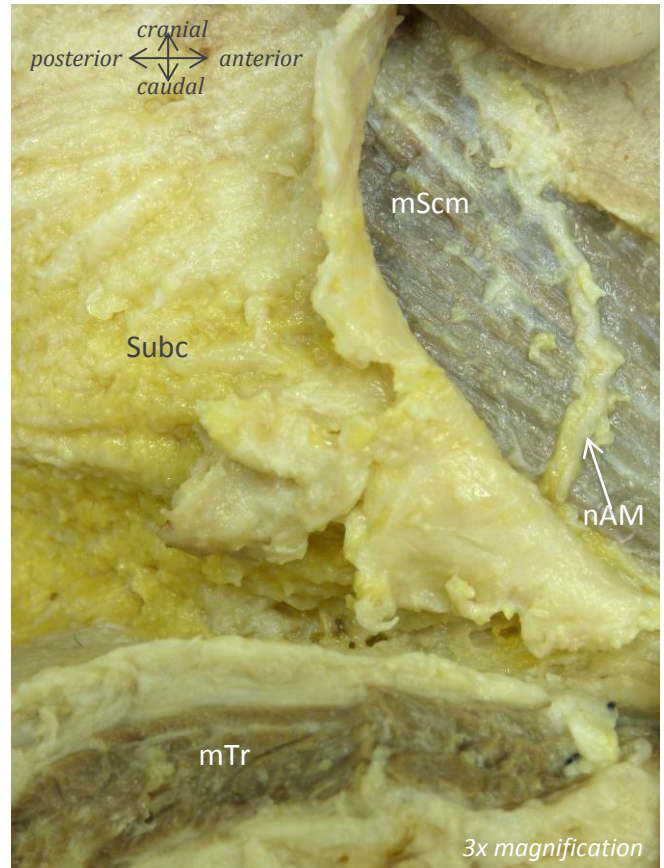
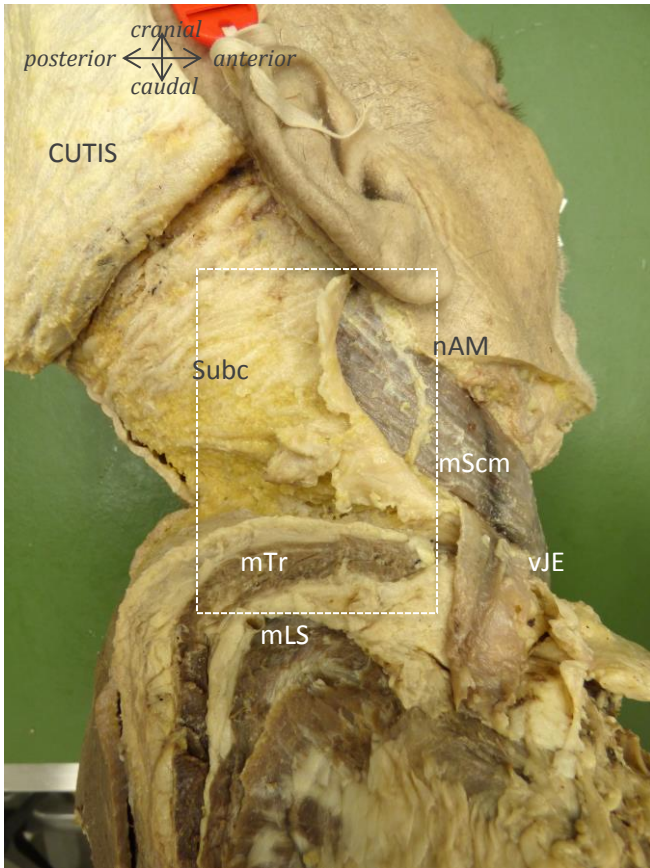
*Fabian Büsken, Noëlle Dirks, Andreas Herrler, Arno
Lataster
Department of Anatomy & Embryology
FHML, Maastricht University
The Netherlands*



Muscles: mTr = m. trapezius

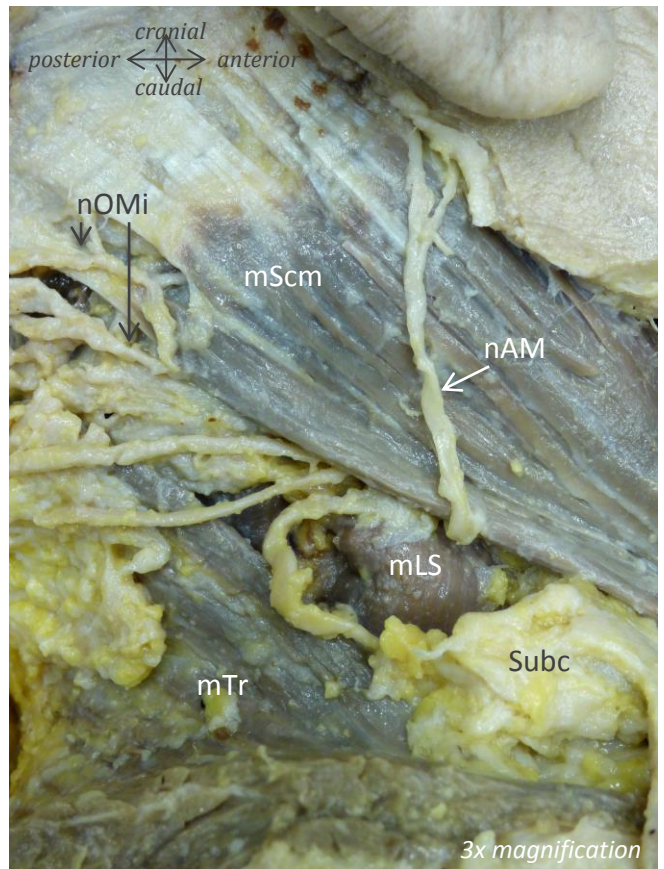
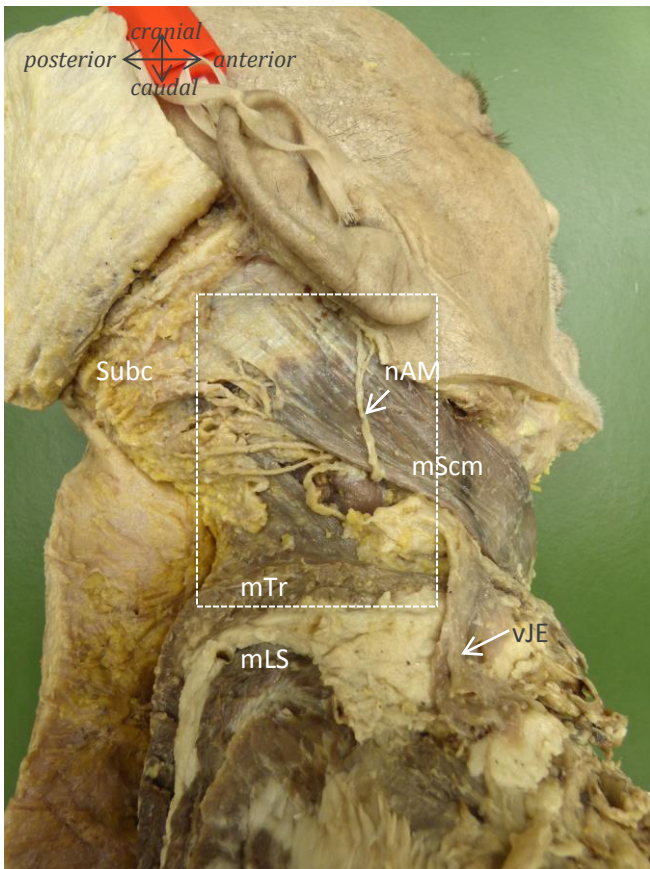
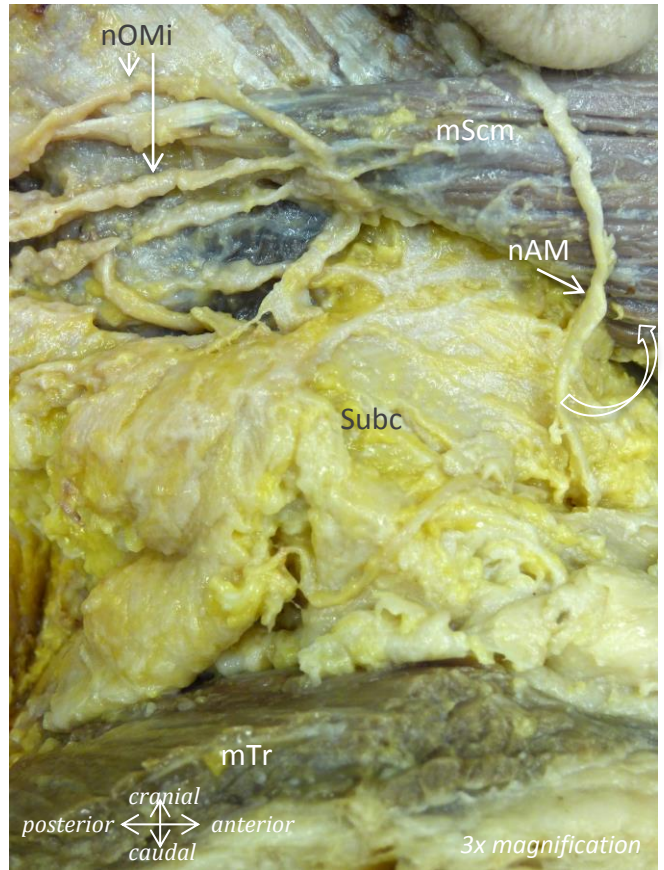
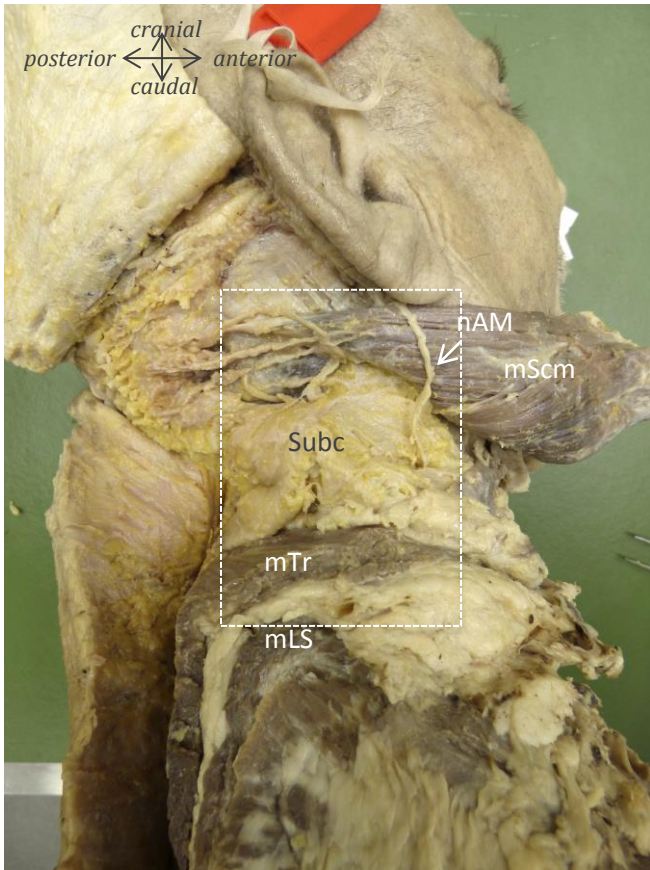
Extra: Subc = subcutis

Male, 67 years of age



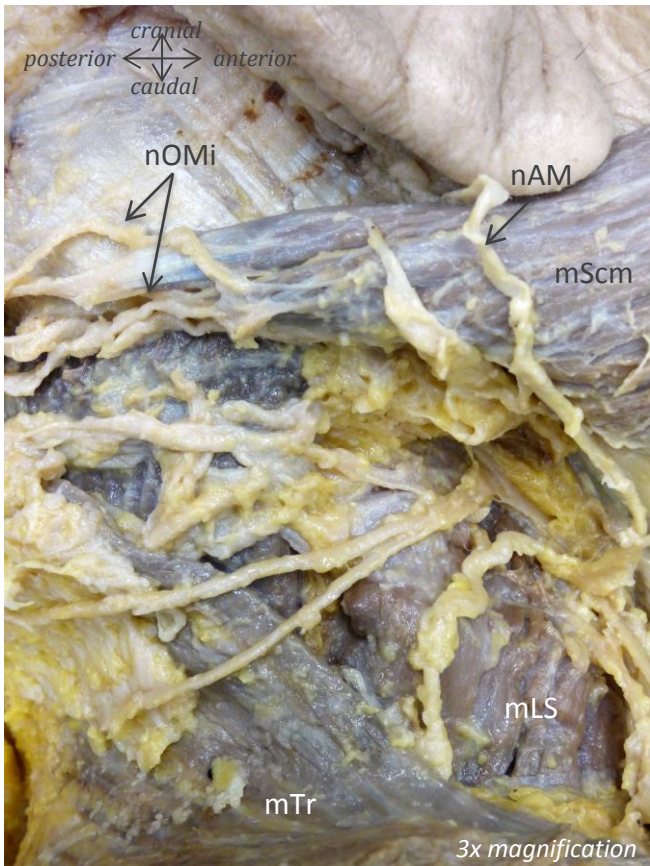
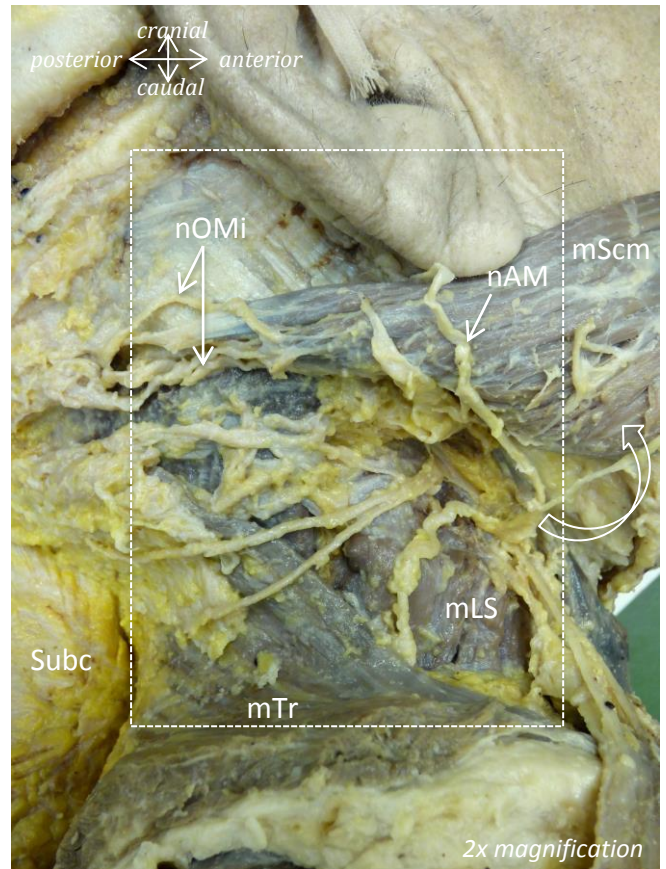
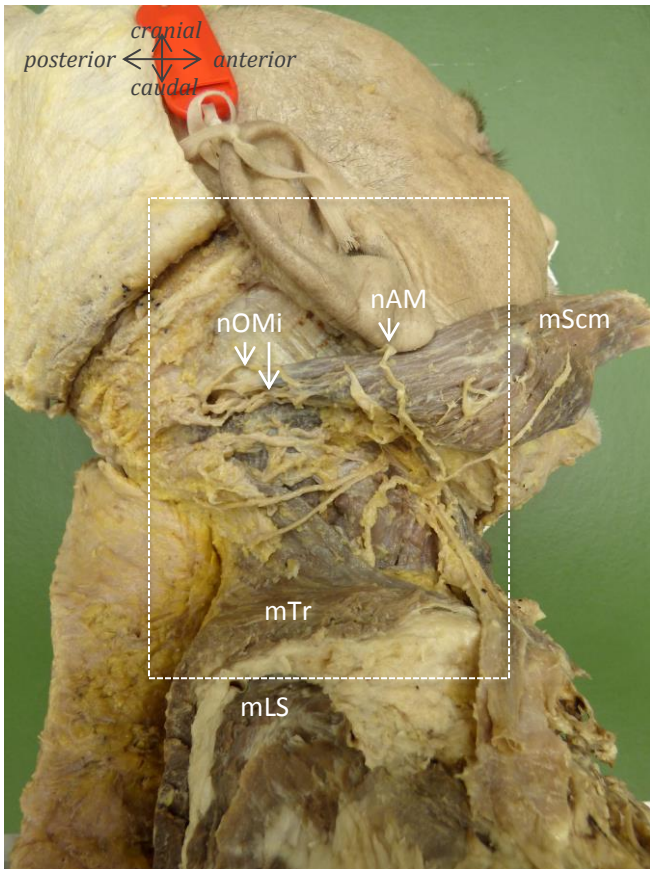
Muscles: mScm = m. sternocleidomastoideus; mTr = m. trapezius; mLS = m. levator scapulae
Nerves: nAM = n. auricularis magnus; nOMi = n. occipitalis minor
Vessels: vJE = v. jugularis externa
Extra: Subc = subcutis

Male, 67 years of age



Muscles: Scm = m. sternocleidomastoideus; Tr = m. trapezius; LS = levator scapulae
Nerves: AM = n. auricularis magnus; OMi = n. occipitalis minor
Vessels: vJE = v. jugularis externa
Extra: Subc = subcutis

Male, 67 years of age



Muscles

mScm = m. sternocleidomastoideus

mLS = m. levator scapulae

mTr = m. trapezius

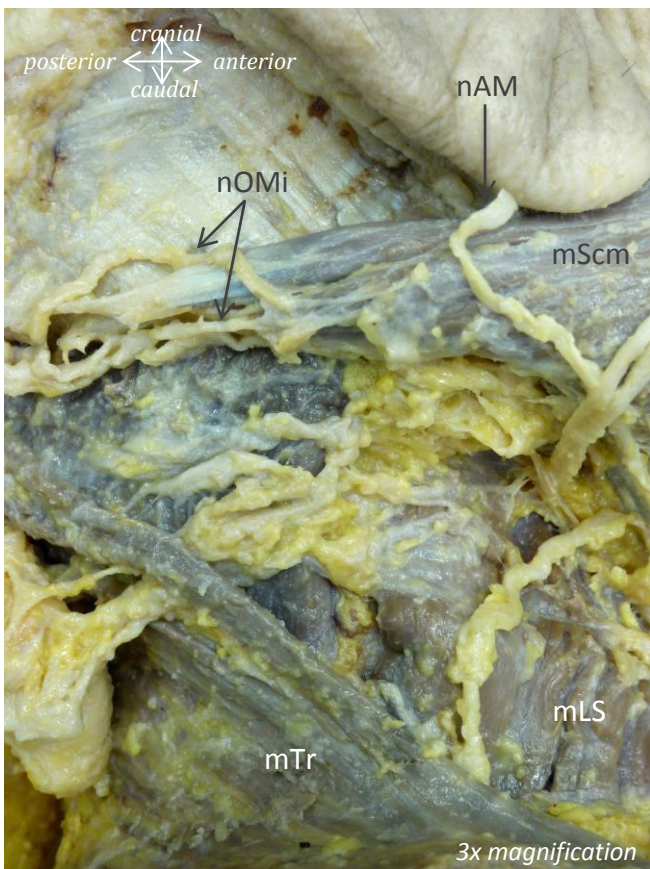
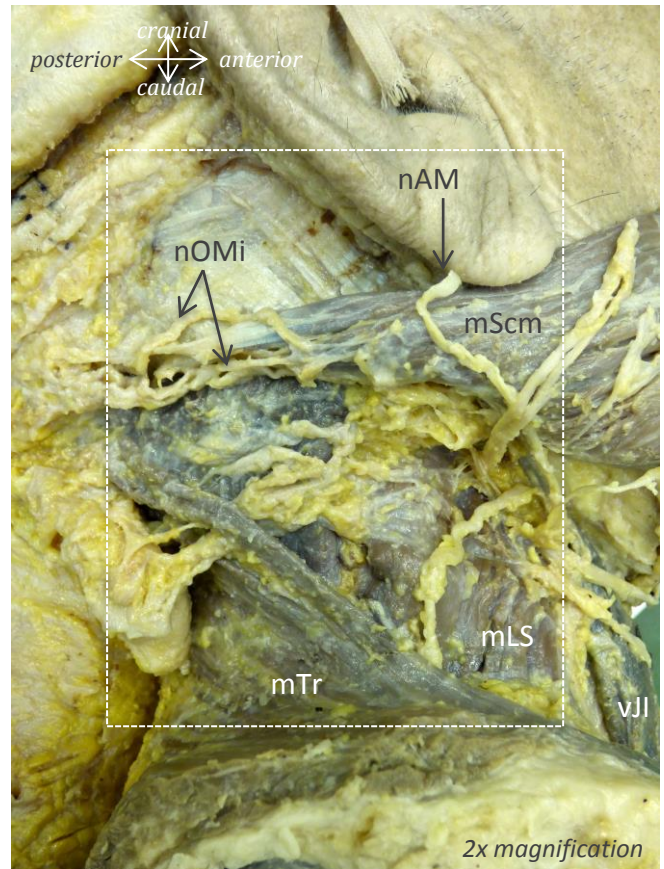
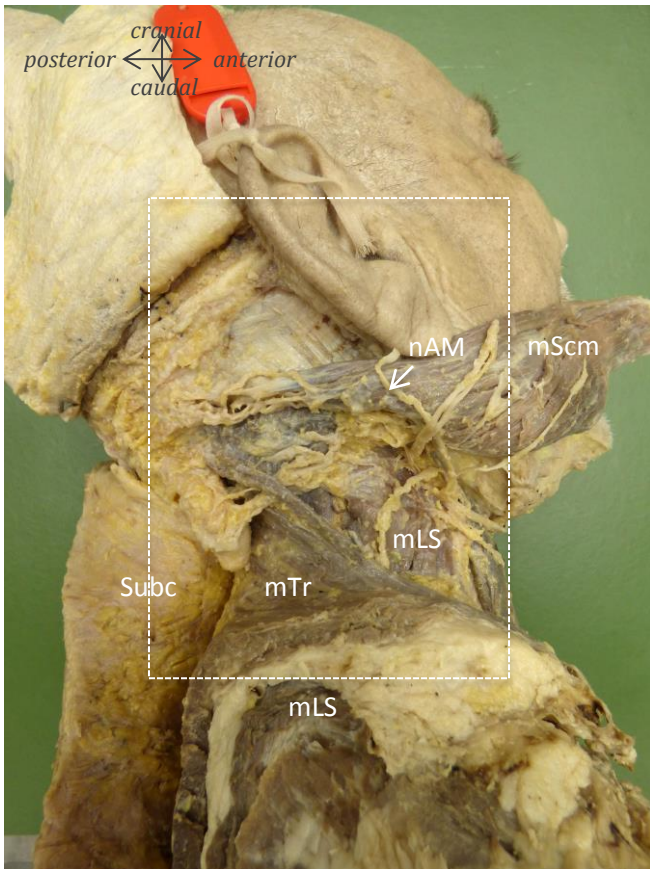
Nerves

nAM = n. auricularis magnus

nOMi = n. occipitalis minor

Extra

Subc = subcutis



Muscles

mScm = m. sternocleidomastoideus

mLS = m. levator scapulae

mTr = m. trapezius

Nerves

nAM = n. auricularis magnus

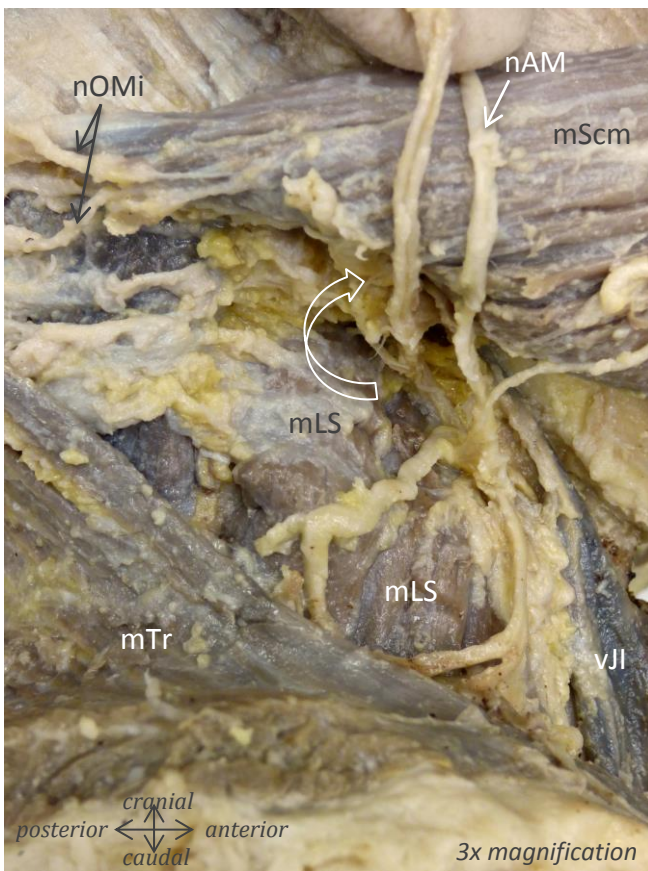
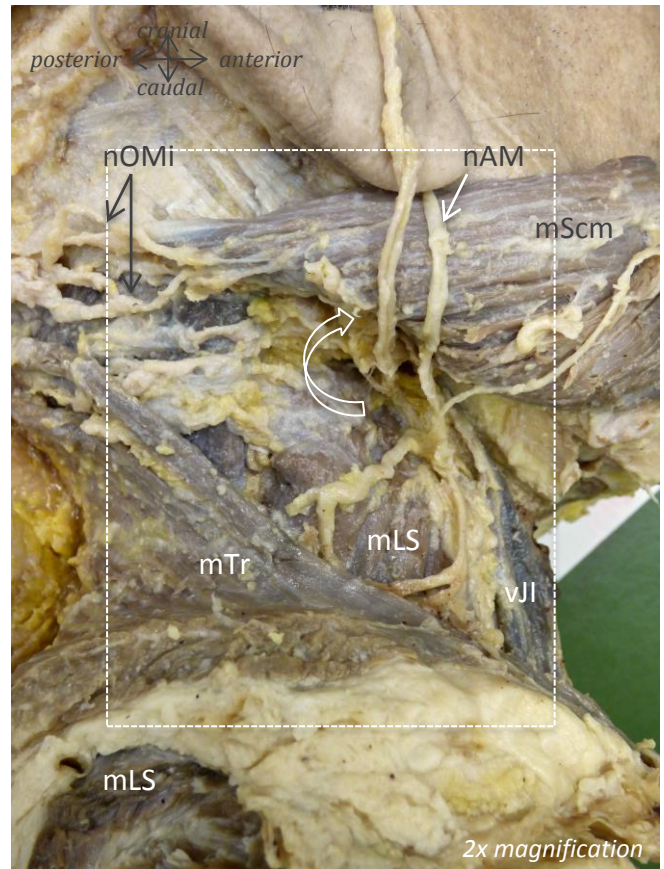
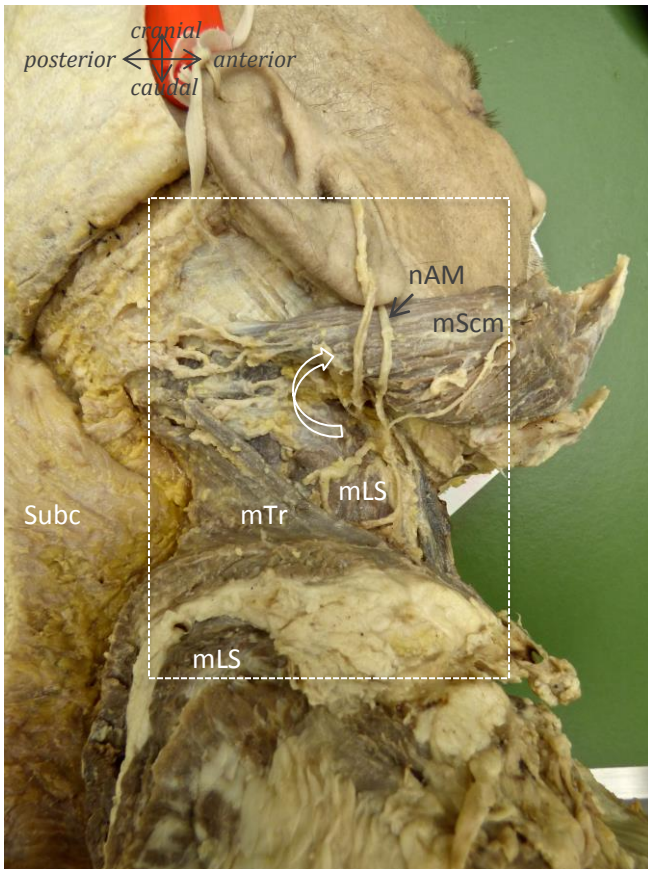
nOMi = n. occipitalis minor

Vessels

vJl = v. jugularis interna

Extra

Subc = subcutis



Muscles

mScm = m. sternocleidomastoideus

mLS = m. levator scapulae

mTr = m. trapezius

Nerves

nAM = n. auricularis magnus

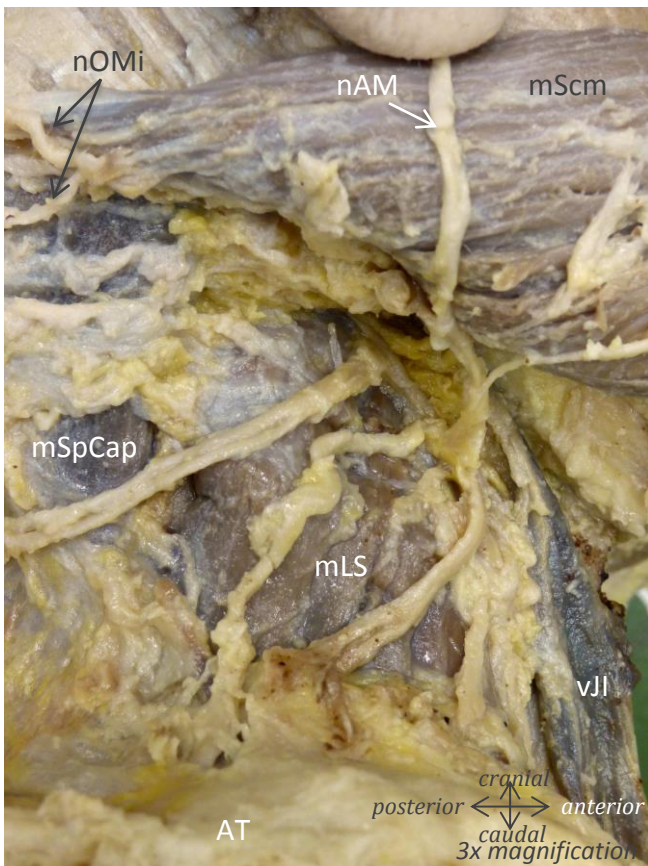
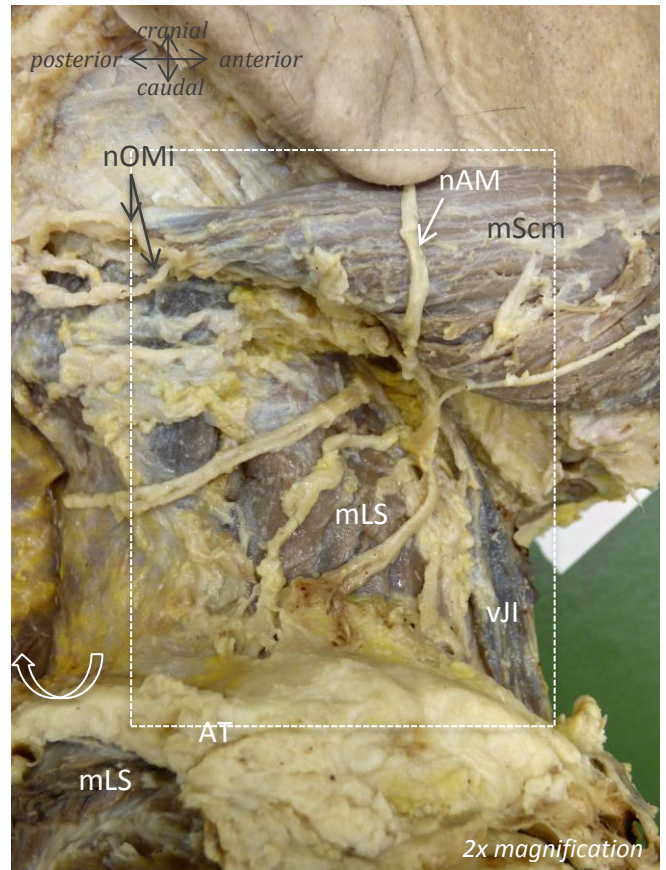

nOMi = n. occipitalis minor

Vessels

vJI = v. jugularis interna

Extra

Subc = subcutis



Muscles

- mScm = m. sternocleidomastoideus
- mLS = m. levator scapulae
- mTr = m. trapezius
- mSpCap = m. spinalis capitis
- mRMa = m. rhomboideus major

Nerves

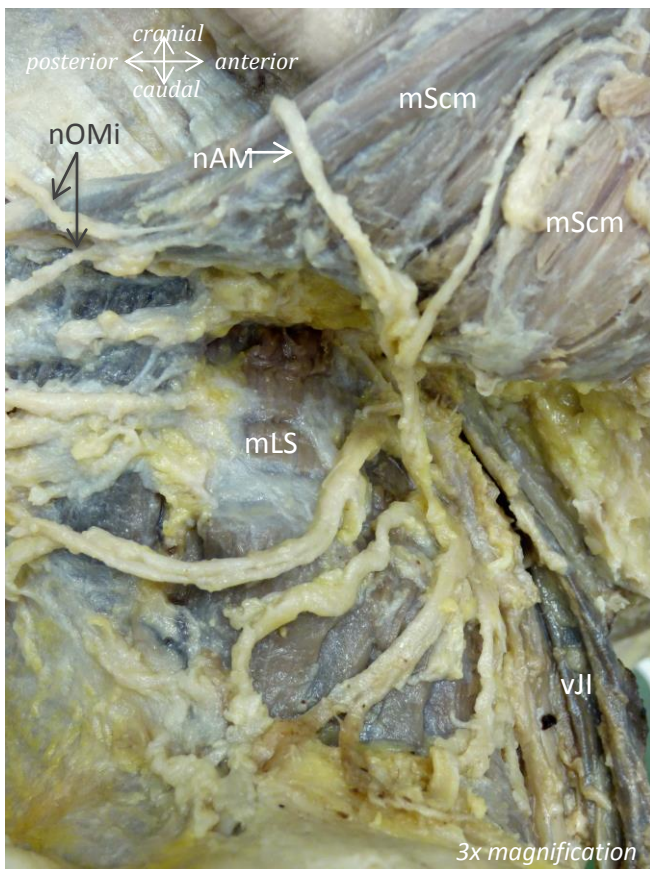
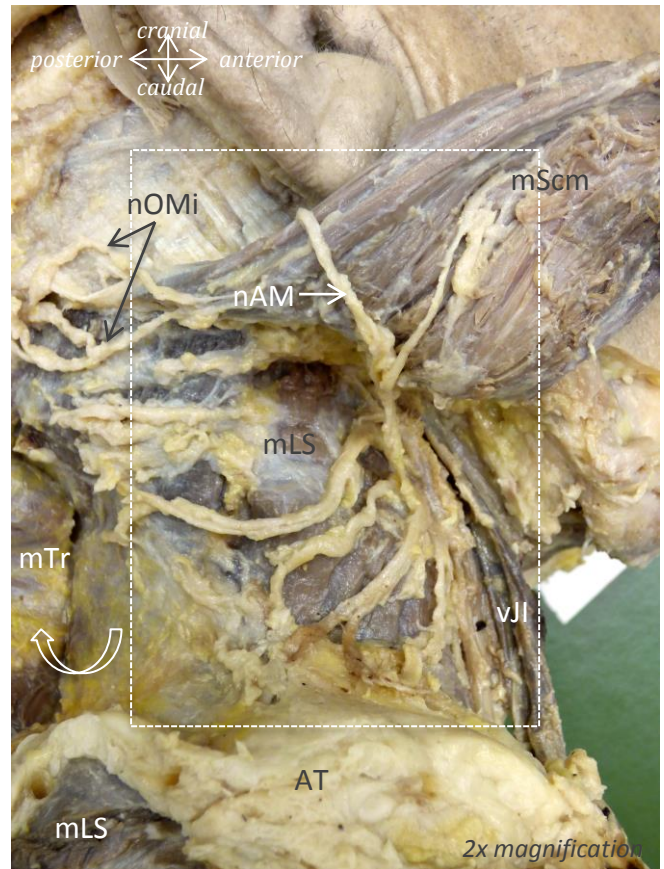
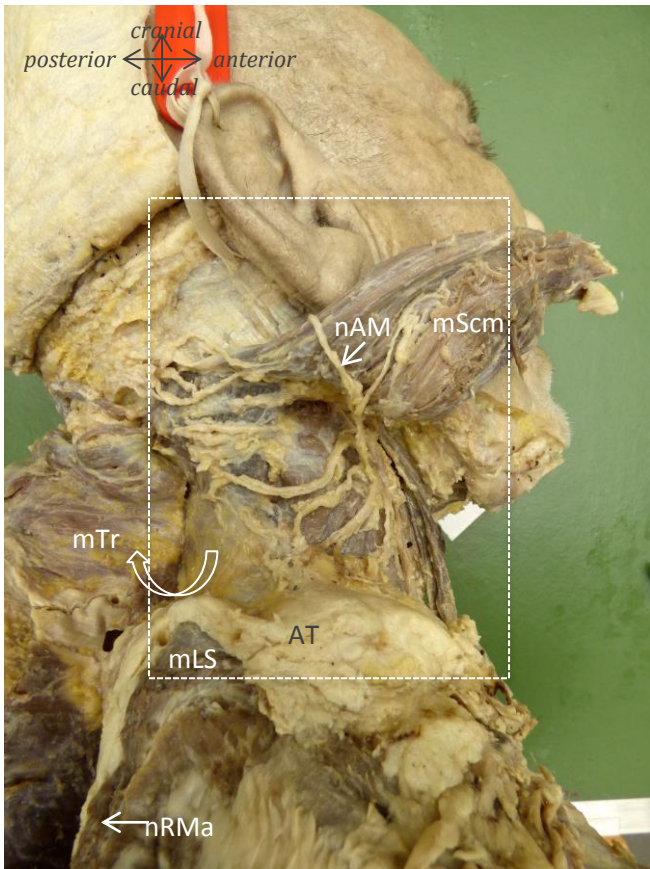
- nAM = n. auricularis magnus
- nOMi = n. occipitalis minor

Vessels

- vJI = v. jugularis interna

Extra

- Subc = subcutis
- AT = adipose tissue



Muscles

mScm = m. sternocleidomastoideus

mLS = m. levator scapulae

mTr = m. trapezius

mSpCap = m. spinalis capitis

mRMa = m. rhomboideus major

Nerves

nAM = n. auricularis magnus

nOMi = n. occipitalis minor

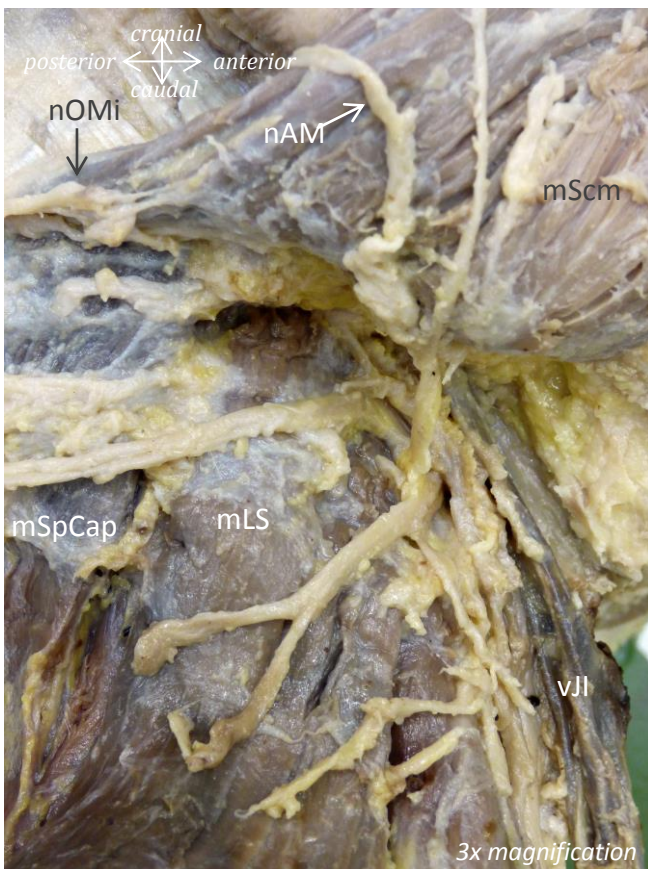
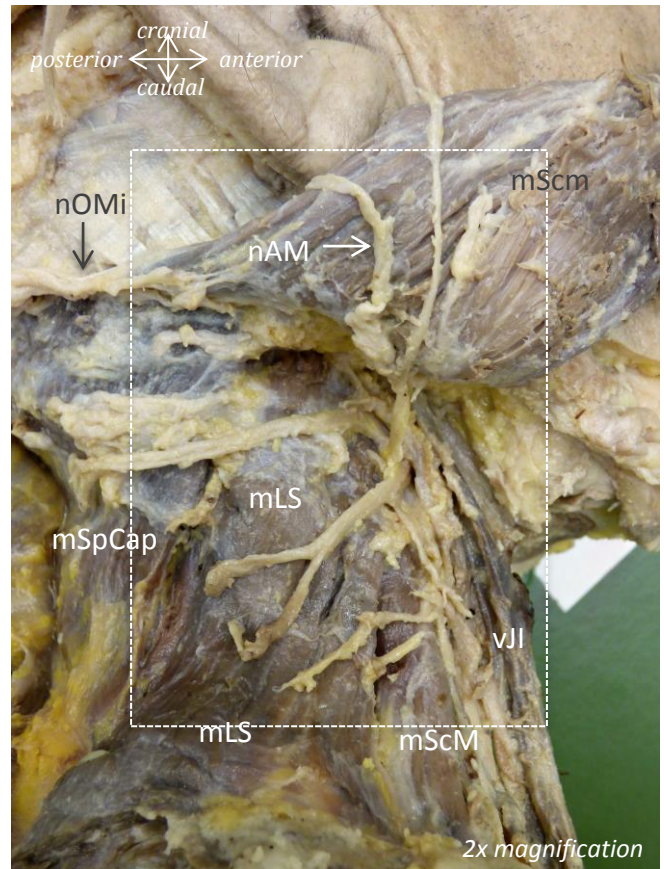

Vessels

vJI = v. jugularis interna

Extra

Subc = subcutis

AT = adipose tissue



Muscles

mScm = m. sternocleidomastoideus

mLS = m. levator scapulae

mTr = m. trapezius

mSpCap = m. spinalis capitis

mRMa = m. rhomboideus major

Nerves

nAM = n. auricularis magnus

nOMi = n. occipitalis minor

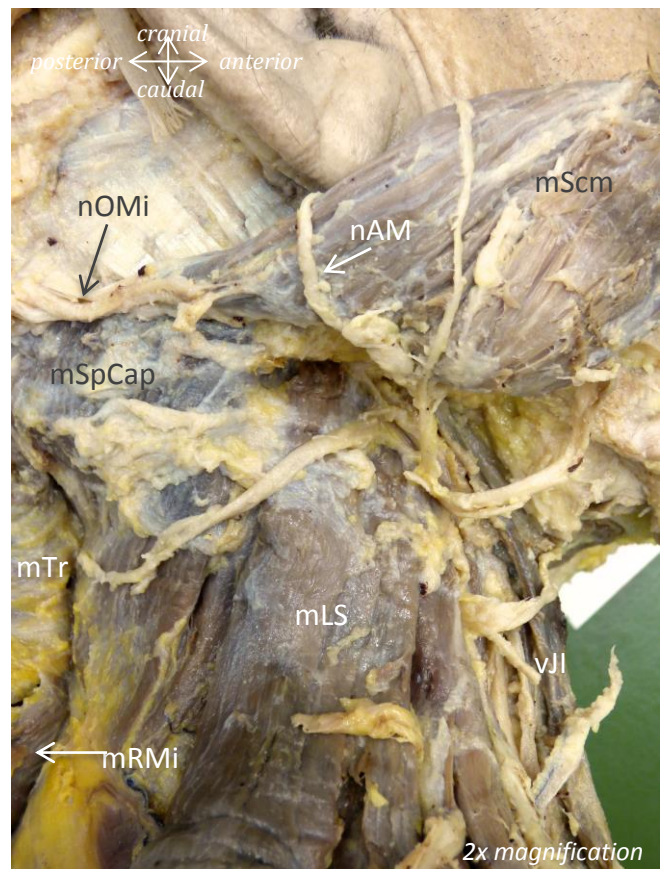
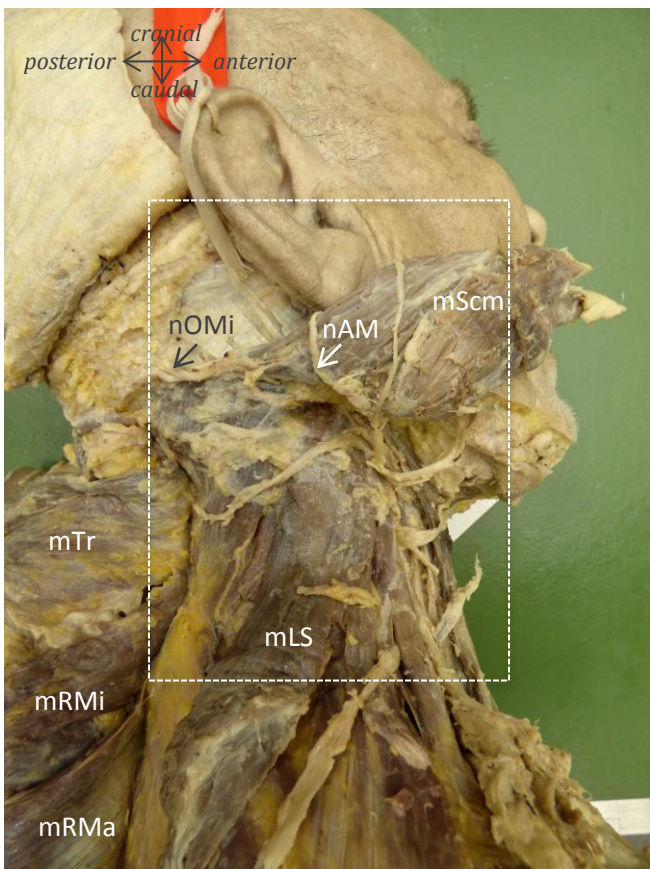
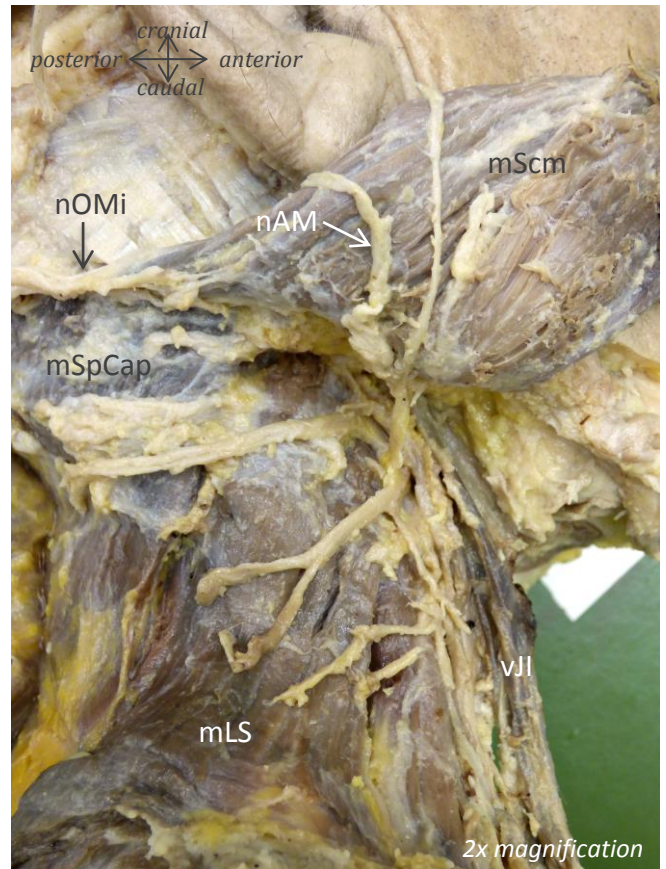
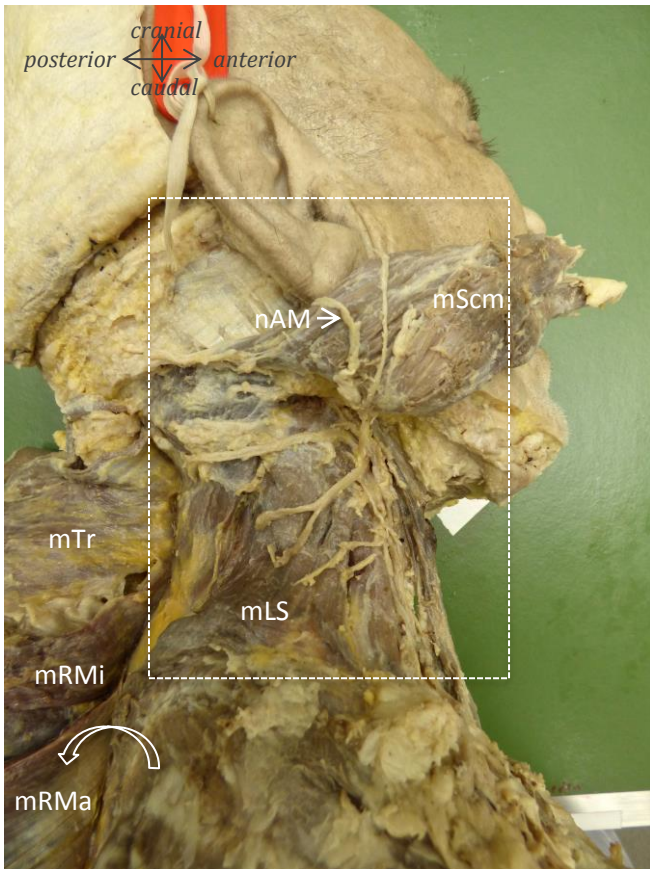
Vessels

vJI = v. jugularis interna

Extra

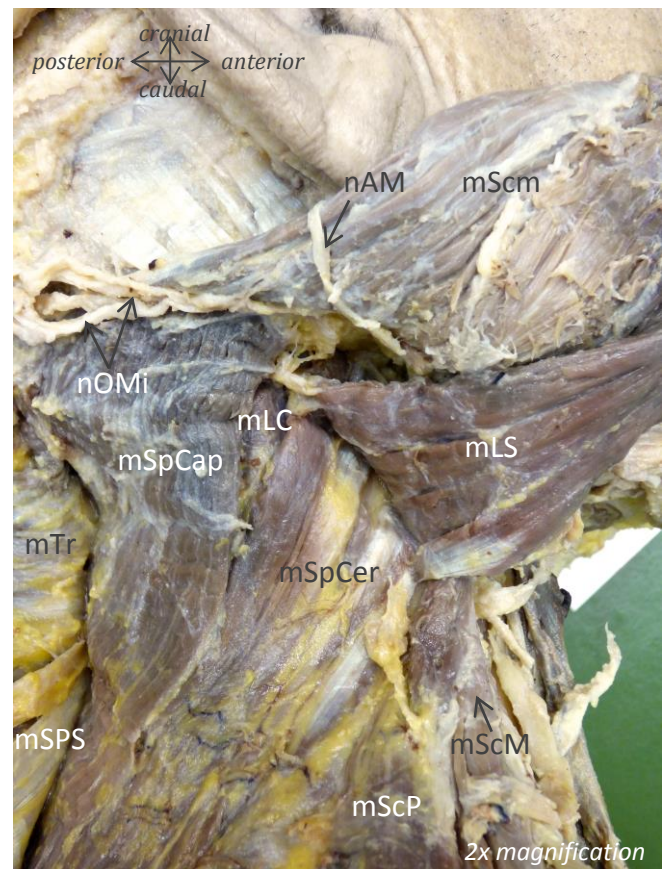
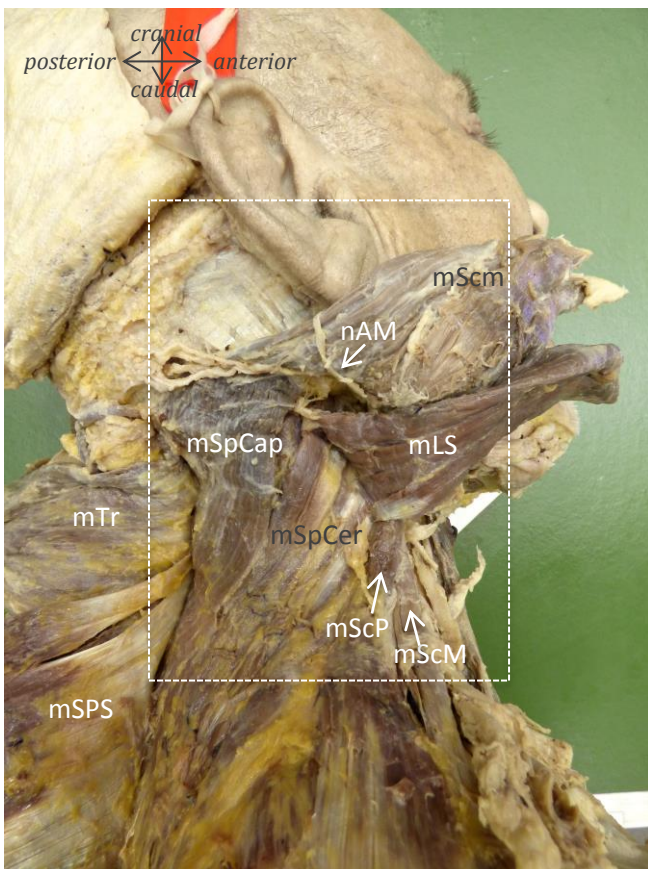
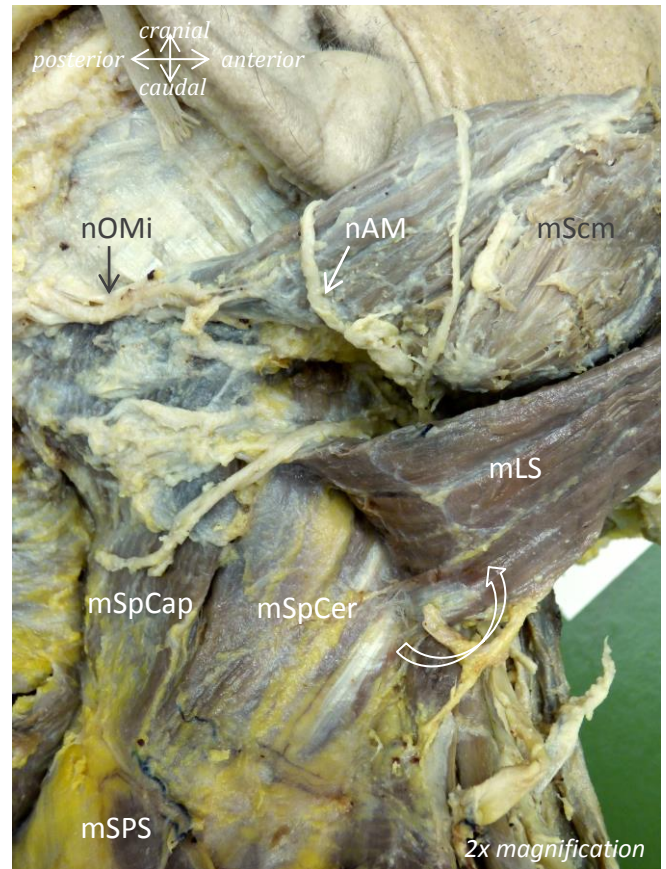
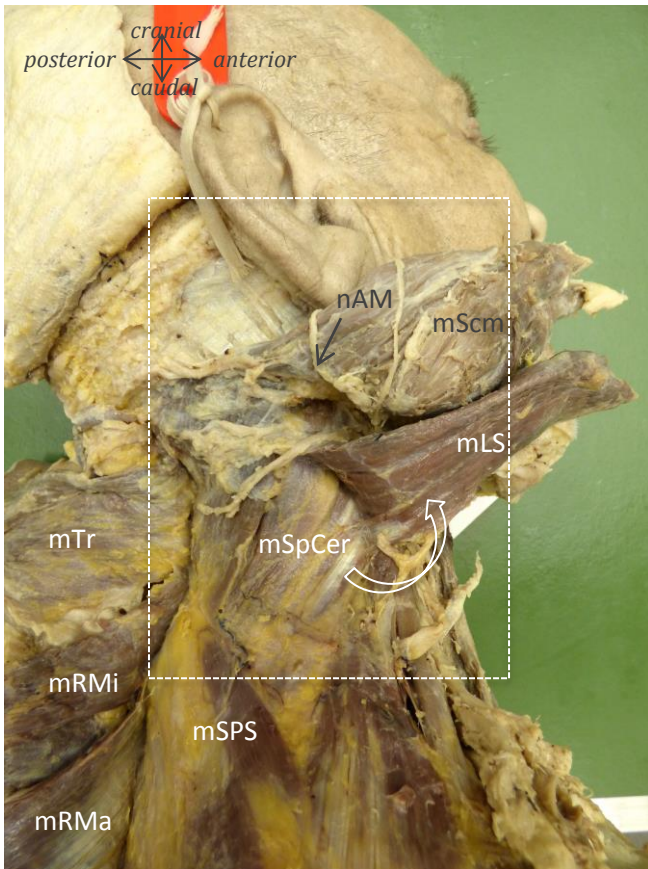
Subc = subcutis

AT = adipose tissue



Muscles: mScm = m. sternocleidomastoideus; mLS = m. levator scapulae; mSpCap = m. splenius capitis; mTr = m. trapezius; mRMi = m. rhomboideus minor; mRMa = m. rhomboideus major
Nerves: nAM = n. auricularis magnus; nOMi = n. occipitalis minor
Vessels: vJI = v. jugularis interna

Male, 67 years of age

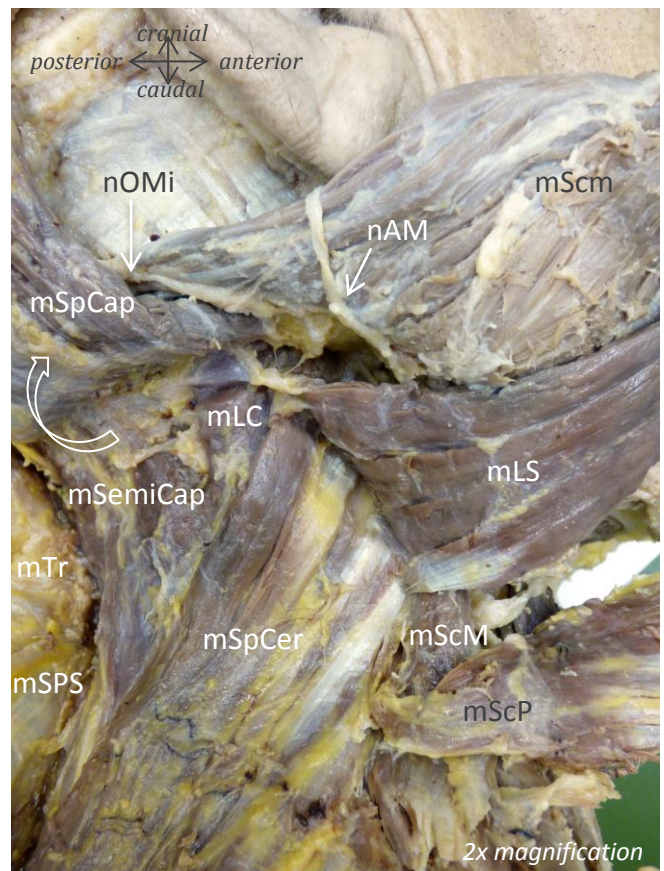

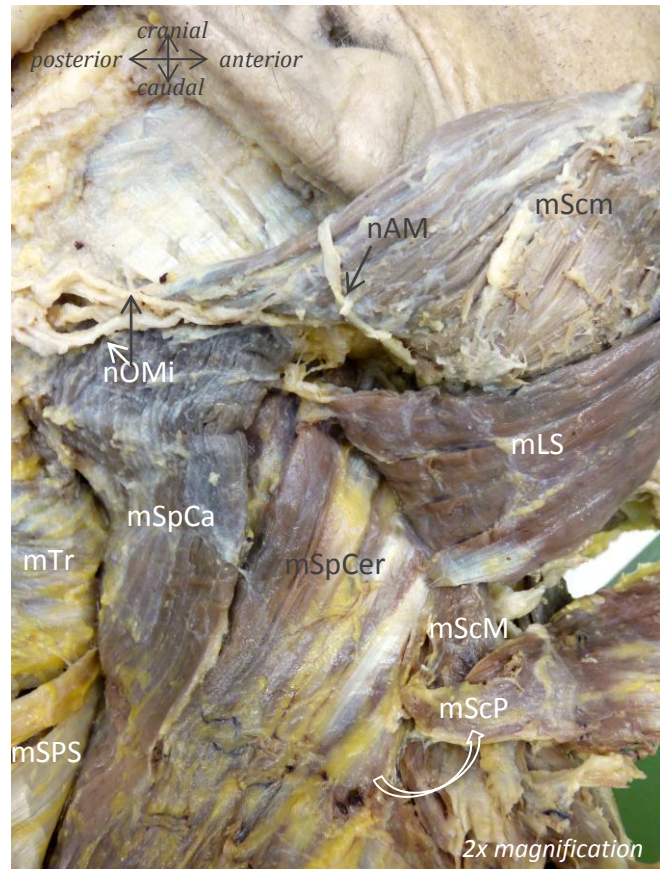
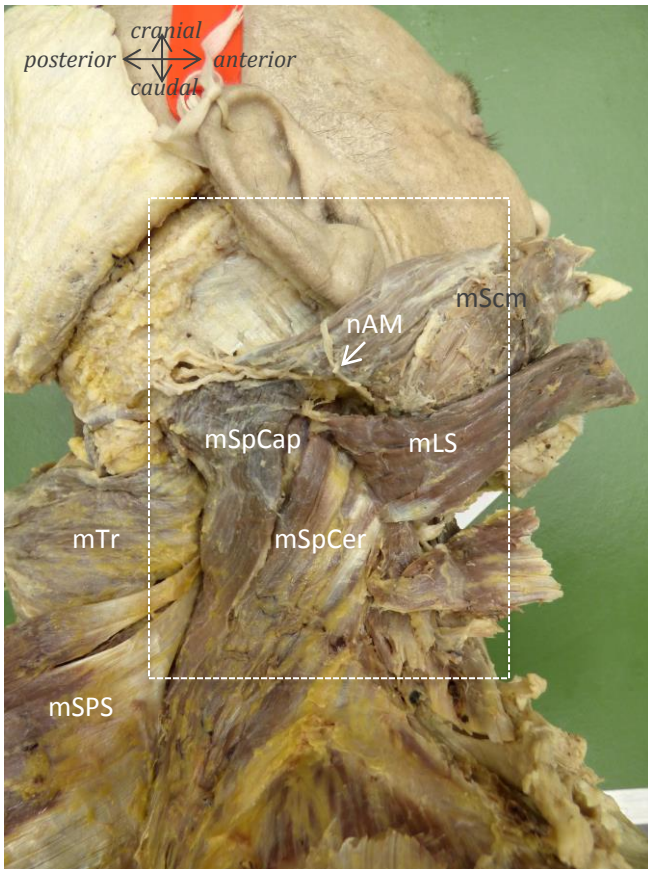


Muscles: mScm = m. sternocleidomastoideus; mLS = m. levator scapulae; mLC = m. longissimus capitis; mSpCap = m. splenius capitis; mSpCer = m. splenius cervicis; mTr = m. trapezius; mSPS = m. serratus posterior superior; mScP = m. scalenus posterior; mScM = m. scalenus medius

Nerves: nAM = n. auricularis magnus; nOMi = n. occipitalis minor

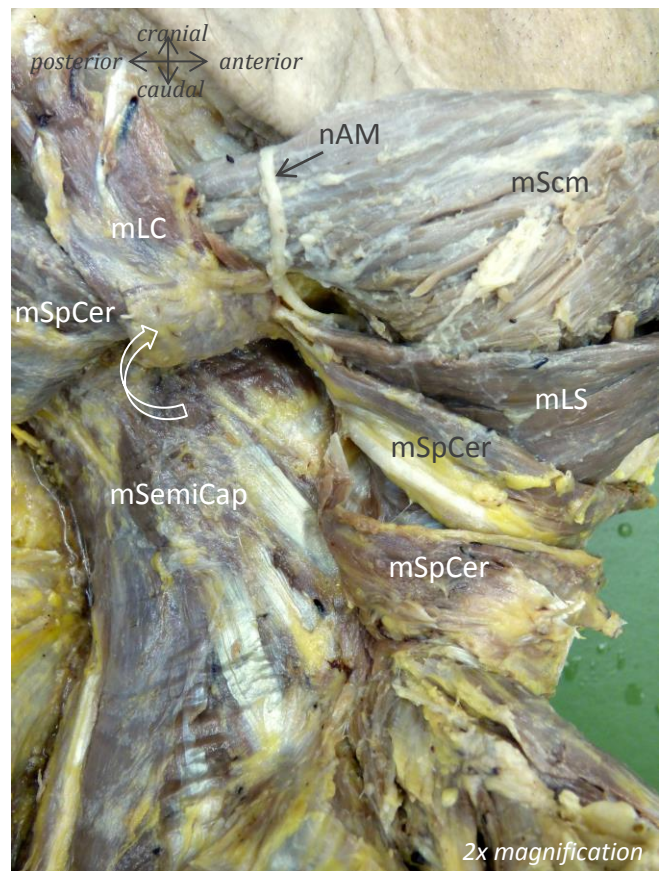
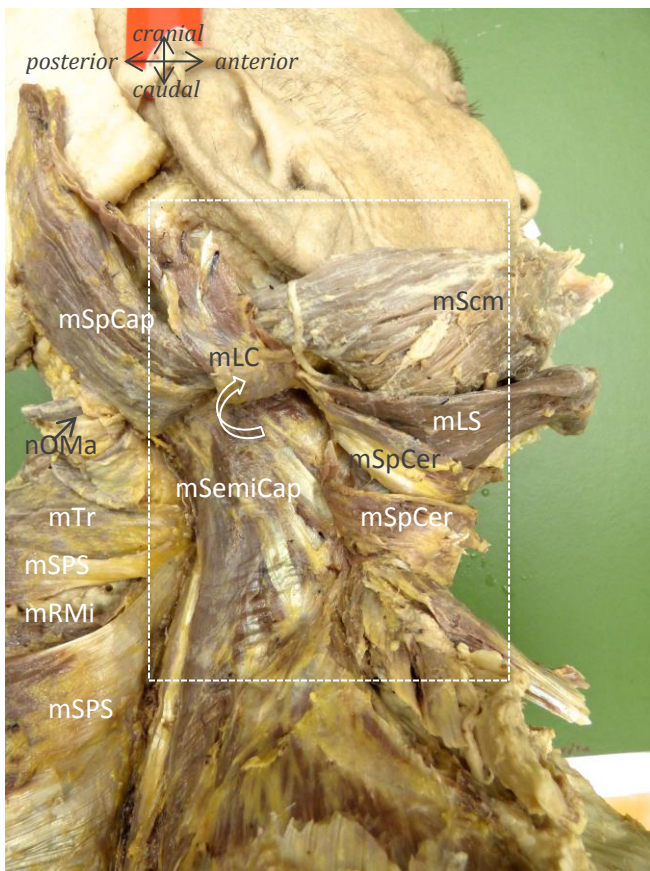
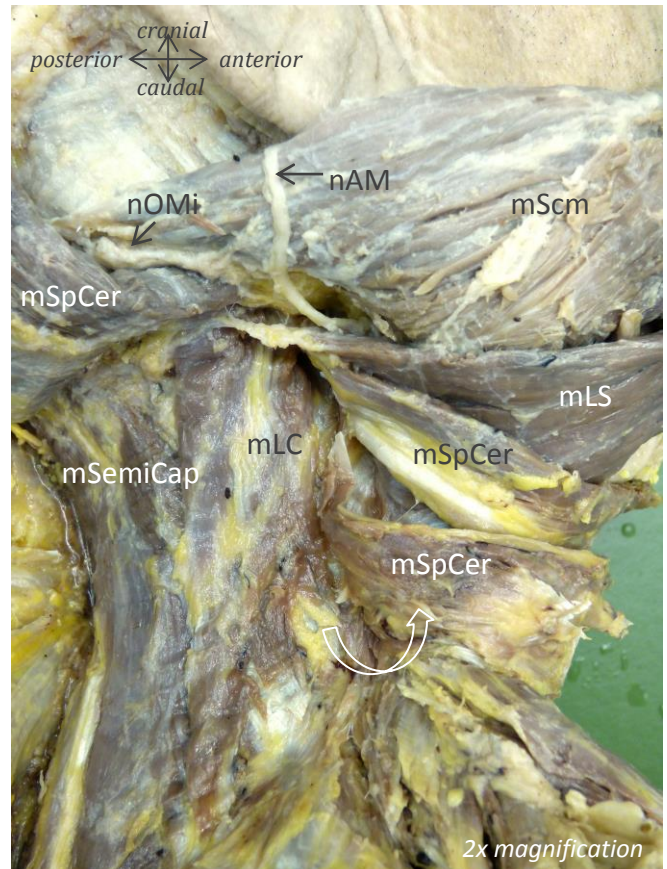
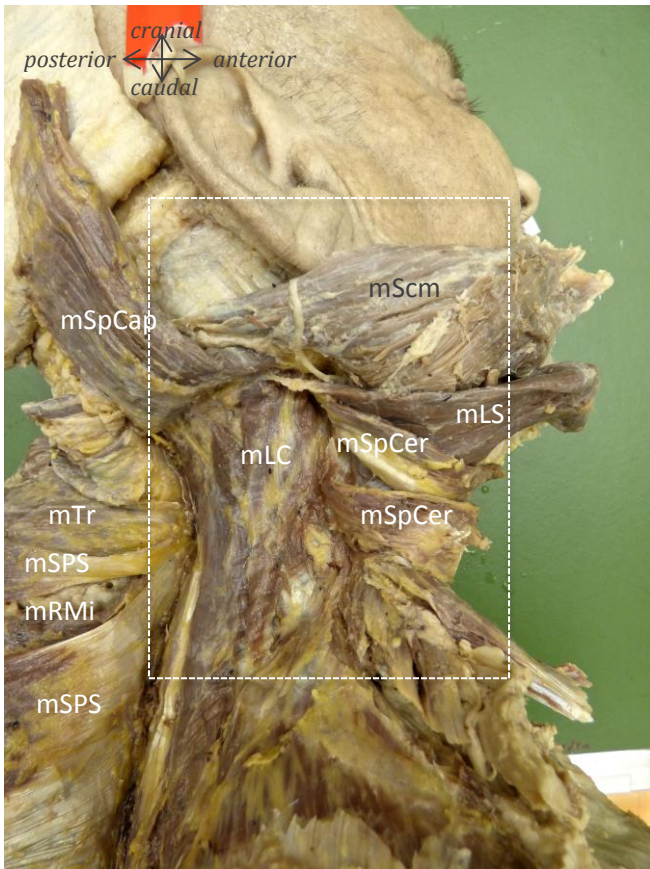
Vessels: vJI = v. jugularis interna

Male, 67 years of age



Muscles: mScm = m. sternocleidomastoideus; mLS = m. levator scapulae; mLC = m. longissimus capitis; mSpCap = m. splenius capitis; mSpCer = m. splenius cervicis; mSemiCap = m. semispinalis capitis; mTr = m. trapezius; mSPS = m. serratus posterior superior; mScP = m. scalenus posterior; mScM = m. scalenus medius
Nerves: nAM = n. auricularis magnus; nOMi = n. occipitalis minor; nOMa = n. occipitalis major

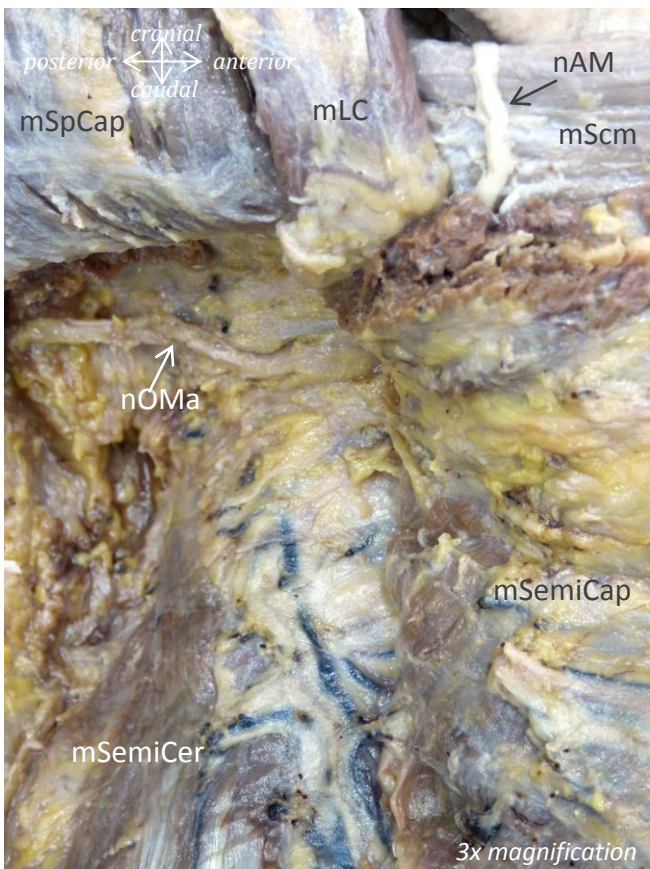
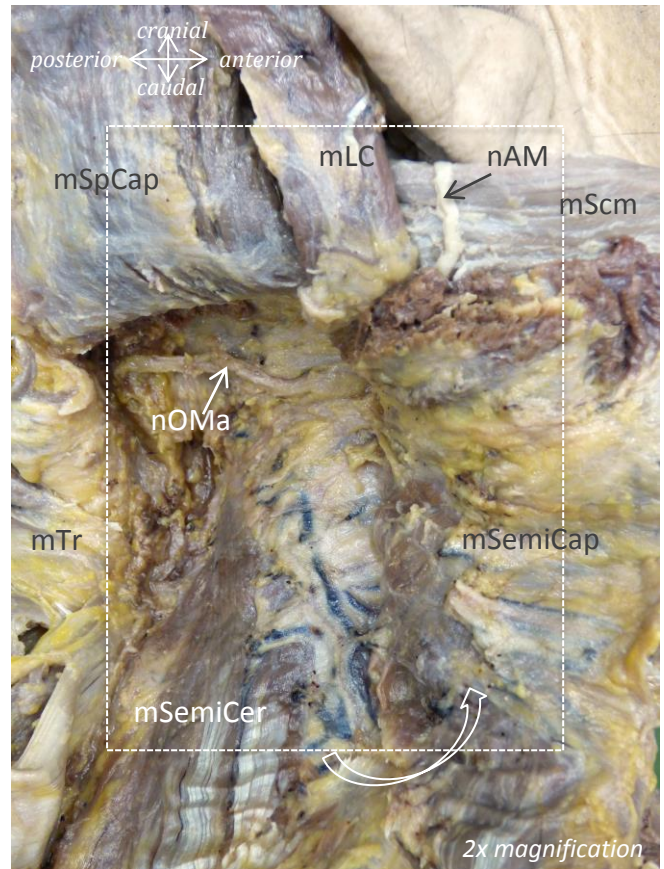
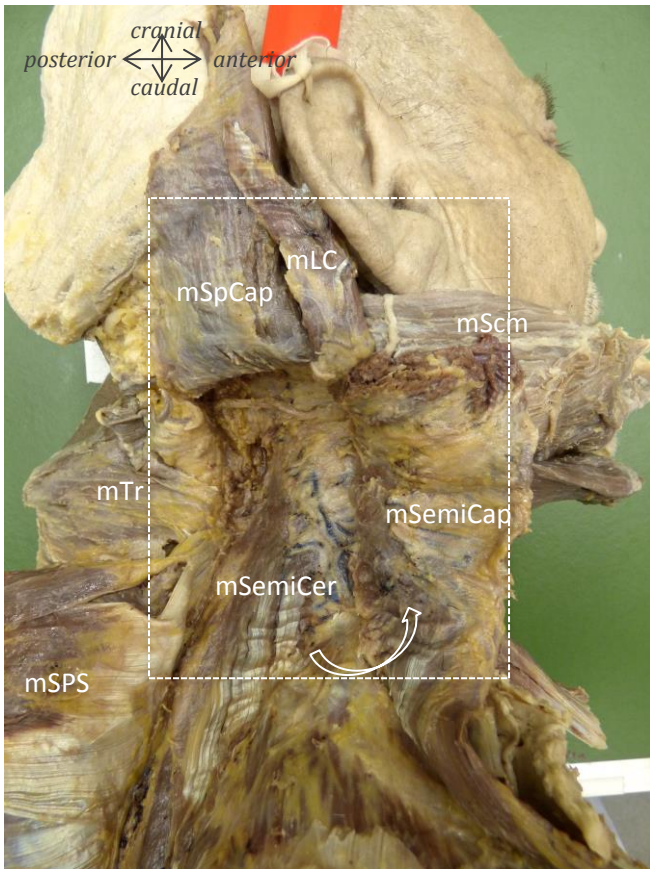
Male, 67 years of age



Muscles: mScm = m. sternocleidomastoideus; mLS = m. levator scapulae; mLC = m. longissimus capitis; mSpCap = m. splenius capitis; mSpCer = m. splenius cervicis; mSemiCap = m. semispinalis capitis; mTr = m. trapezius; mRMI = m. rhomboideus minor; mSPS = m. serratus posterior superior

Nerves: nAM = n. auricularis magnus; nOMi = n. occipitalis minor; nOMa = n. occipitalis major

Male, 67 years of age



Muscles

- mScm = m. sternocleidomastoideus
- mLC = m. longissimus capitis
- mTr = m. trapezius
- mSPS = m. serratus posterior superior
- mSpCap = m. spinalis capitis
- mSemiCer = m. semispinalis cervicis

Nerves

- nAM = n. auricularis magnus
- nOMa = n. occipitalis major