

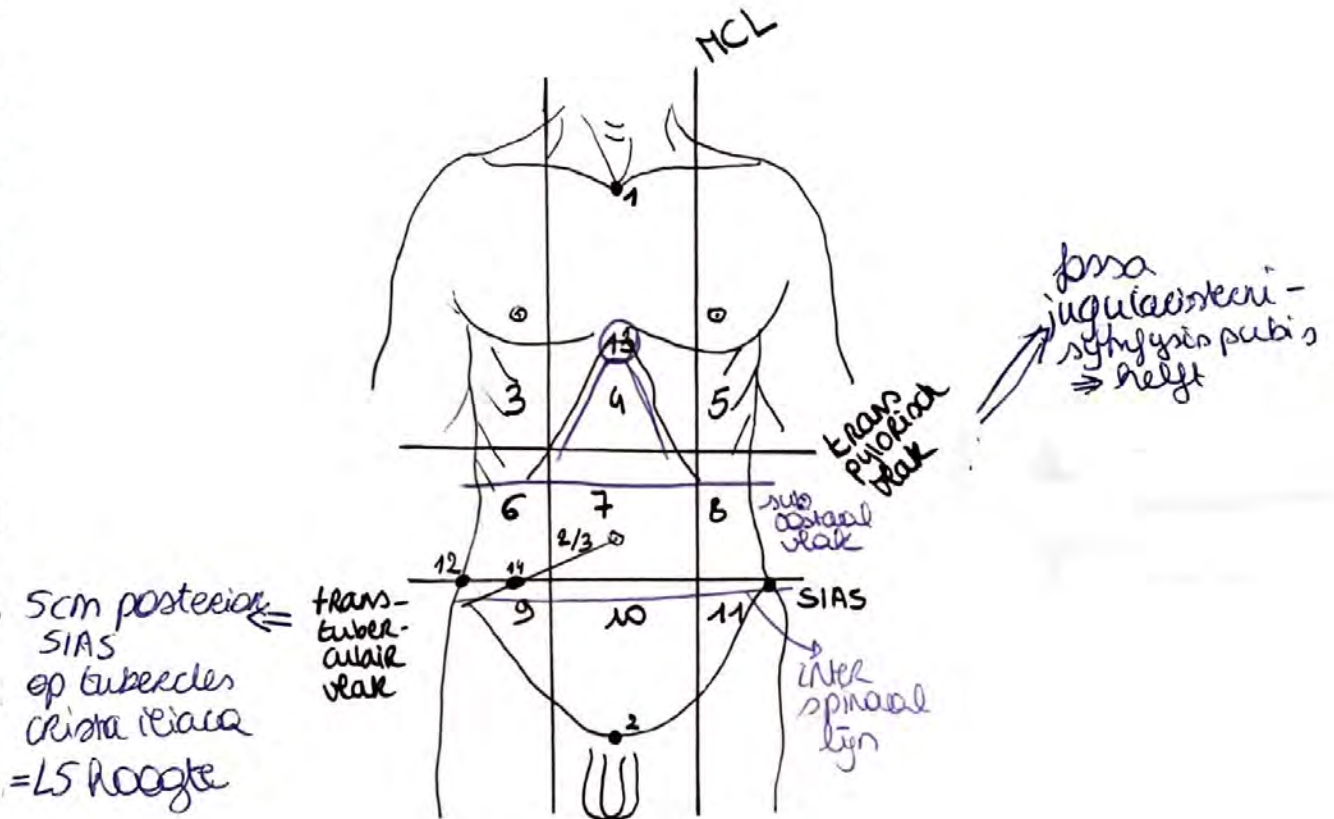
ABDOMEN

Jaar 3

BOEK 1

* Anatomie

Regiones Abdominales

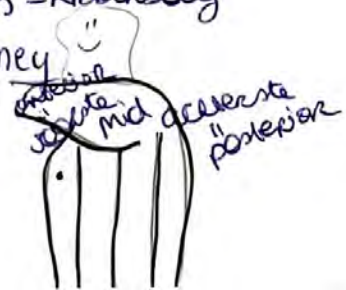

scm posterior
SIAS
ep tubercles
Crista iliaca
= L5 hoogte

1. fossa jugularis sterni
2. symphysis pubis
3. Regio hypochondriaca R
4. regio epigastria = epigastrium
5. regio hypochondriaca L
6. regio lateralis (lumbalis) R
7. regio umbilicalis
8. regio lateralis (lumbalis) L

9. regio inguinalis (iliaca) R
10. regio ^{supra}pubica (hypogastrica)
11. regio inguinalis/iliaca L
12. tuberculum crista iliaca
13. arcus costalis = ribbenboog
14. punt v. McBurney

+ axillair lijn



* **Rectus abdominis**

- o: kraakbeen 5-7^e Rib
proc. xiphoides sternum
- i: os pubis (vs tuberculum pubicum en nymfje)
- nn. intercostales (th 5-12)

* **M. transversus abdominis**

- o: 7-12^e Rib, fascia thoracolumbalis
crista iliaca, SIAS, lig inguinale
- i: rechusschede, linea alba
- n: nn. intercostales (th 5-12), nn. iliohypogastricus, ilioinguinalis, genitofemoralis

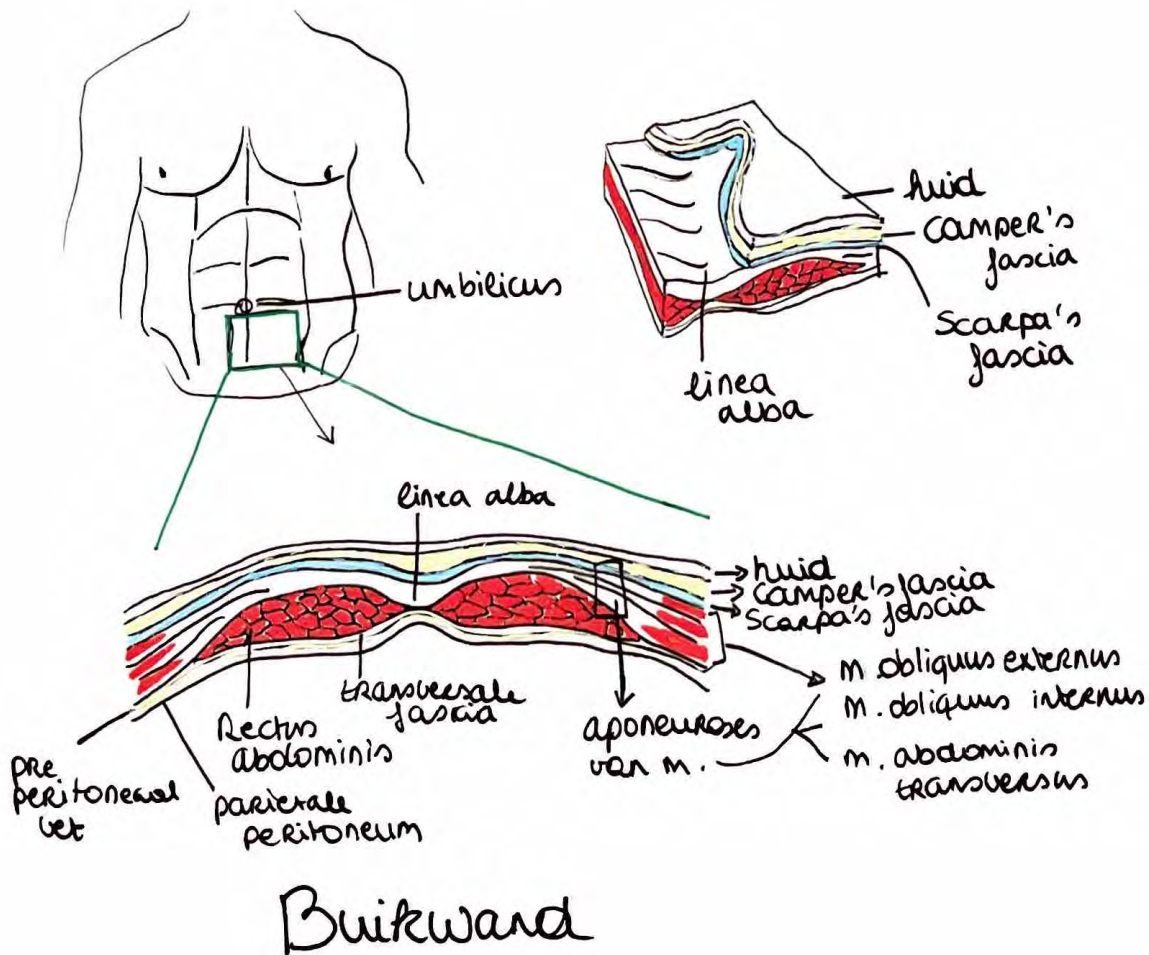
* **M. obliquus**

externus abdominis

- o: 5-12^e Rib
- i: crista iliaca, Rechusschede, linea alba
- nn. intercostales Th 5-12
- n. iliohypogastricus

* **M. obliquus internus abdominis**

- o: fascia thoracolumbalis, crista iliaca, SIAS, lig inguinale
- i: 10-12^e Rib, Rechusschede, linea alba, overgang m. cremaster
- n: nn. intercostales Th 8-12, n. iliohypogastricus, n. ilioinguinalis

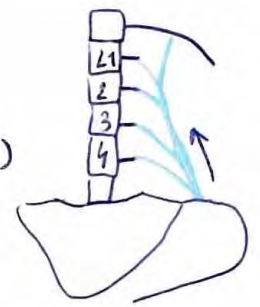

= opp. subcutane
vetaag
= diepe subcutane
vindwepellaag

Buikwand

*** M. quadratus lumborum**

- o: crista iliaca
- i: 12^e Rib, L1-4
- n: n. subcostalis (n. intercostalis XII)



*** M. iliopsoas**

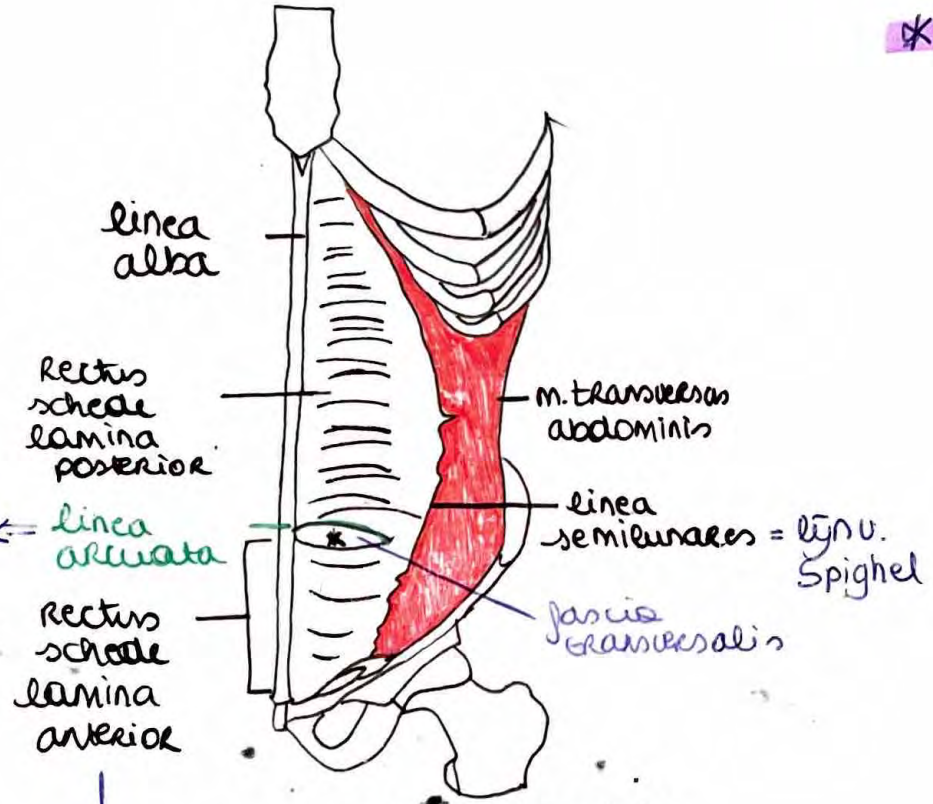
- M. psoas major
 - o: opp: Th12, L1-4
 - deep: L1-5
 - i: brachiolex minor os femoris

→ M. iliacus

- o: fossa iliaca
- i: brachiolex minor os femoris
- ⇒ n: n. femoralis (Th12-L4) + plexus lumbalis

*** M. psoas minor**


- o: T12-L1
- i: iliopubic eminence, pecten pubis
- n: L1 anterior ramus



Douglas lym

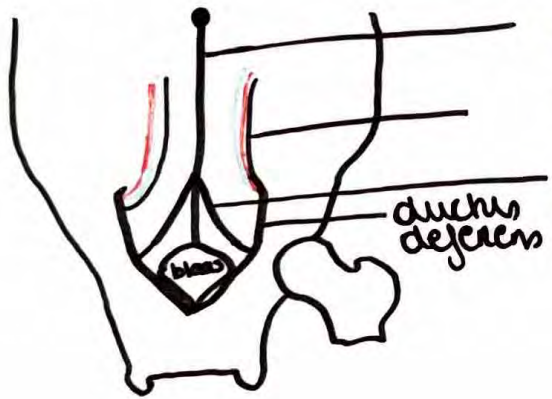
*** Rectus abdominis**

Rectusscheide = vagina musculi Recti abdominis

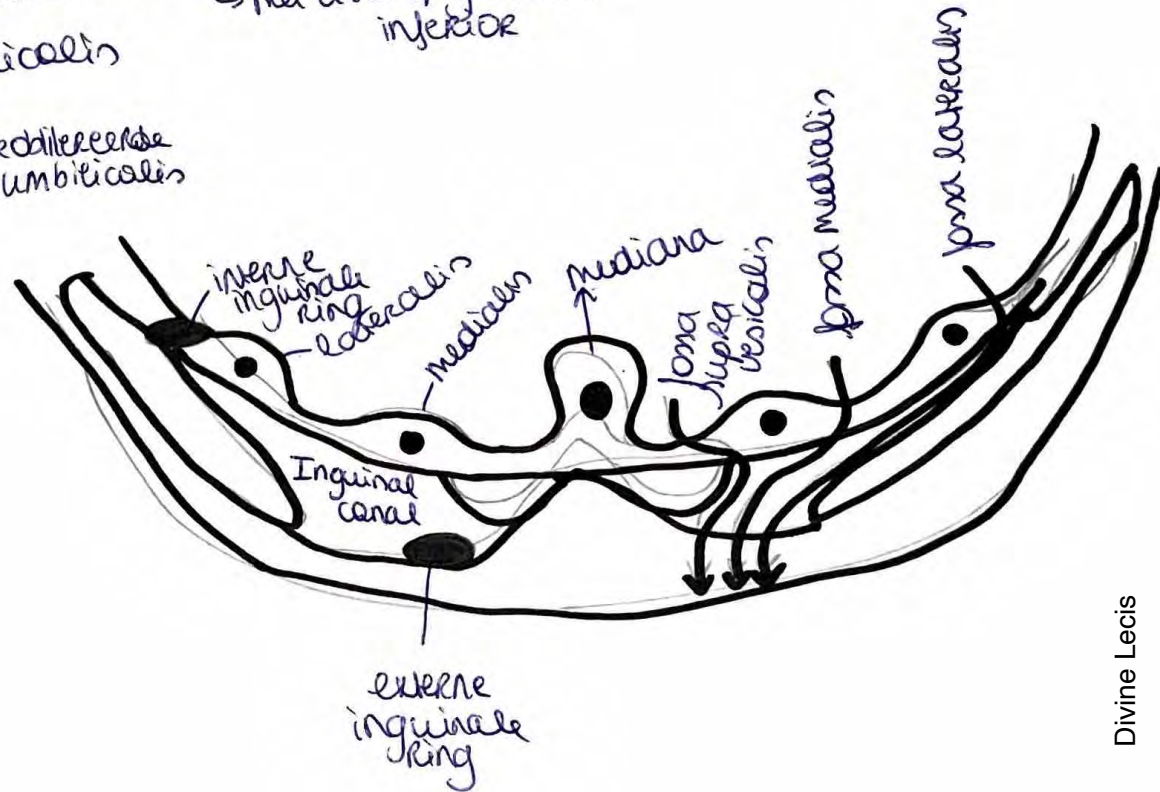


intersecciones tendineae

Buikwand

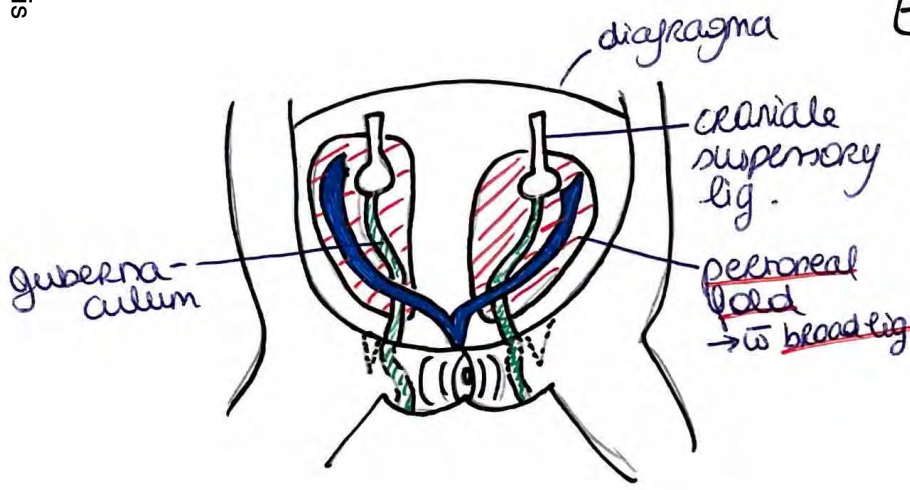


plica umbilicalis (urachus)
 mediana
 plica umbilicalis lateralis
 ↳ met a l.v. epigastrica inferior
 plica umbilicalis
 medialis
 ↳ met gedileeerde
 a. umbilicalis

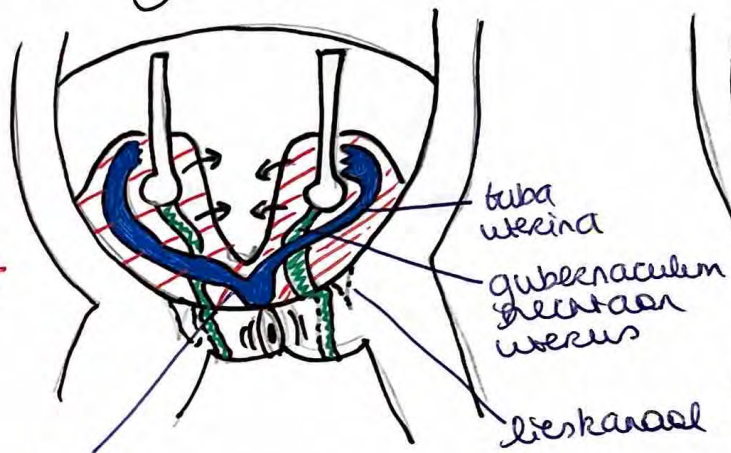


Lieskanaal (Canalis inguinalis) ♀

Embryologie

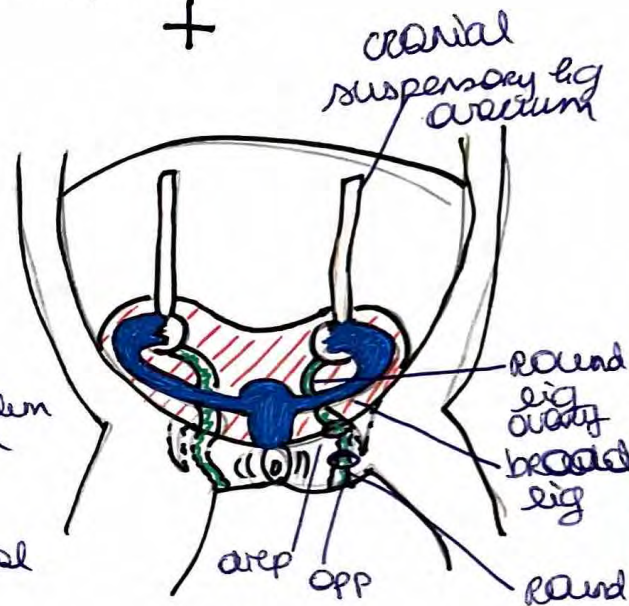


3mm



worming wees

peritoneumbladen vouwen de binnen toe en nemen beide tubae mee

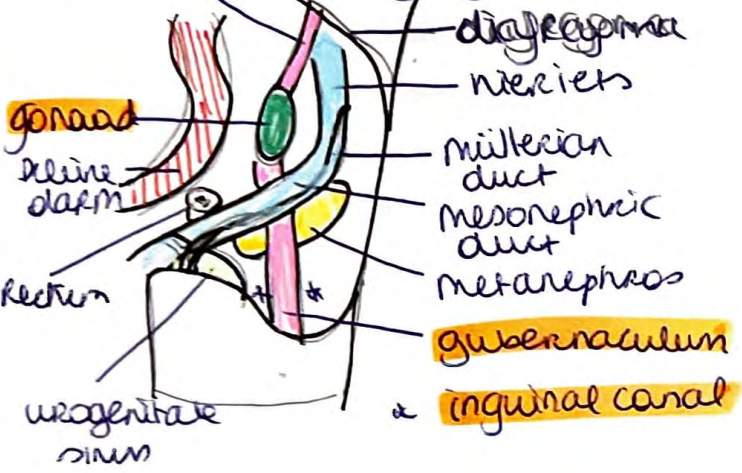


7mm

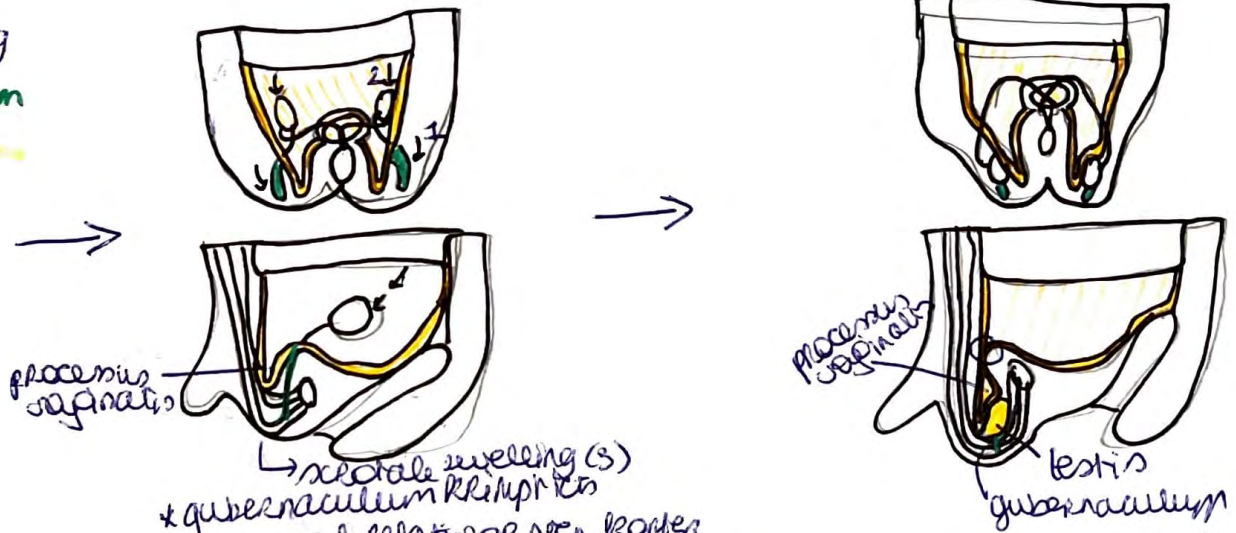
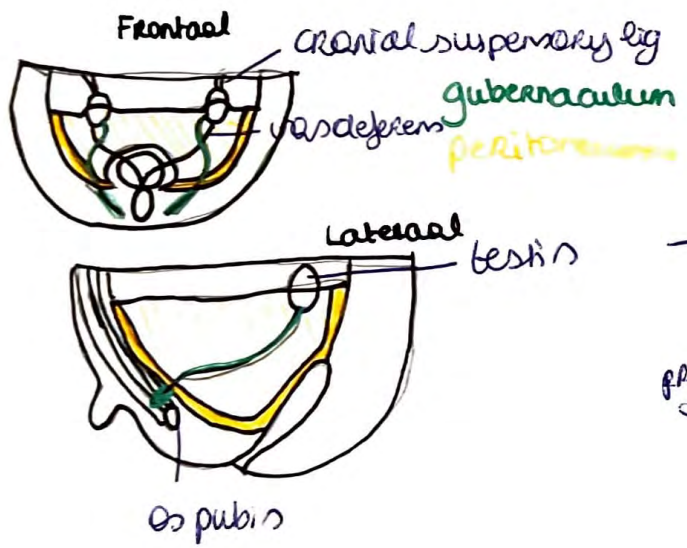
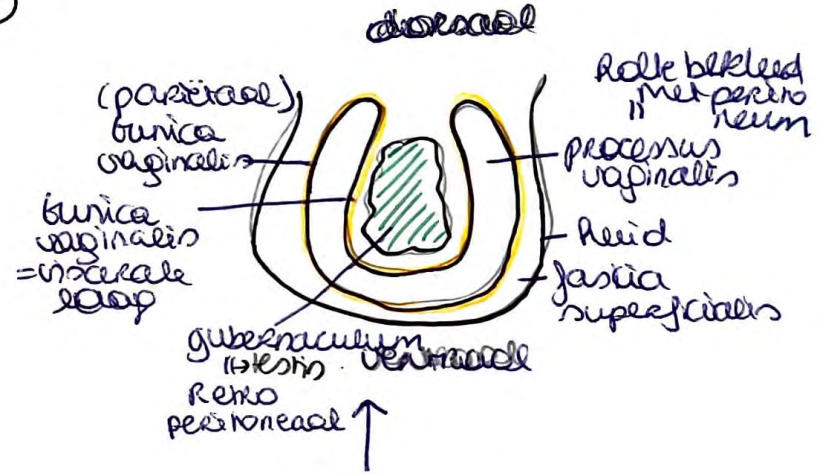
gubernaculum \Rightarrow to 2 lig

- \rightarrow rond lig \rightarrow wees en ovarium \Rightarrow lig ovarii na obliteratie = groot dicht
- \rightarrow rond lig \rightarrow wees en labia majora \Rightarrow + bindweefsel man pubis (veeueven \rightarrow verskewel)

Cranial suspensory ligament



Lieskanaal Embryologie ♂




- (2) * door gubernaculum daalt testis in
- (3) * gubernaculum trekt peritoneum mee + intulper het processus vaginalis

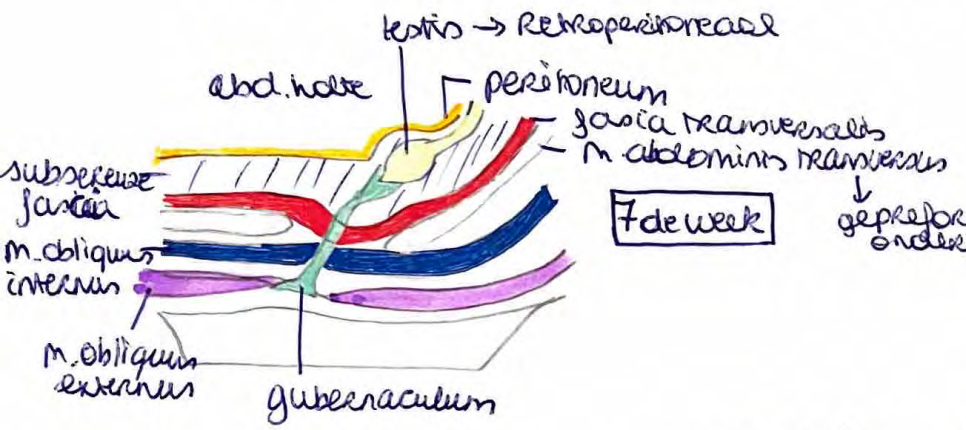
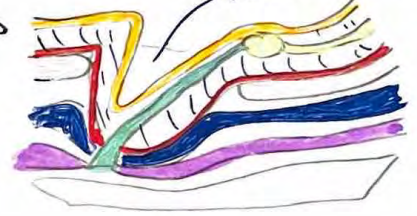* testis volledig ingedaald = in scrotum/abdomen
* doortreekt (groeit dicht) processus vaginalis
→ scrotum afzonderdelyk deel tot abdominale holte

Embryologie lieskanaal ♂

M. cremaster
 O: obliquus internus
 i: tunica vaginalis
 n: n. genitofemorals

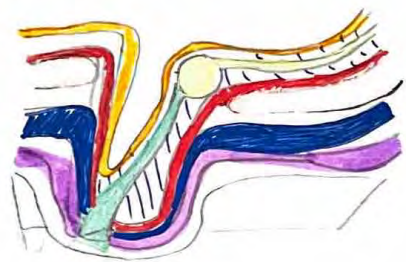

42de week



7de week

gepreformeerde onderbreking

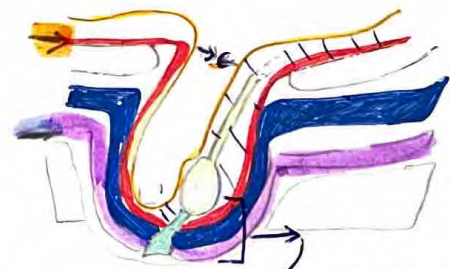


8ste maand

naast invulpend peritoneum
 ook spierfasie, bloedvaten,
 lymfevaten, zenuwen, ductus
 vas deferens met indalende
 testes meegenomen

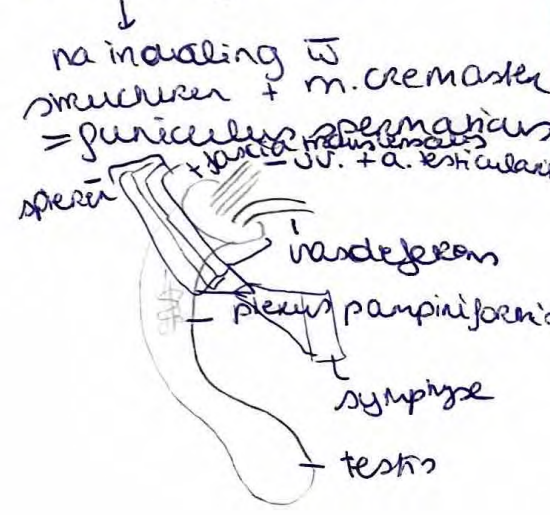


8ste week



9de maand

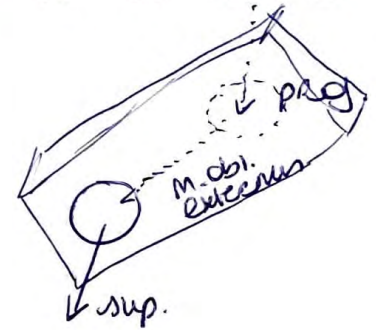
- na 9m
- fascia transversalis → interne spermatic fascia
 - m. Obliquus internus → fascia cremaster
 - m. obliquus externus → fascia spermatica externa



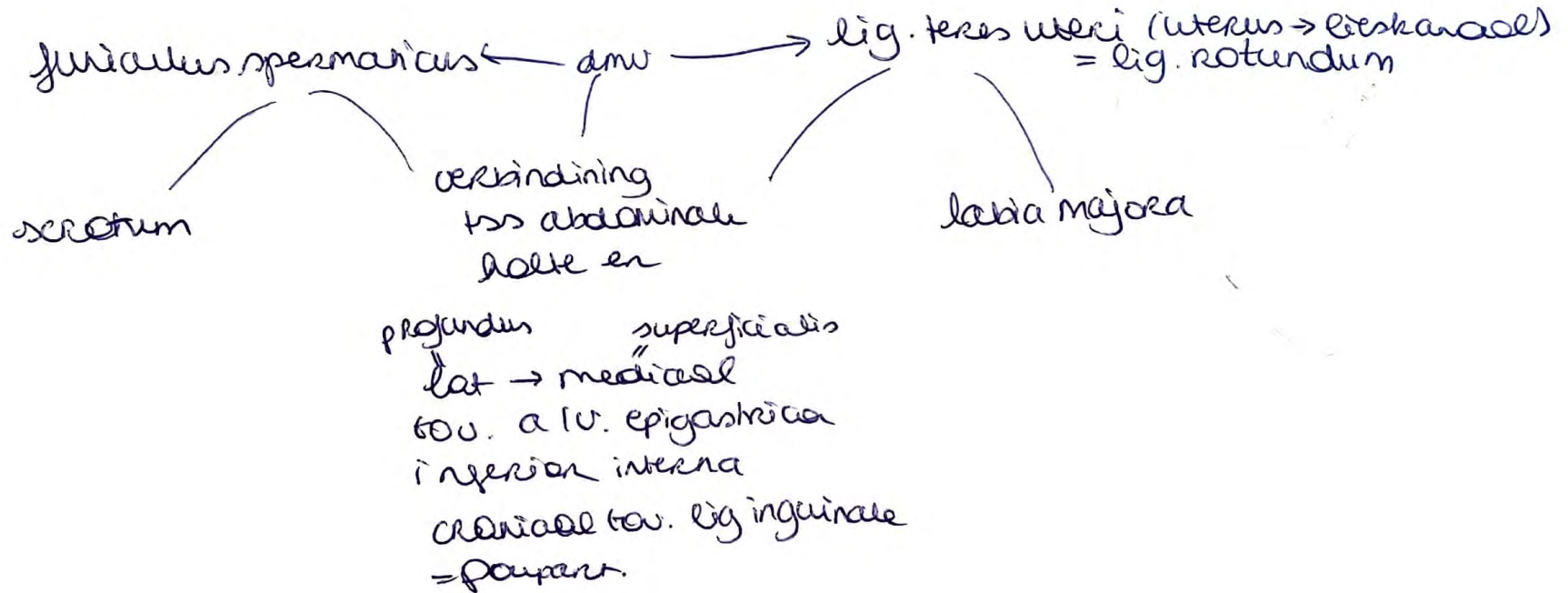
Lieskanaal

M

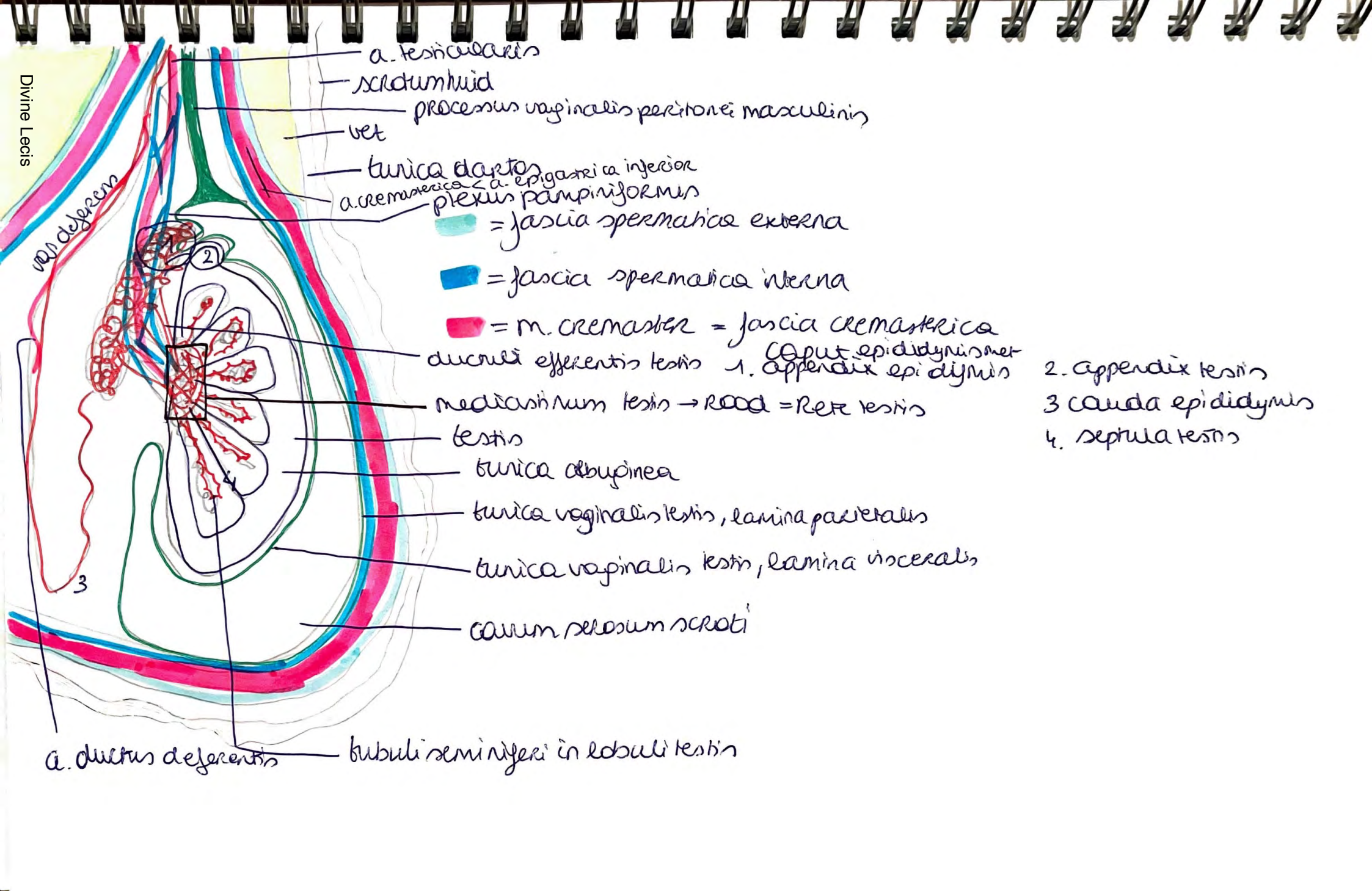
V



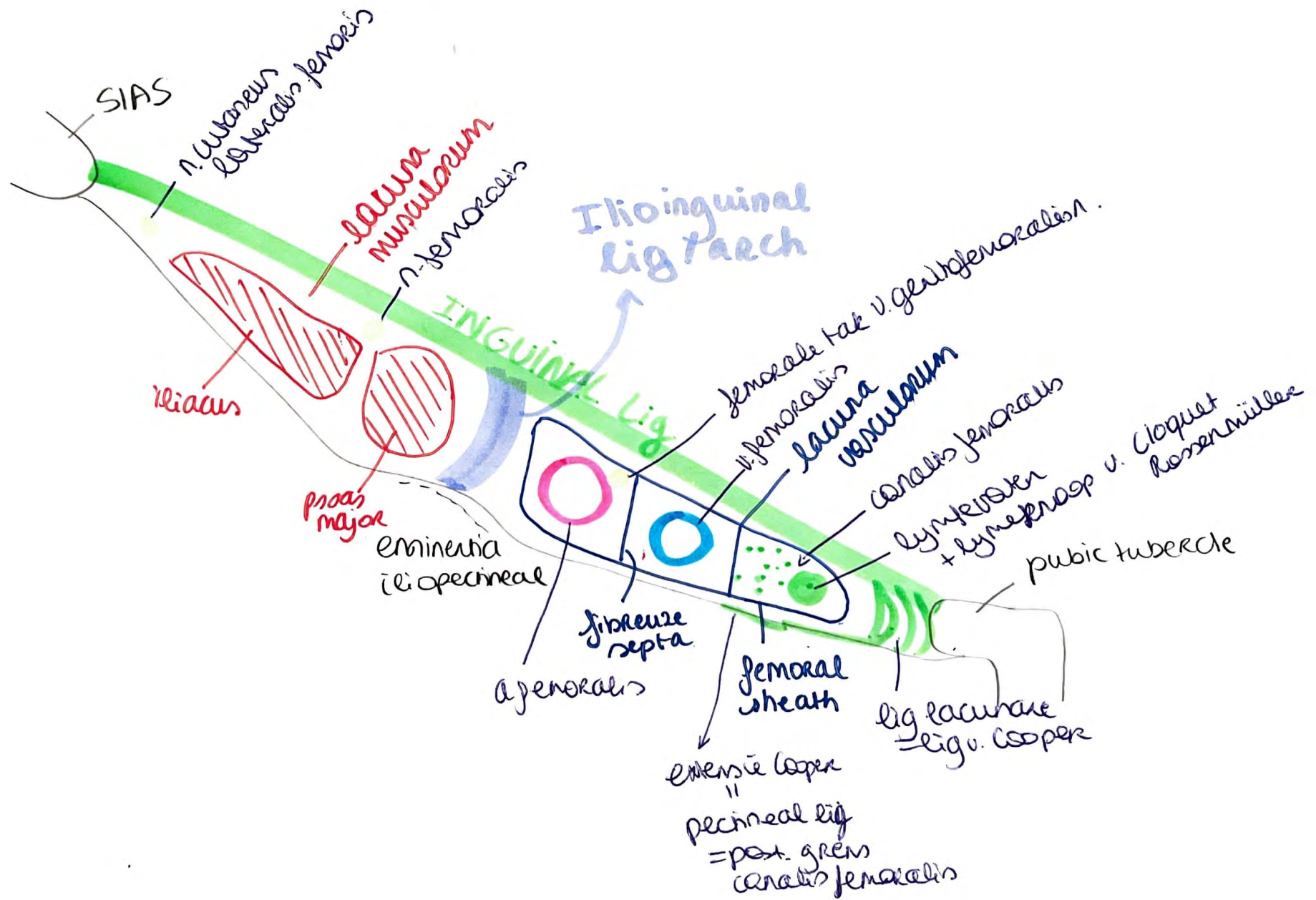
beide
ca. 4 cm



Divine Lecis

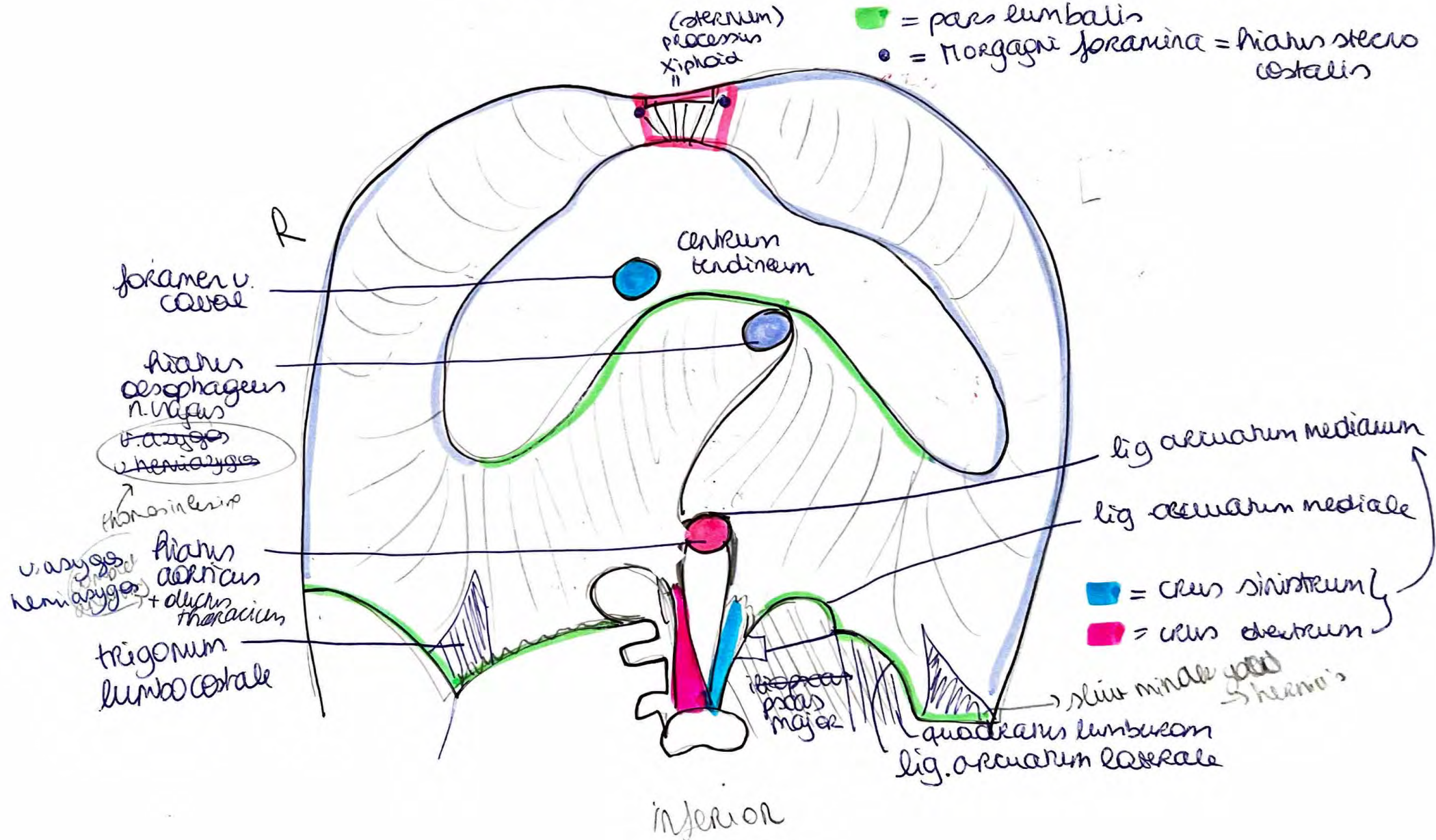


- a. testicularis
- scrotum huius
- processus vaginalis peritonei masculinus
- vet
- tunica dartos
- a. cremasterica
- a. epigastrica inferior
- plexus pampiniformis
- = fascia spermatica externa
- = fascia spermatica interna
- = m. cremaster = fascia cremasterica
- ductuli efferentis testis
- caput epididymis met
- 1. appendix epididymis
- 2. appendix testis
- 3. cauda epididymis
- 4. septula testis
- mediana testis → Rete = Rete testis
- testis
- tunica albuginea
- tunica vaginalis testis, lamina parietalis
- tunica vaginalis testis, lamina visceralis
- corium pelosum scroti
- lobuli seminiferi in lobuli testis
- a. ductus deferentis



Diaphragma thoracoabdominalis

- █ = pars sternalis
- █ = pars costalis diaphragmatis
- █ = pars lumbalis
- = Morgagni foramina = hiatus sterni costalis



inferior

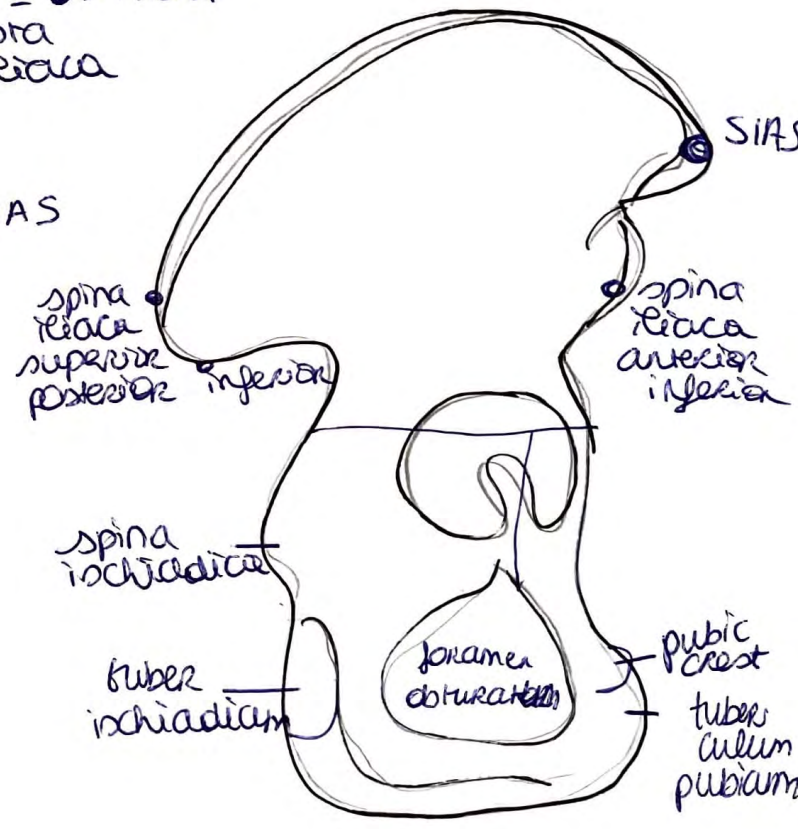
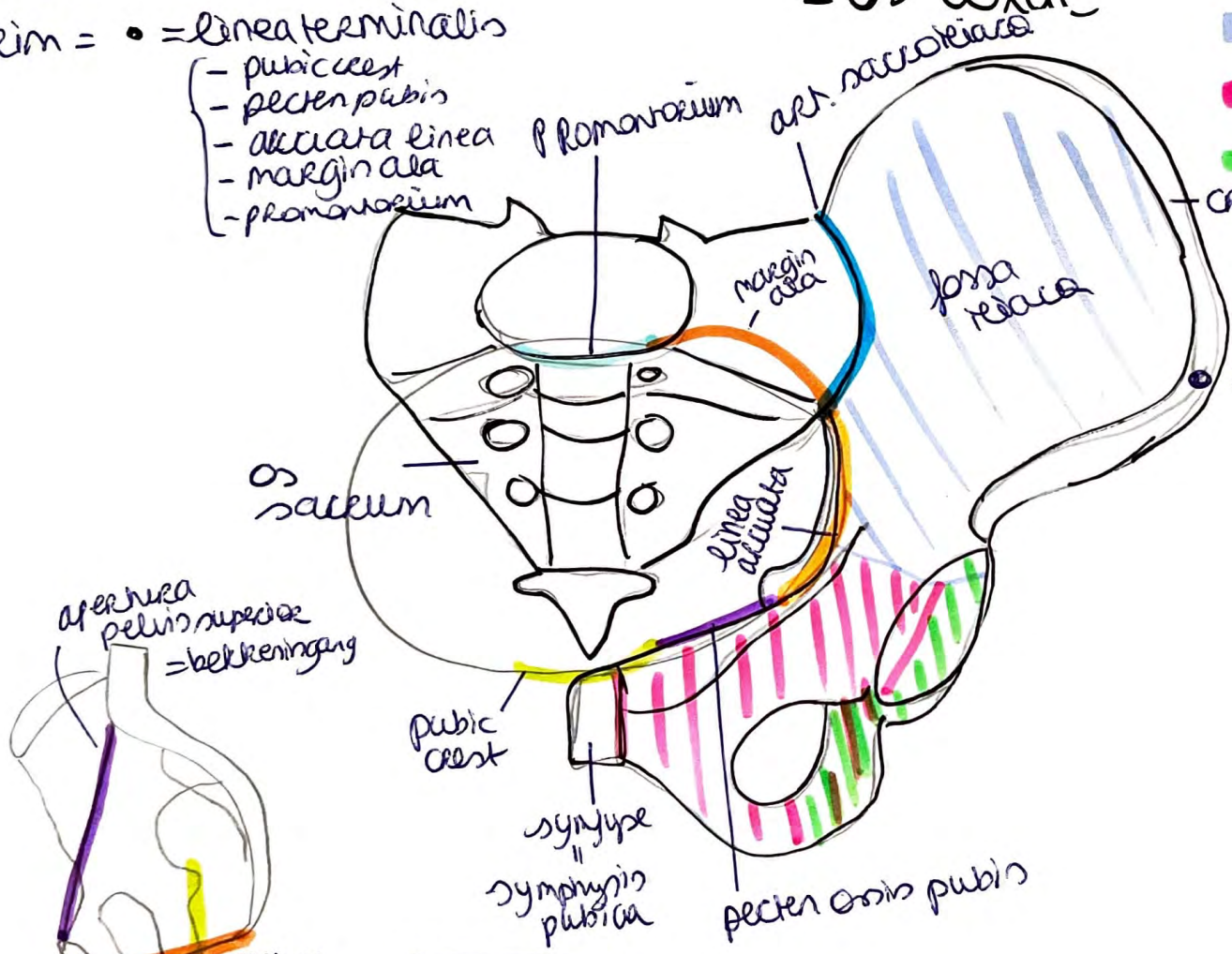
pelvis major = boven beem
 pelvis minor = onder beem
 beem = • = linea terminalis

- pubic crest
- pecten pubis
- alciata linea
- margin ala
- promontorium

Pelvis (bekken)

= os coxae

- = os ilium
- = os pubis
- = os ischii

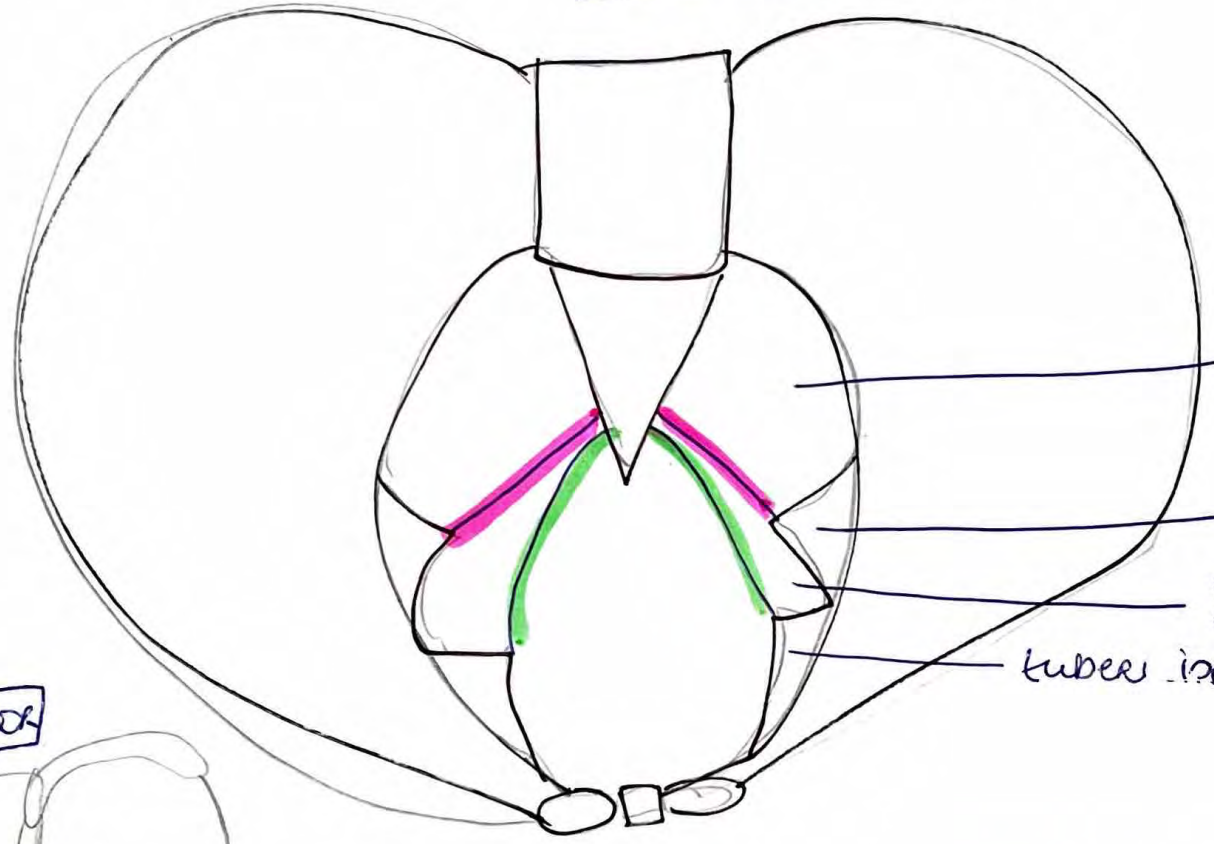


anterior

lateral R

canalis pudendalis = parasel v. Alcock
 = n. pudendus
 = a. pudenda interna + v. } in fossa ischioanalis

anterior



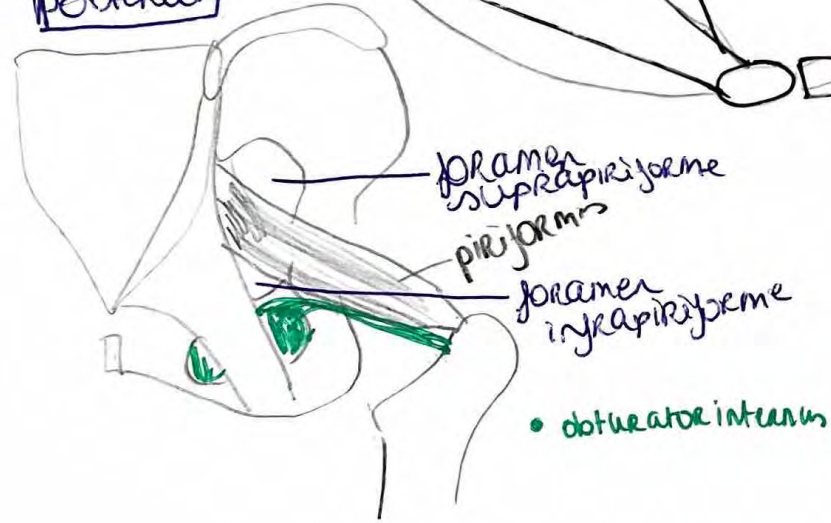
foramen ischiadicum majus

spina ischiadica

foramen ischiadicum minus

tuber ischiadicum

posterior



foramen suprapiriforme

piriformis

foramen infrapiriforme

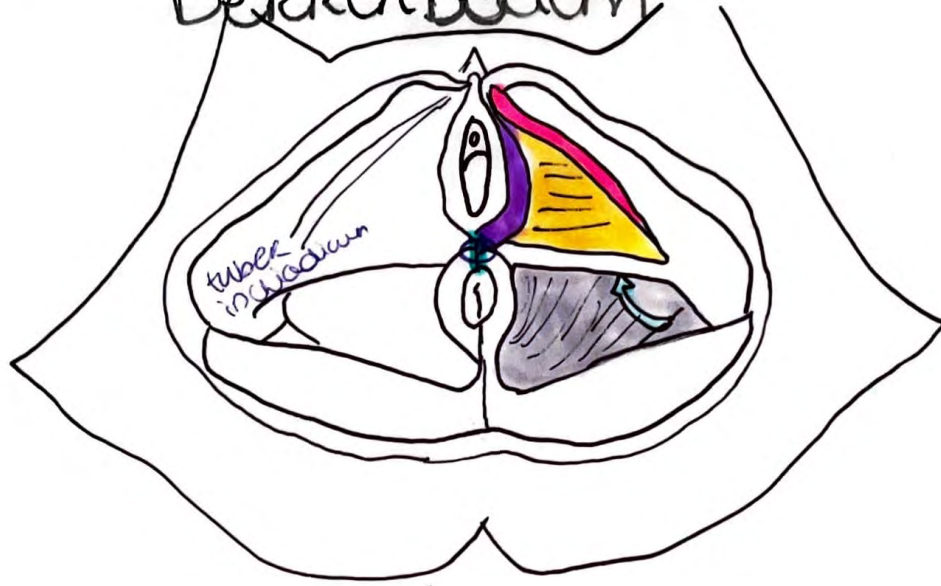
• obturator internus

■ = lig. sacrotuberale

■ = lig. sacrospinale

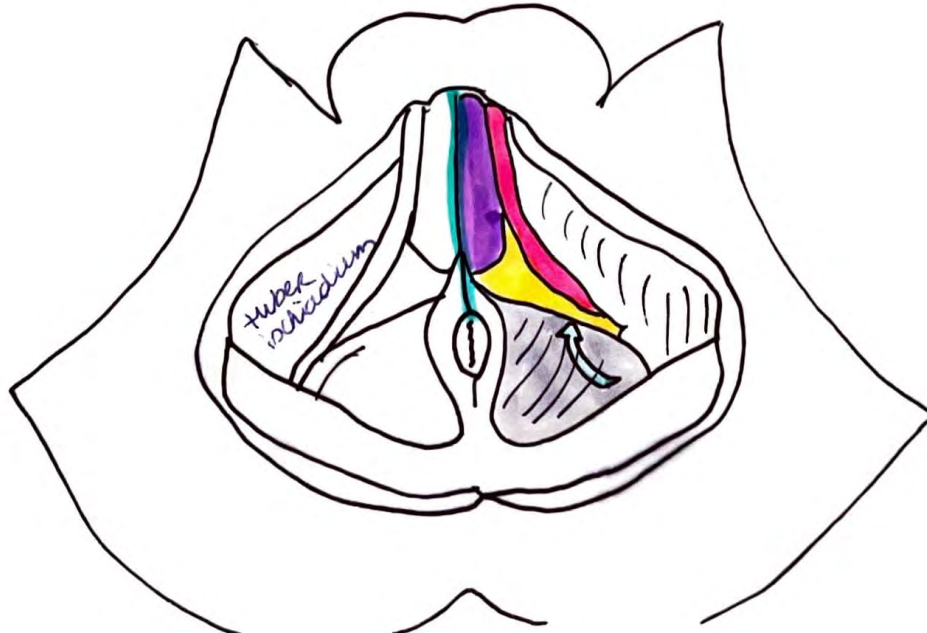
Bekkenbodern

V
caudaal

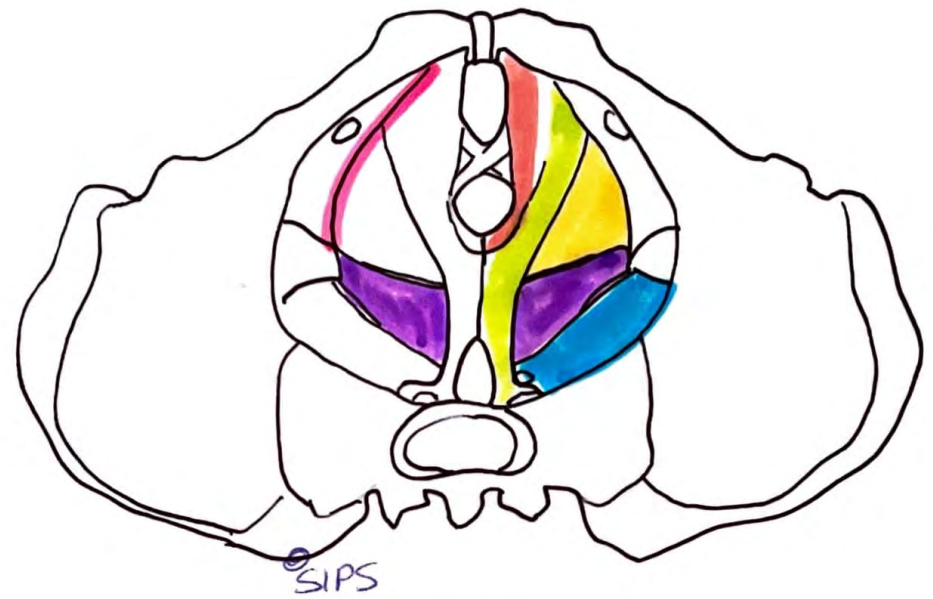


- o = centrum perinei
- = m. ischioocavernosus
- = m. bulbospongiosus
- = subcutane ruimte
= linker fossa ischio
analis = ischioanal
- = m. levator ani
→ m. pubococcygeus
→ m. puborectalis
→ m. aniococcygeus
- = fascia diaphragma
urogenitalis inferior
= membrana perinei
- = perineum = huid

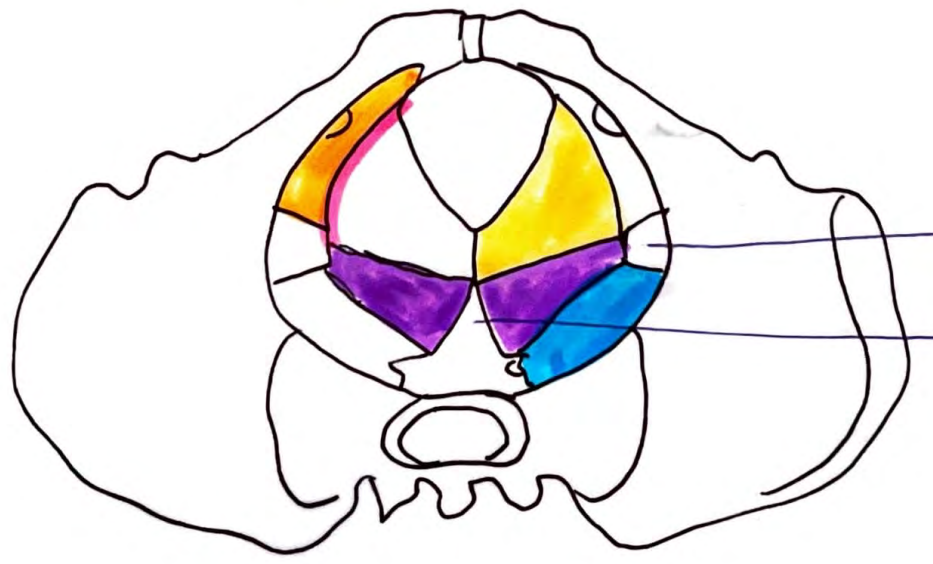M
caudaal



Levator ani craniasl, v



- = aacus tendineus (m. levatoris ani)
 - = m. coccygeus *
 - = m. piriformis
 - = m. iliococcygeus
 - = m. puborectalis
 - = m. pubococcygeus
- } m. * levator ani
- = m. obturatorius internus

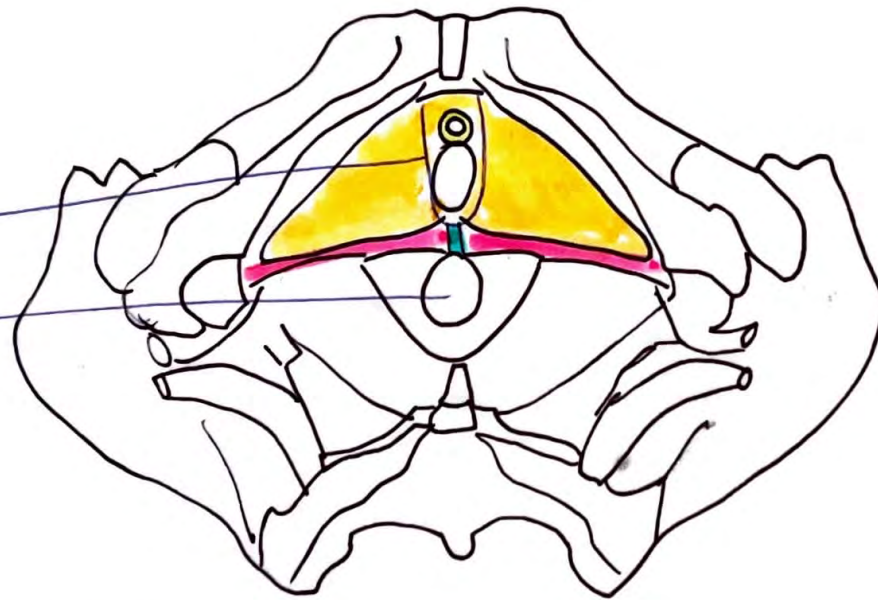


spina ischiadica

os coccygis

* + * = diafragma pelvis = Beckenboden

(Urogenitalindex)
 hiatus
 urogenitalis
 hiatus
 ani



p. 186 B.
 Schlüsselwort
 urogenitale

= centrum (perineum)
 perineum

= m. sphincter
 urethrae externus

= m. transversus
 perinei superficialis

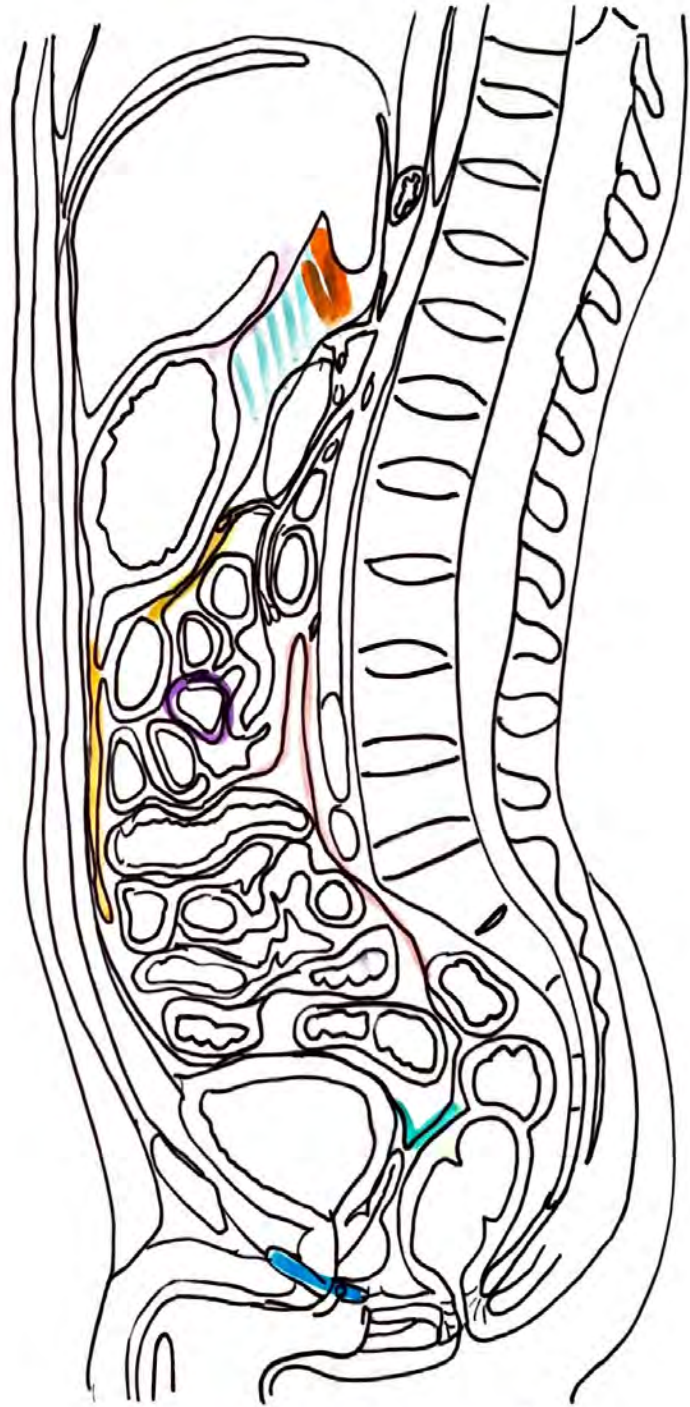
= m. transversus
 perinei profundus

urogenitale
 diafragma

Buikholte en peritoneum

cavitas peritonealis
 = ruimte t/m peritoneum
 viscerale en parietale

- = peritoneum parietale
- = excavatio retrovesicalis
- = diaaphragma urogenitale
- = omentum majus
- = mesocolon transversum



- = bursa omentalis
- = lig. hepatogastricum
 = omentum minus
- = foramen omentale = epiploicum
 = Winslow
- = peritoneum viscerale



intra peritoneaal

→ meso

cavitas peritonealis abdominis

- maag
- milt
- lever + galblaas
- duodenum: pars superior, pars ascendens gedeelte

cavitas peritonealis pelvis

- fundus + corpus uterus
- ovarium
- tuba uterina
- evt. bovenste deel rectum



- jejunum, ileum
- colon transversum
- colon sigmoideum
- caecum variabel

extra peritoneaal

→ geen meso

primair = embryonaal

- center abdominis = retro peritoneaal
- nieren
 - bijnieren
 - ureters

onder abdominis = infra / subperitoneaal

- urineblaas
- prostaat
- vesicula seminalis
- cervix uteri
- vagina
- rectum vanaf flexura sacralis

secundair

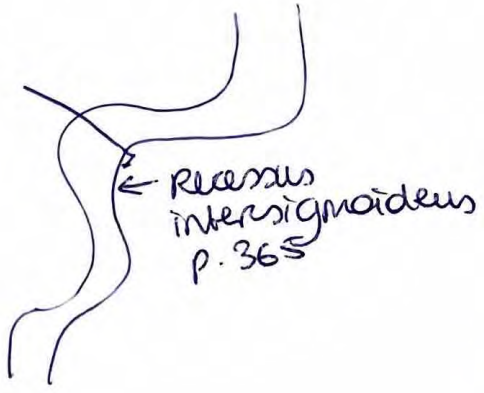
= voorzijde van peritoneale bekleedings

|| Retroperitoneaal

- duodenum: pars descendens, horizontalis, beide ascendens
- pancreas
- colon ascendens
- colon descendens
- caecum variabel
- rectum tot flexura sacralis

Retroperitoneaal = spatium retroperitoneale

lig. gastrosplenicale = gastro-splenium
 lig. lienorenale
 lig. phrenicosplenicum



sulcus paracolicus = ruimte t/m colon en abdominale wand

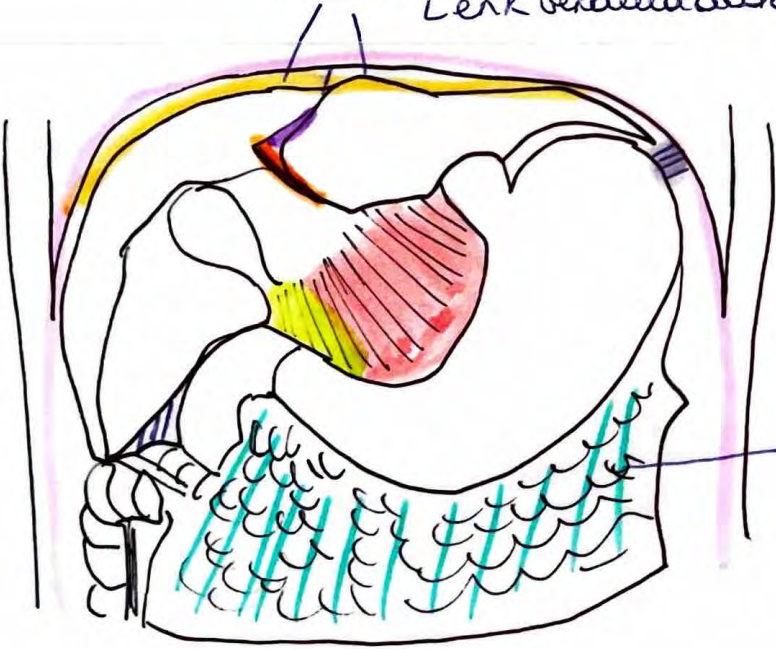


gedubbelede ductus venosus
 ↑
 lig. venosum

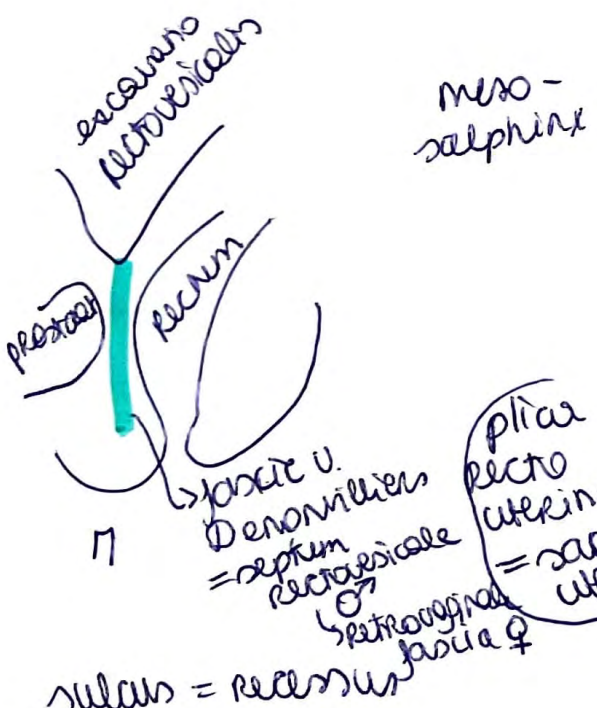
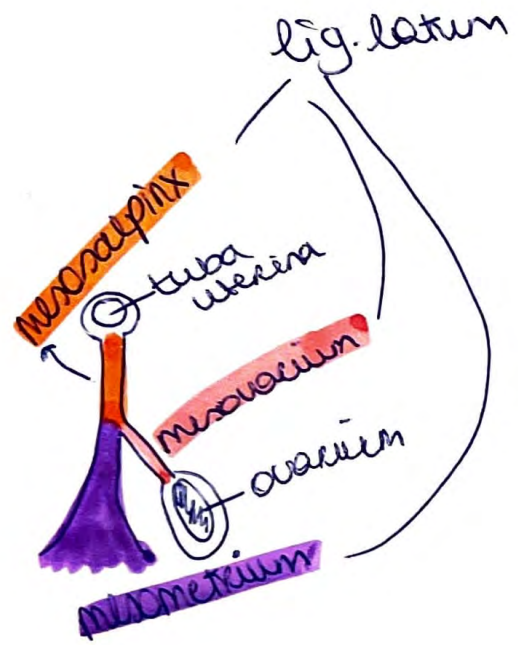


lig. triangulare dextrum et sinistrum

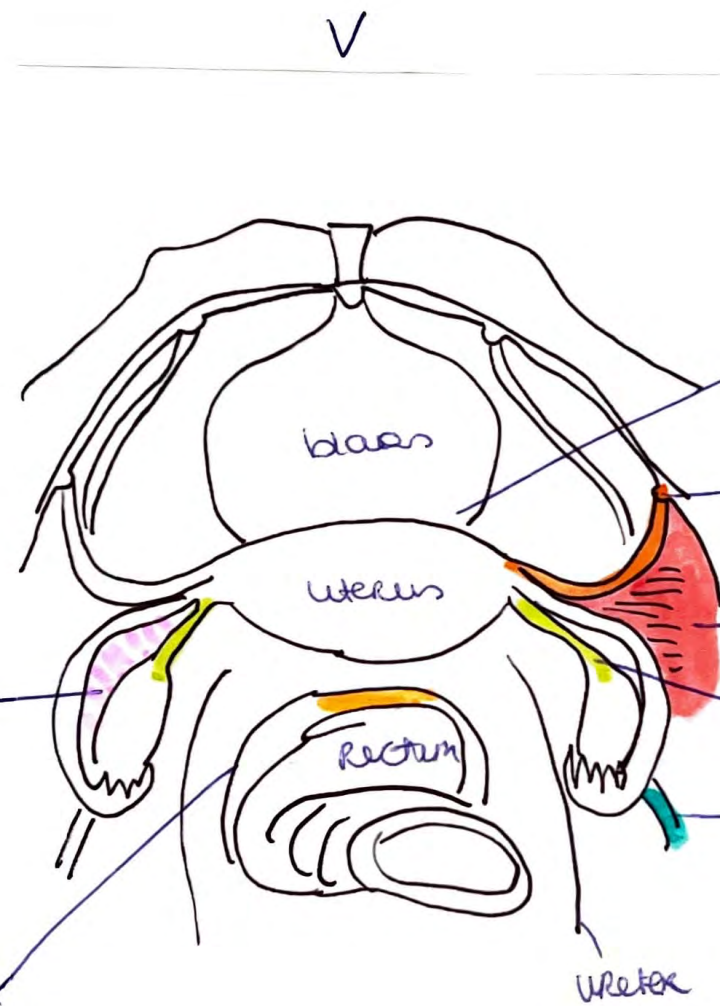
recessus subphrenicus
 Lerk verdeeld door lig. falciiforme, bepermd door lig. coronarium



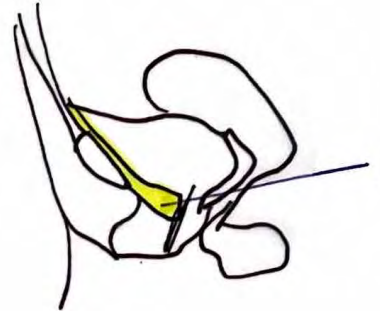
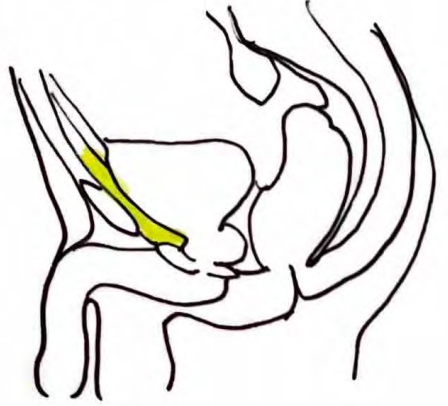
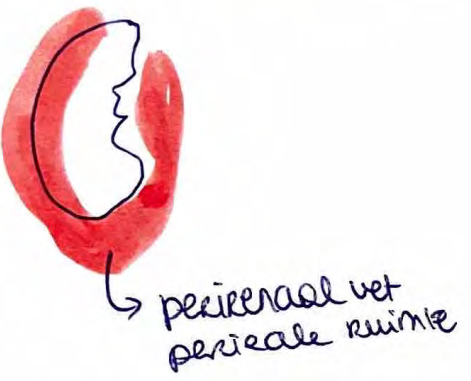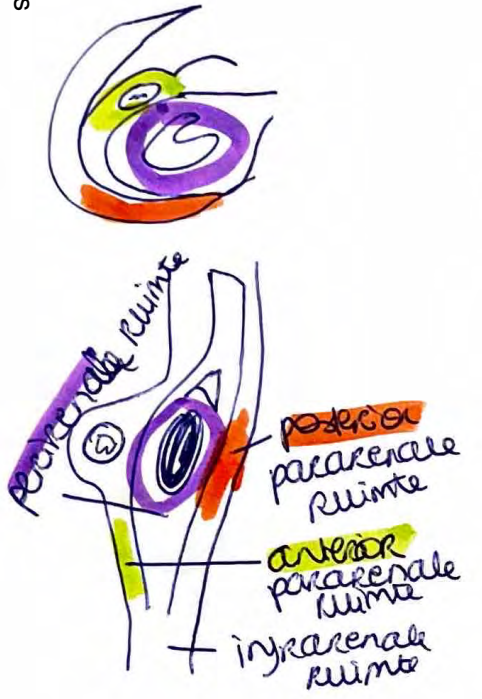
- = lig. gastrophrenicum
- = lig. falciiforme hepatis
- = lig. feres (hepatis) → tweein gedubbelede v. umbilicales
- = lig. hepatogastricum
- = lig. hepatoduodenale
- = omentum majus
- lig. gastrocolicum = gastro → colon transversum
- = peritoneum parietale
- = lig. coronarium
- /// = recessus subhepaticus



plica recto-uterina = sacro-uterina

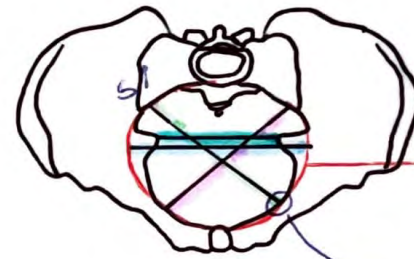
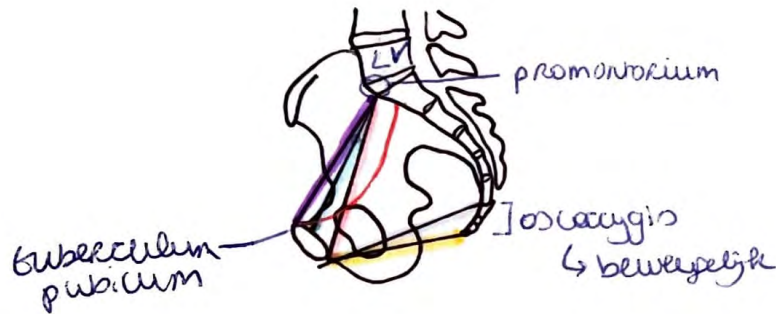


- excavatio vesico-uterina
- lig. teres uteri = lig. Rotundum uteri
- lig. latum (uteri)
- lig. ovarii proprium
- lig. suspensorium ovarii = lig. infundibulopelvicum
- excavatio recto-uterina = caecum Douglasi



spatium retroperitoneum = canum Retzii

Bekkenmaten



■ = diameter transversa
= 13,5-14cm
→ bekkenuitgangsniveau

■ = interspinale afstand
= 10cm

→ bekkenuitgangsniveau
(spina iliadica)

■ = diameter obliqua sinistra

= 12cm

→ SI op linea terminalis → eminentia

→ linea terminalis

→ eminentia iliopsoechnica

■ = diameter obliqua dextra = 12cm

■ = conjugata anatomica = ±12cm

■ = conjugata vera (obstetrica) = ±11cm
= C.V.

■ = conjugata diagonalis = 12,5-13cm
→ gebruikt om lengte C.V. af te leiden

■ = conjugata mediana = 11-12cm

■ = conjugata recta = 9(±2cm)


Lever (hepar)


→ overkapsel = tunica fibrosa = kapsel o. Glisson

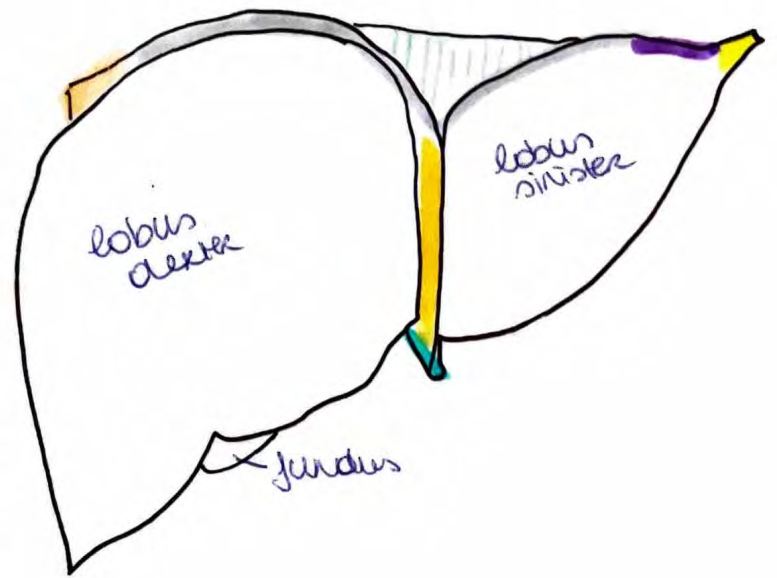
• area nuda → vast aan diafragma ⇒ niet bewegelijk wel intra peritoneaal


 = lig. falciforme hepatis

 = lig. coronarium hepatis


 = lig. triangulare sinistrum

 = lig. triangulare dextrum





 = ductus choledochus

 = ductus cysticus

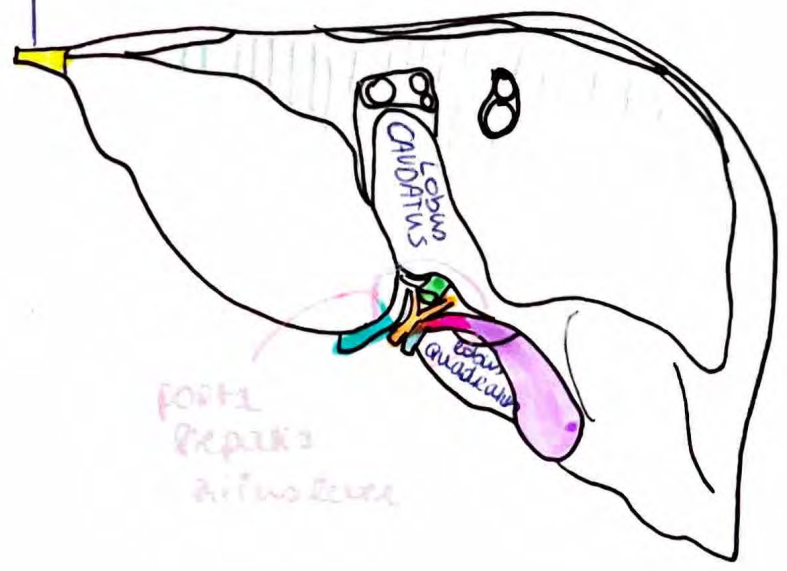
 = vesica biliaris

 = a. hepatica propria

 = v. portae hepatis

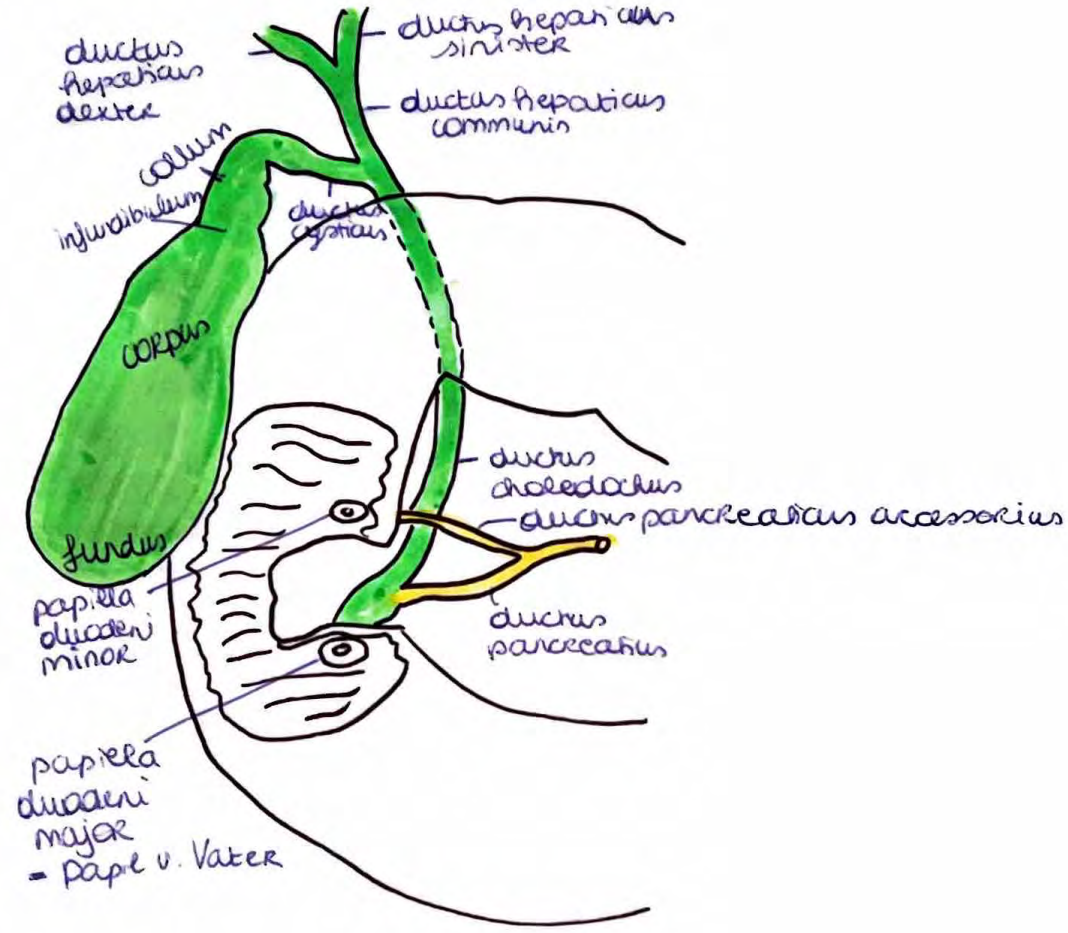
 = lig. teres hepatis

appendix
gastrohepatis



porta hepatis
arteriole

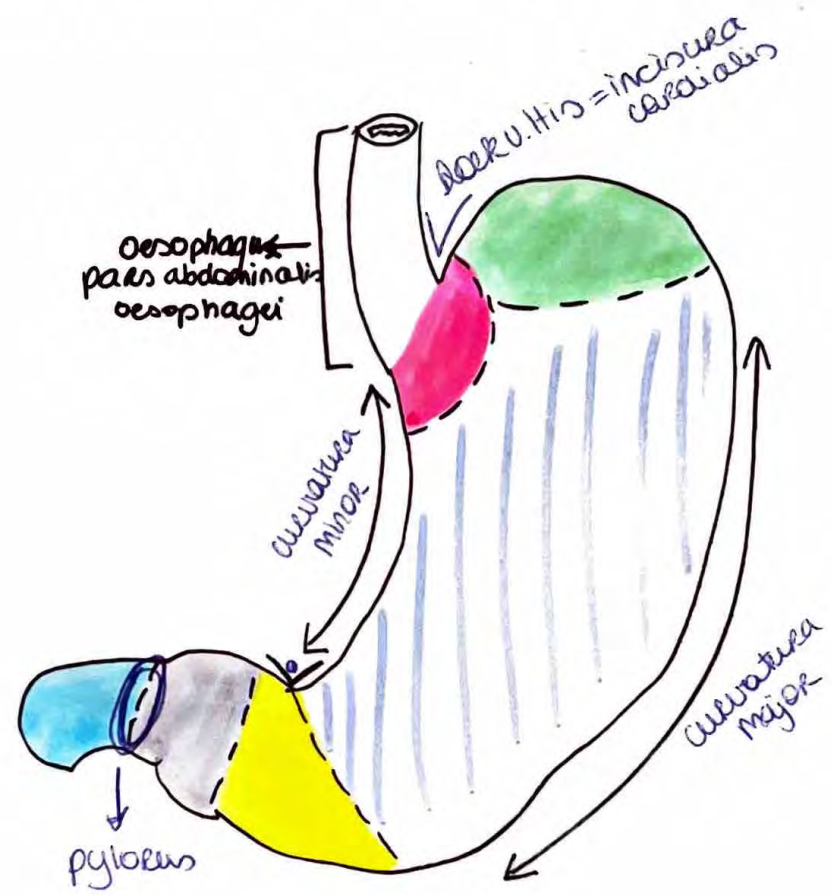
VESICA Biliaris



p. 258

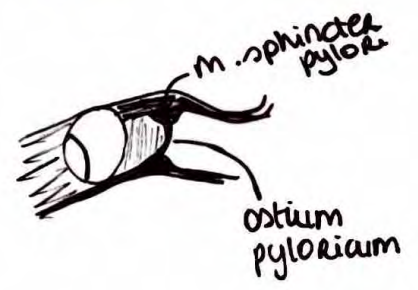
MAAG (Gaster, Venterculus)

Divine Lecis



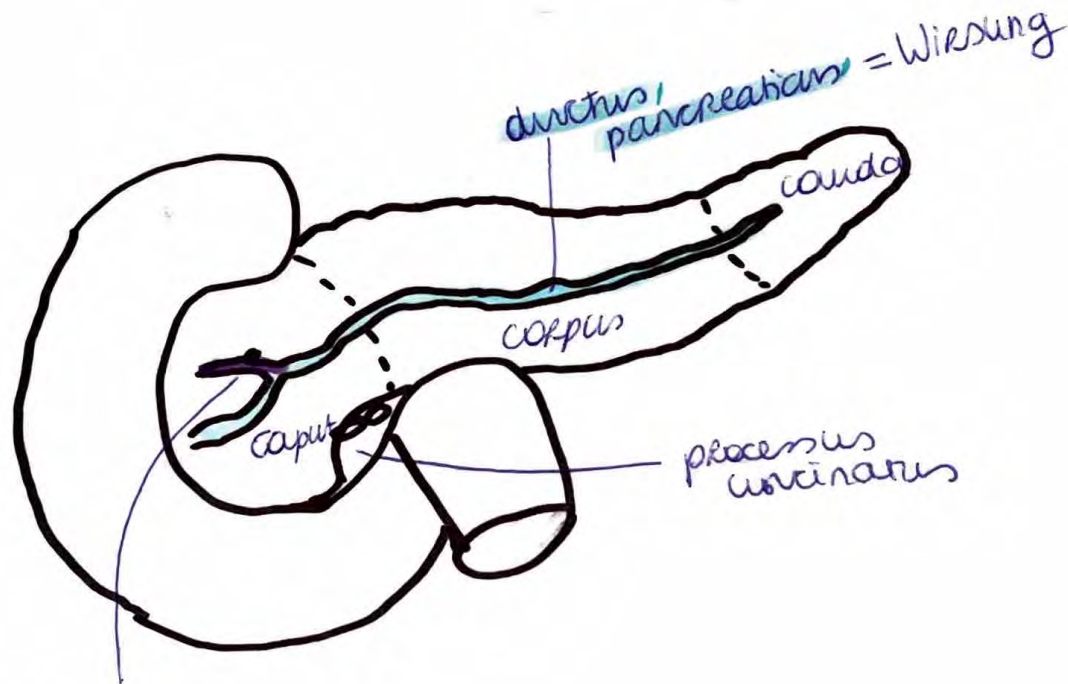
- = cardia
- = fundus (gastricus)
- = corpus (gastricum)
- = antrum (pyloricum)
- = canalis pyloricus
- = duodenum

◦ incisura angularis



Pancreas

= sec. retro



ductus
pancreaticus
accessorius
(Santorini)

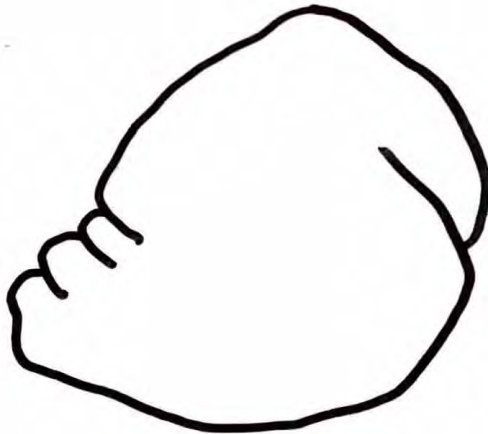
MILT = SPLEN = LIEN

= intra (geen meso?)


C9 - C11

C10 dwars erdoor

↳ costa



costaal zicht



visceraal zicht

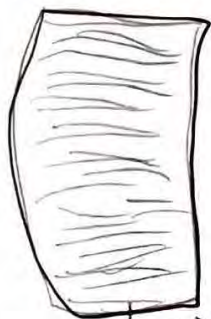■ = a. splenica

■ = v. splenica

miltkapsel
= tunica
fibrosa

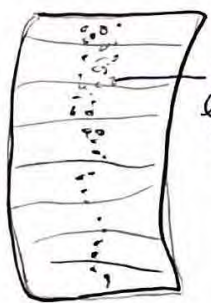Hilum
splenicum

microname
↑
Jejunum



Plicae circulares (v. Kerkring)

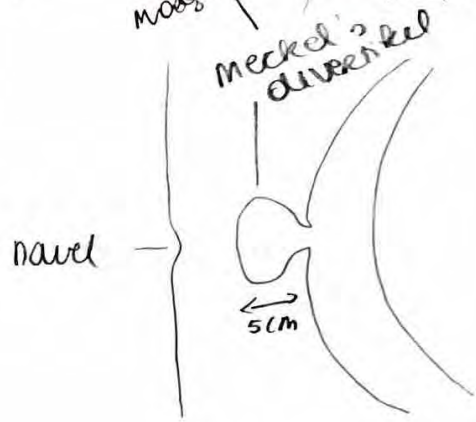
Ileum



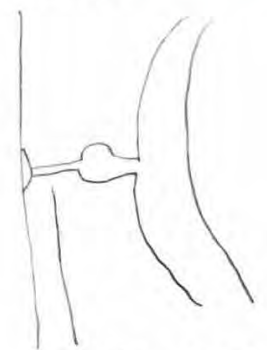
Folliculi lymphatici = plaatu Peyer = nodi lymphoidei aggregati

50% mooglykheid of soms alweer kleiner wepkel

Ileum Meckel's divertikel



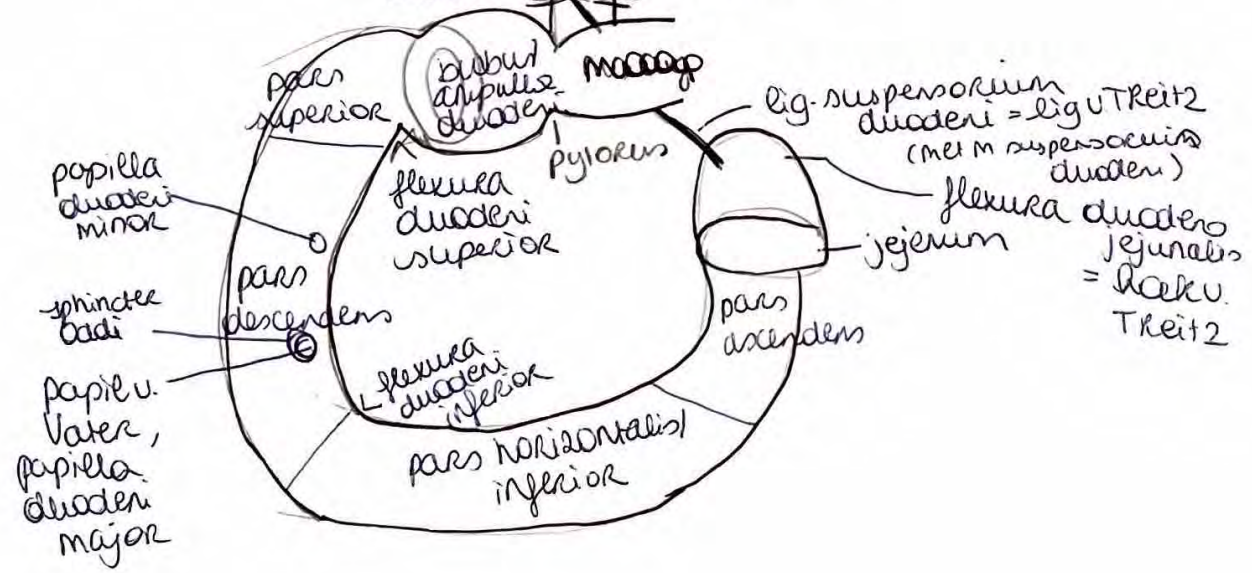+ kan nog verbonden zyn met navel via dun bindweefselmeng



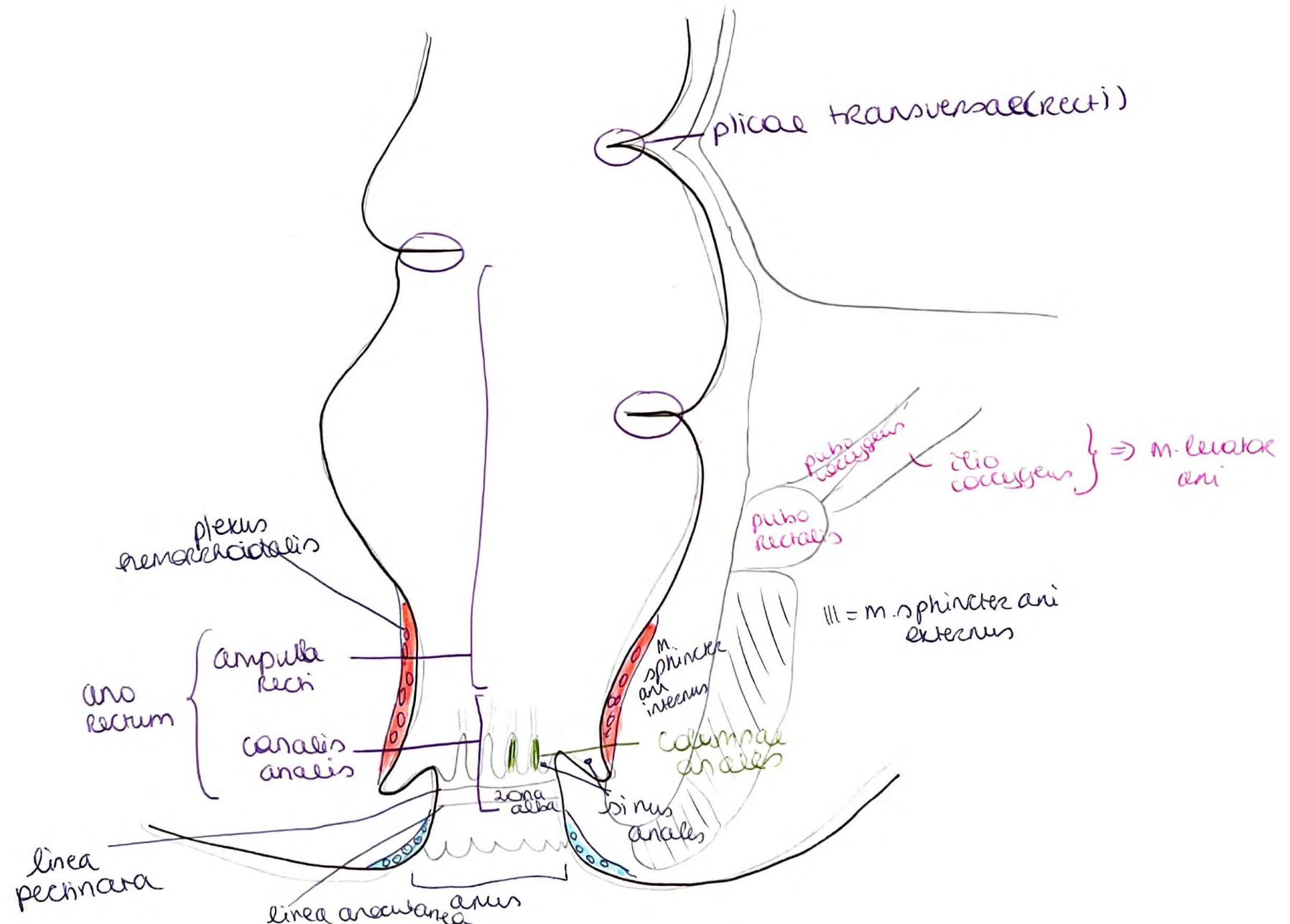
diaer zek gang

↓
verdwijnt na 3m zw. nrml

Duodenum = 12-vingerige darm



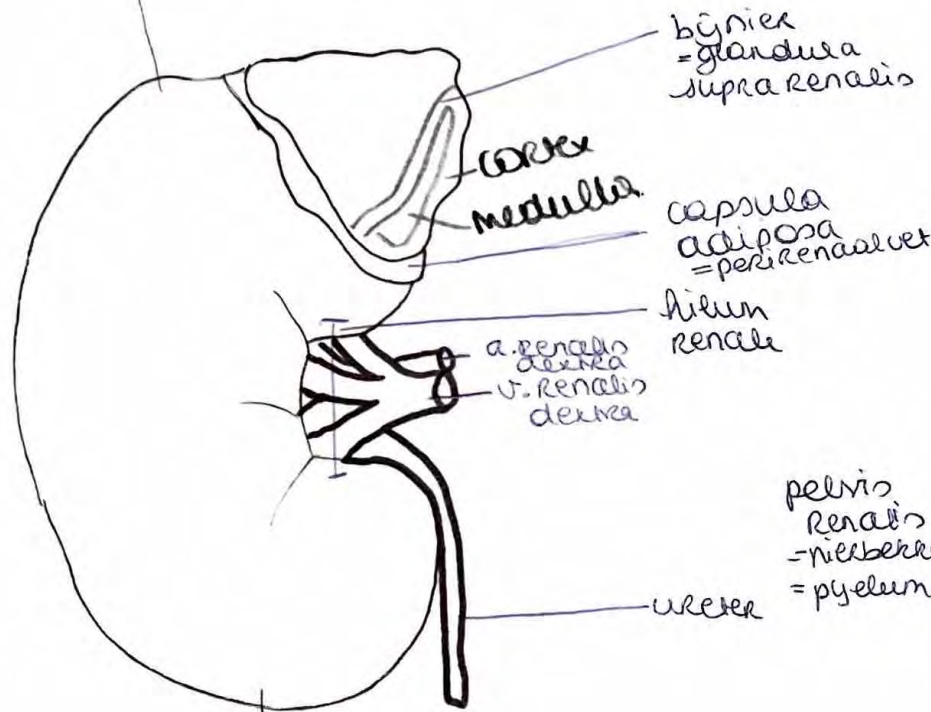
RECTUM = Enddarm



Rechter nier = Ren

↳ pararenale vet (retroperitoneaal vet)

extremitas (polus) superior = bovenpool



Ventraal

extremitas (polus) inferior = onderpool

bijnier = glandula supra renalis

Cortex medulla

capsula adiposa = perirenaalvet

hilum renale

a. renalis dextra
v. renalis dextra

ureter

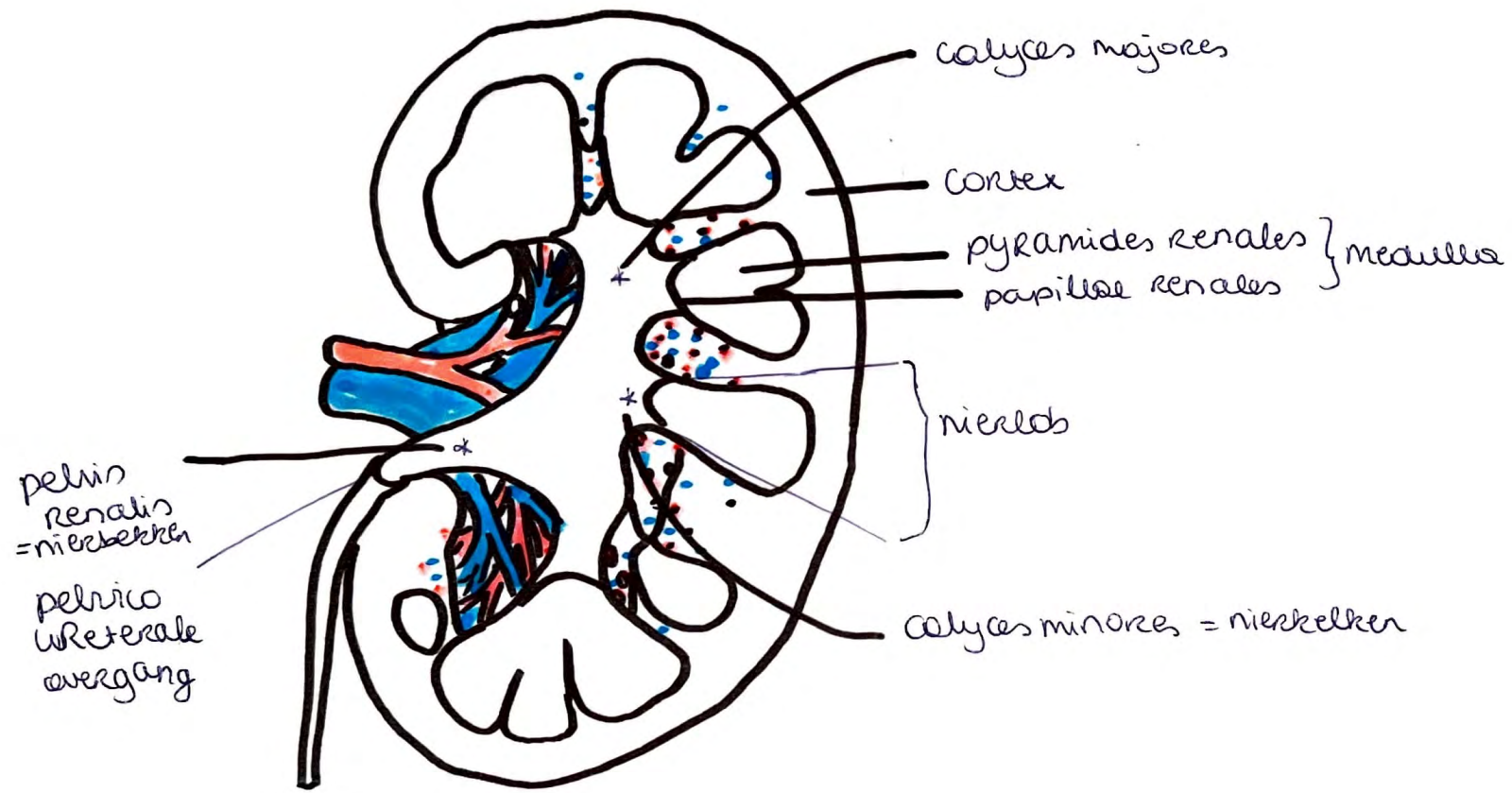
pelvis renalis = nierbekken = pyelum



cortex renalis

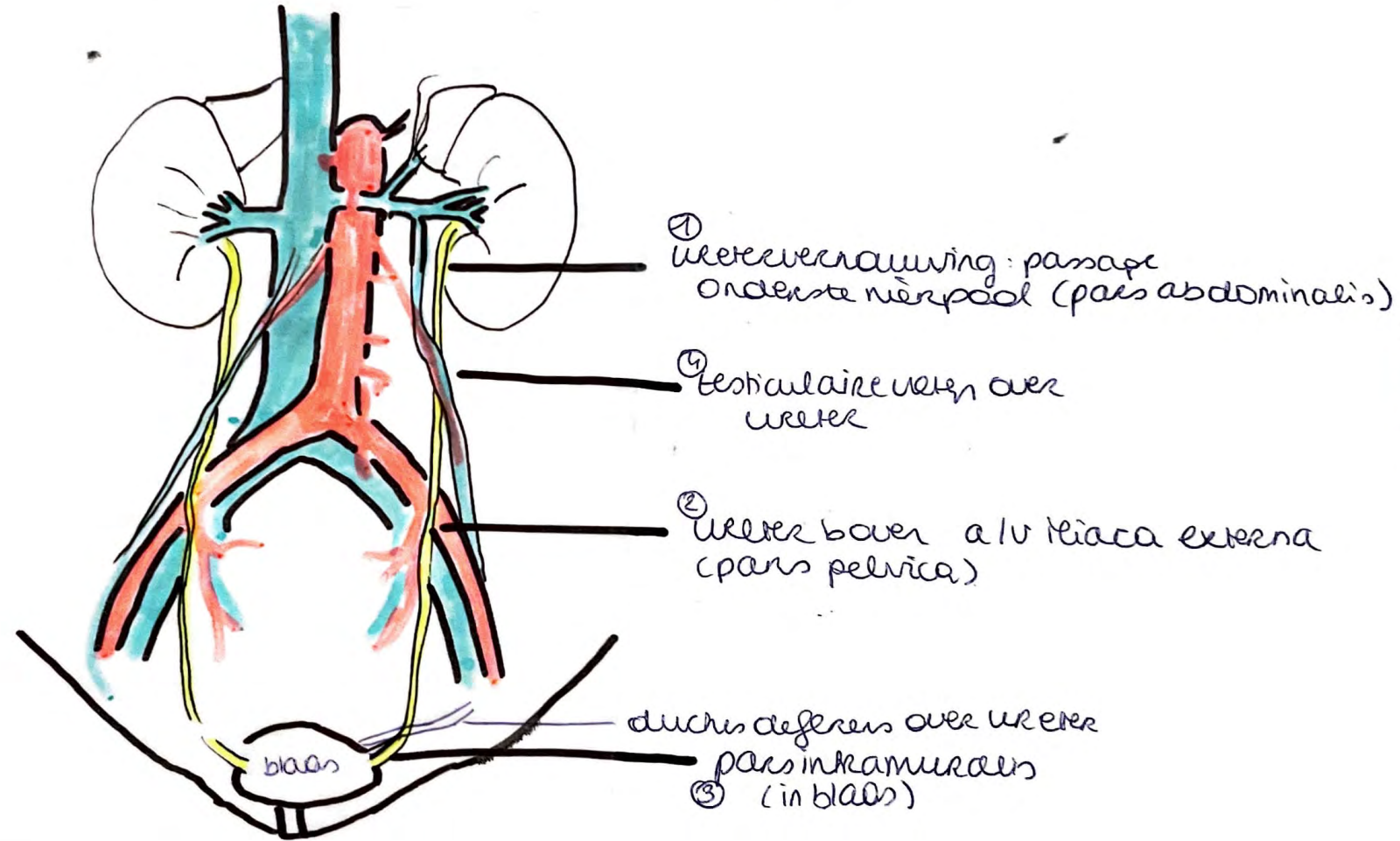
capsula fibrosa renis = nierkapsel

dorsaal



URETER


1-2-3 vernauwing
ert 4.



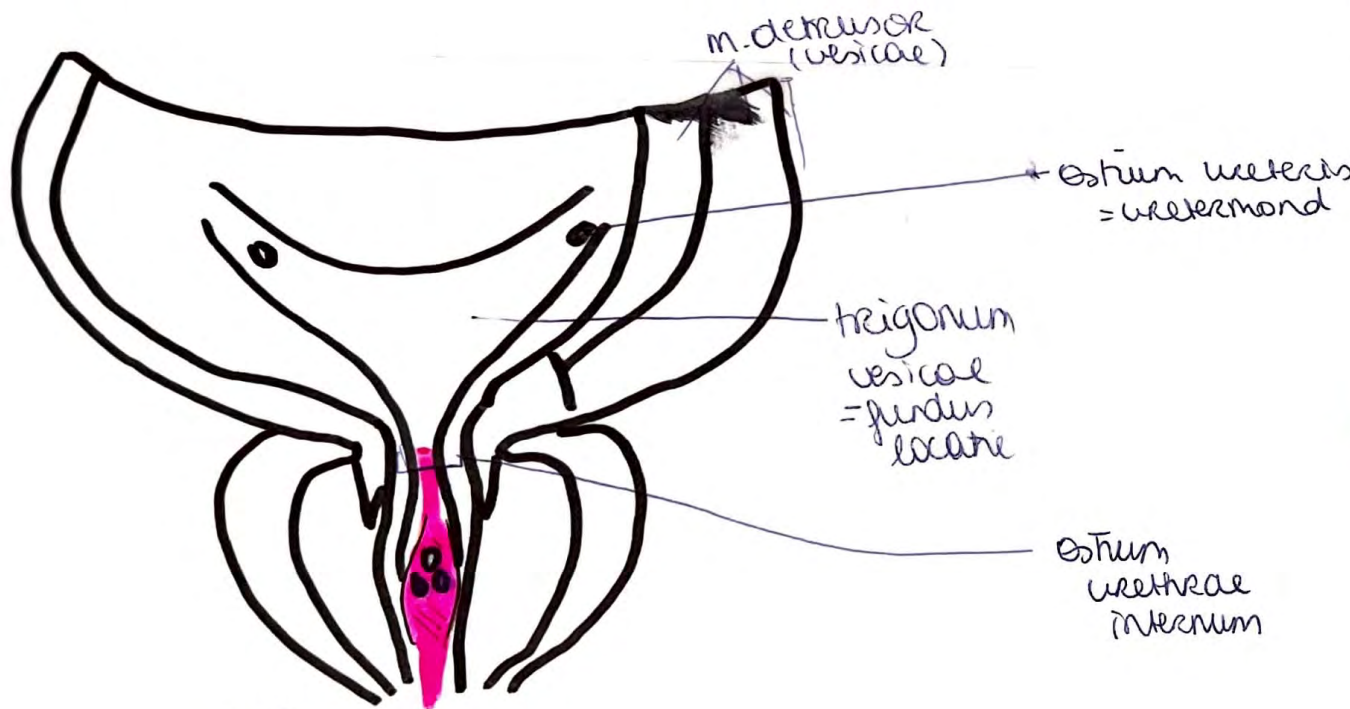

BLAAS

vesica urinaria

M

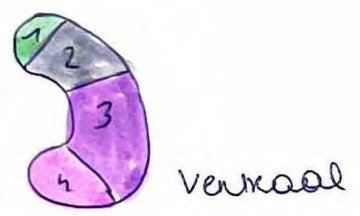

V



- III** = colliculus seminalis + uitmonding ductus ejaculatorii
- IV** = utricleus prostaticus

NIERSEGMENTEN



Ventraal



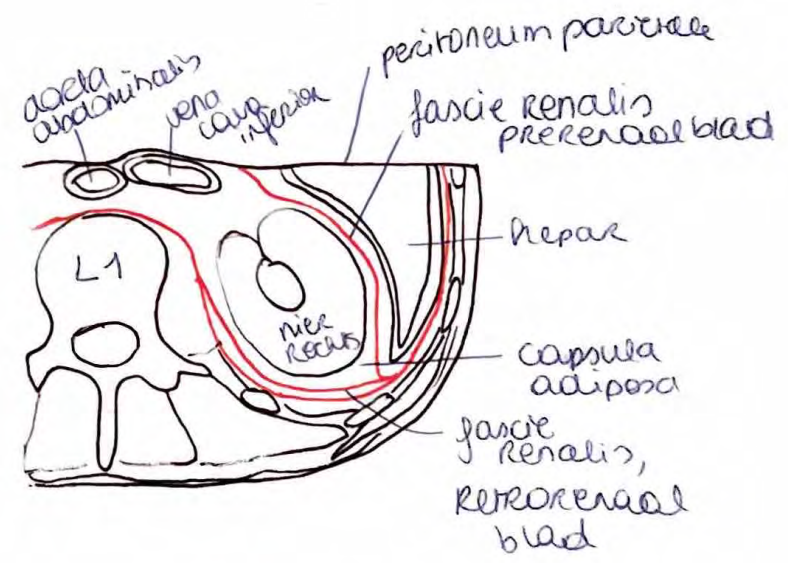
Dorsaal

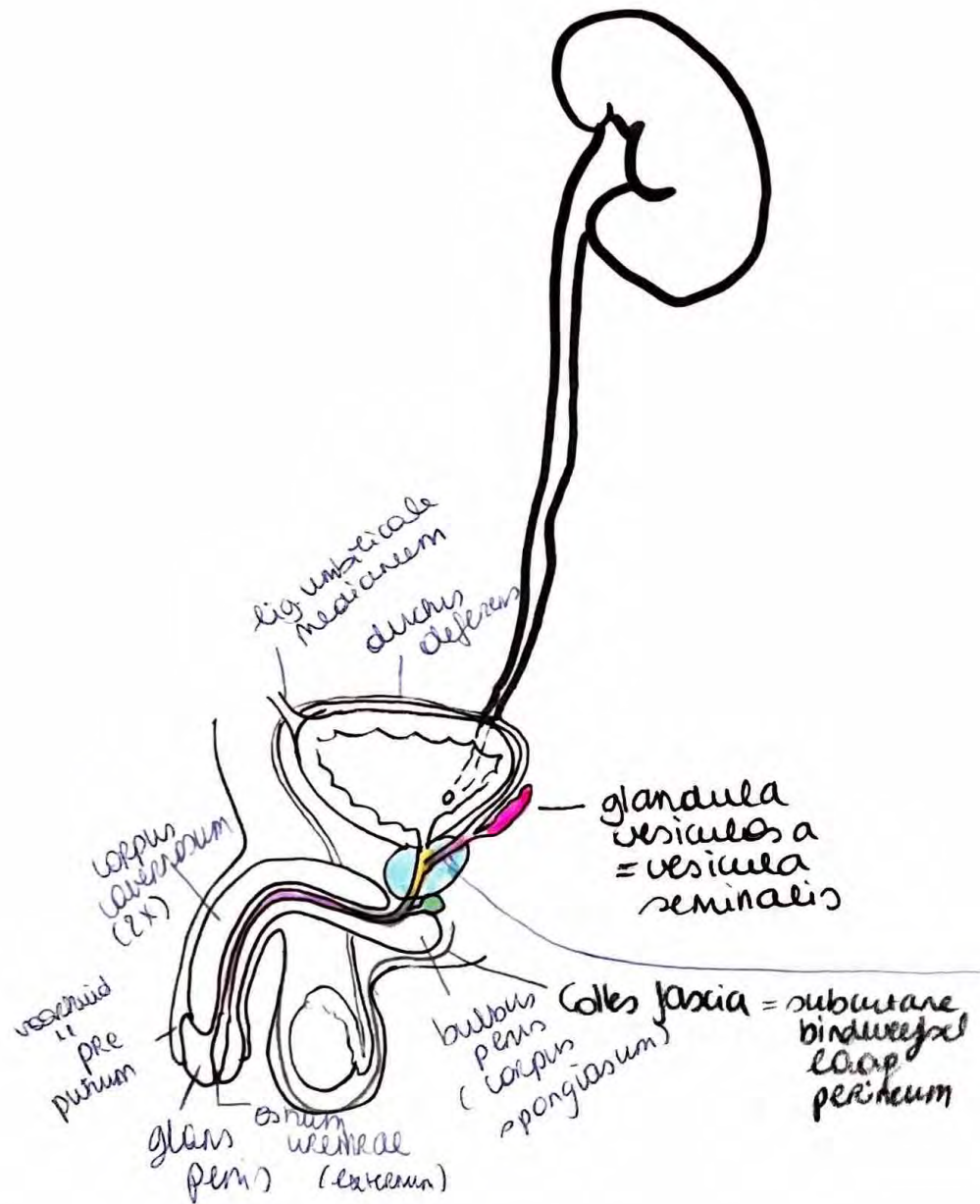


Lakraal

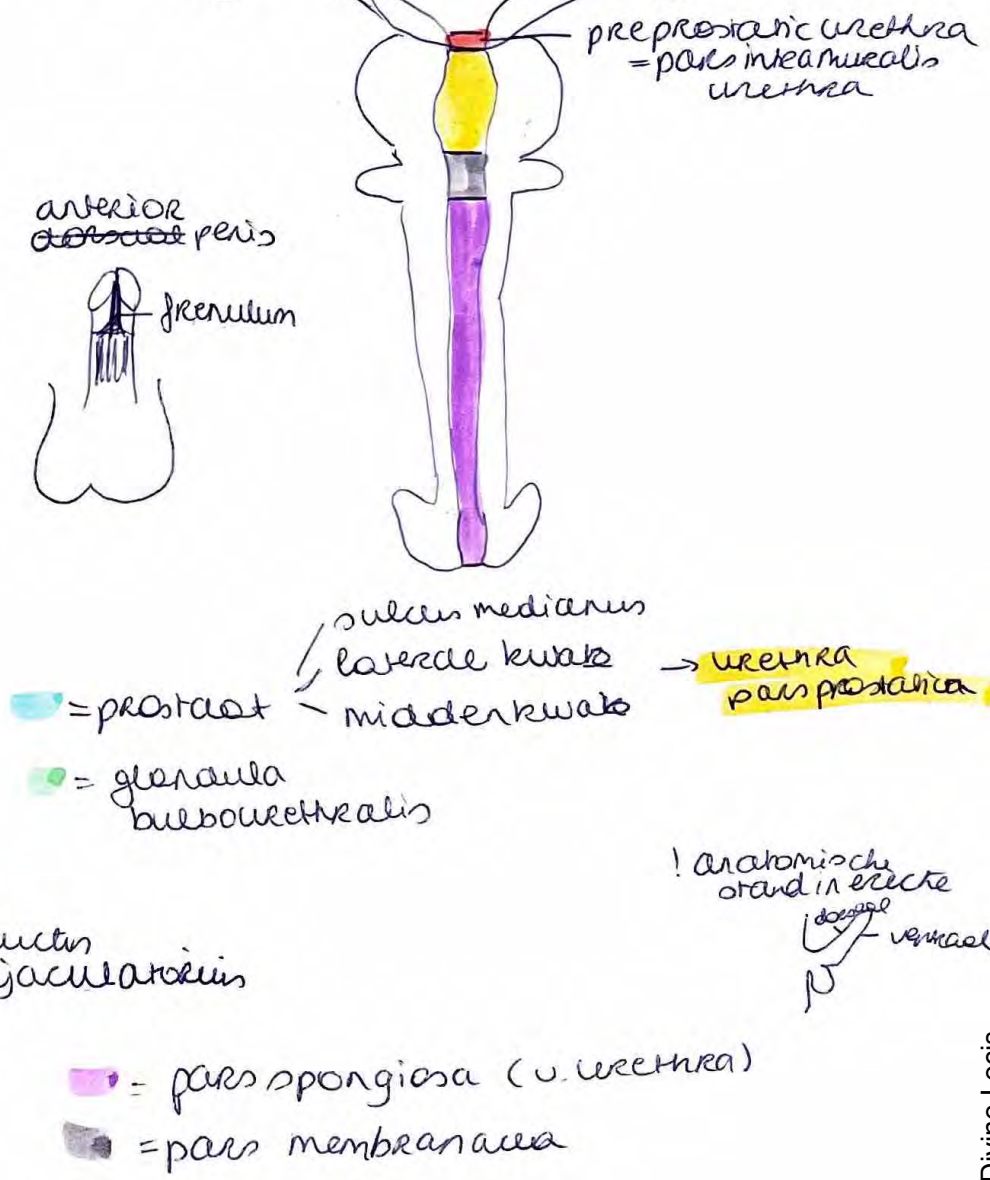
- 1. segmentum superius
- 2. segmentum anterius superius
- 3. anterius inferius
- 4. inferius
- 5. posterius

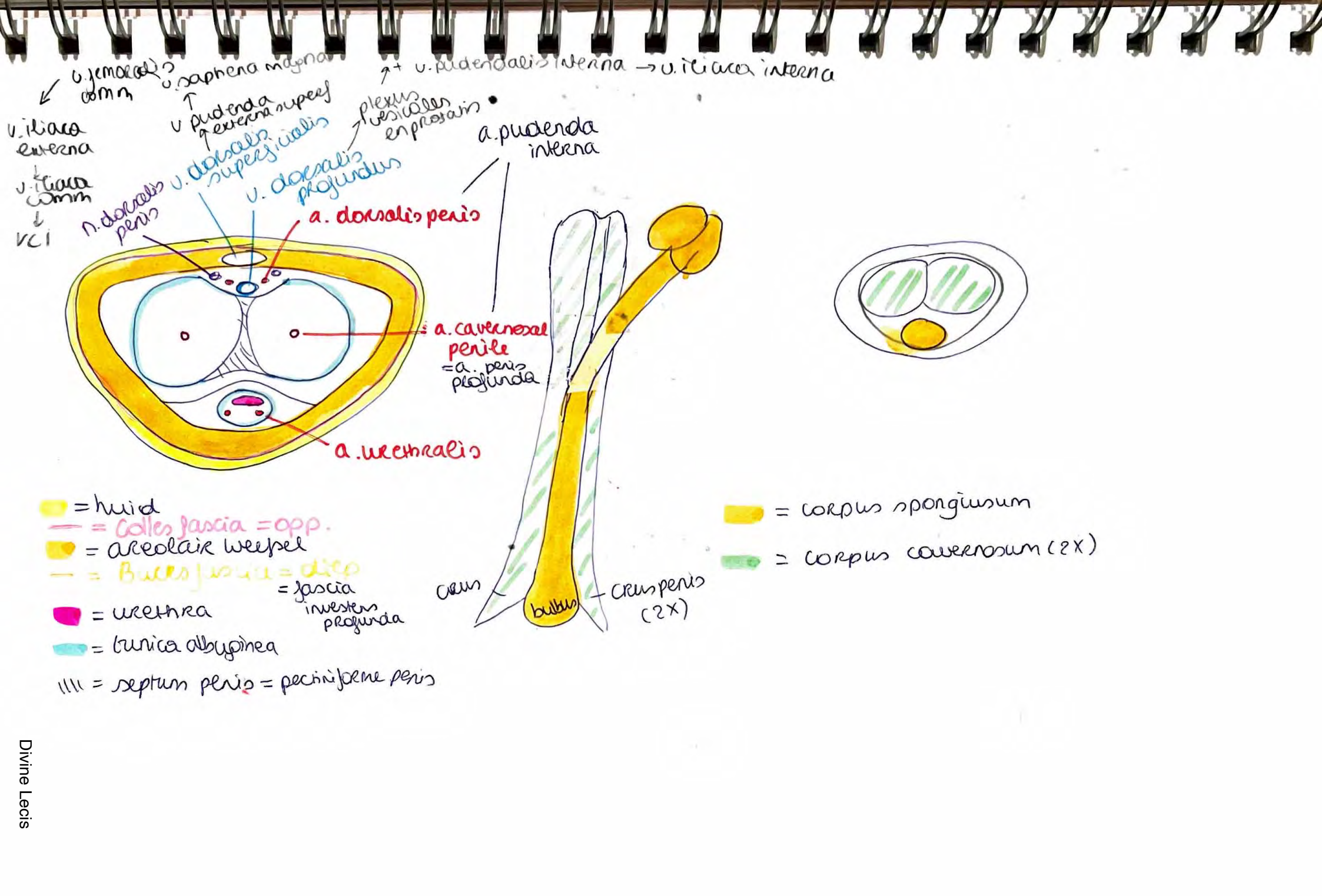
Fascia Renalis = fascia v. Gerota





Mannelijke geslachtsorgaan





v. femoralis → v. iliaca externa
 v. saphena magna → v. pudenda externa
 v. pudenda externa → plexus vesiculosus in prostratis
 v. pudenda interna → v. iliaca interna

v. iliaca externa
 v. iliaca communis
 v. cili
 n. dorsalis penis
 v. dorsalis superficialis
 v. dorsalis profundus

a. pudenda interna

a. dorsalis penis

a. cavernosal penile
 = a. penis profunda

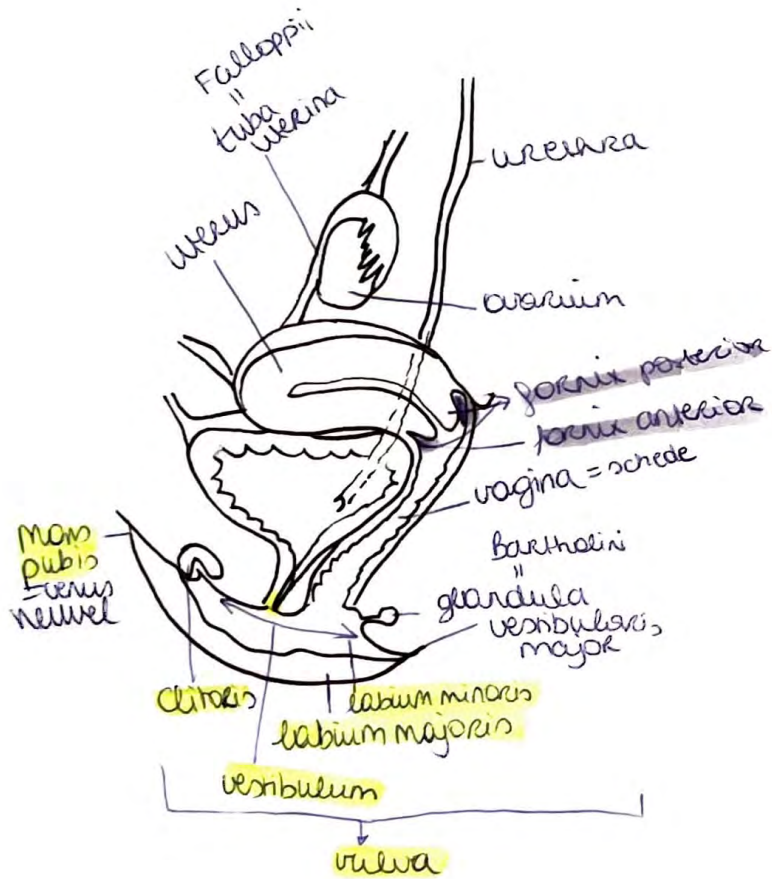
a. urethralis

- = huid
- = Colles fascia = opp.
- = areolaire weefsel
- = Buck's fascia = diep = fascia investens profunda
- = urethra
- = tunica albuginea
- ||| = septum penis = pectiniforme penis

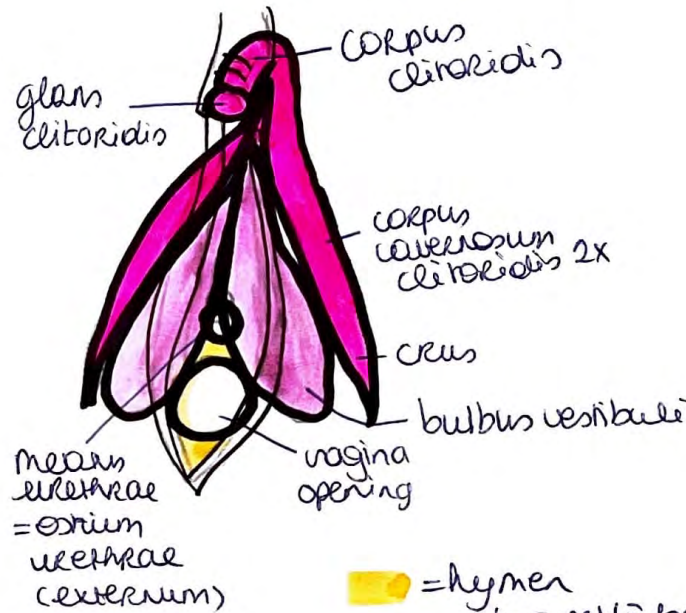
- = corpus spongiosum
- = corpus cavernosum (2x)

crus
 bulbos
 crus penis (2x)

VROUWLIJK GESLACHTS ORGAAN

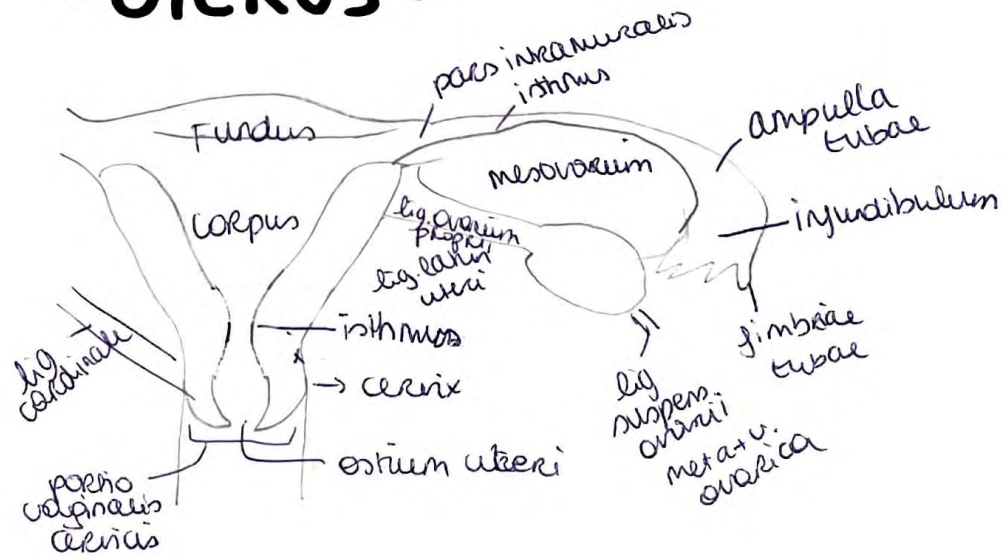


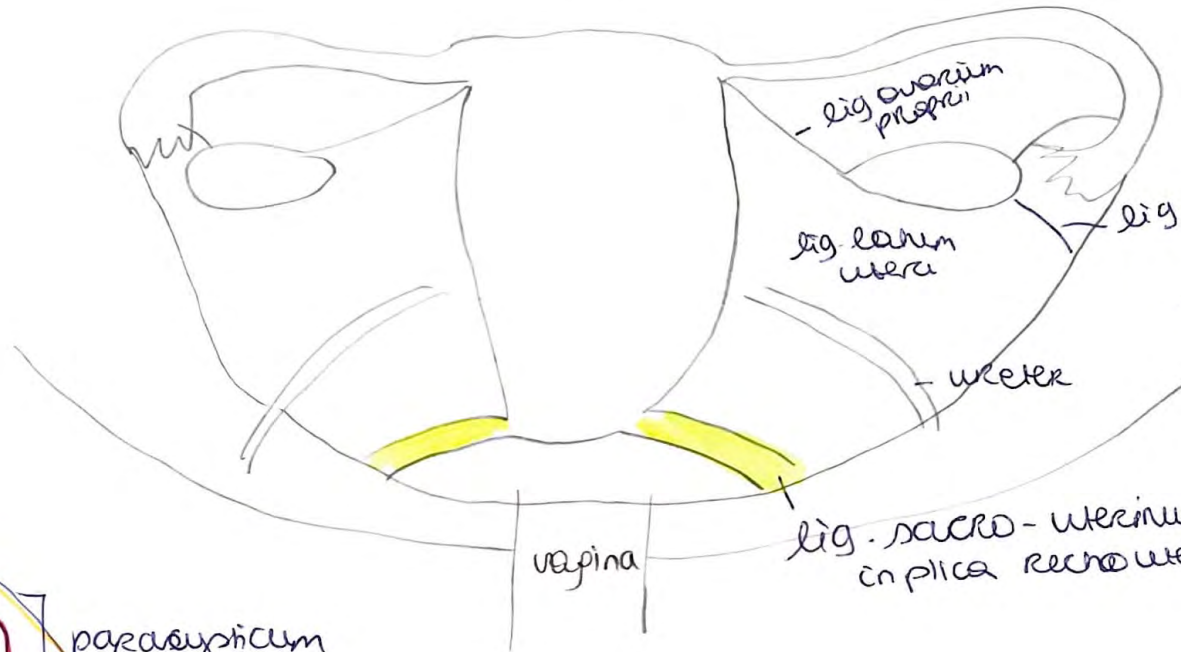
• CLITORIS •



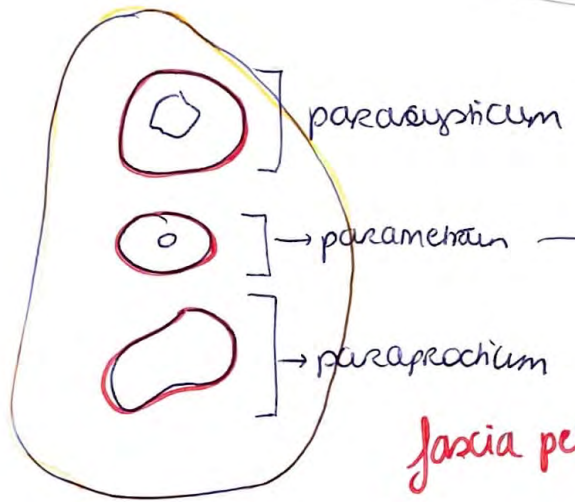
= hymen
 ↳ overblijfselen = cornuulae hymenales

• UTERUS •





lig. cardinale
= transversum cervicis
in cervix uteri → achterwaarts



parasymplicum
parametrium
paraprochium

parametrium
= bindweefselruimte in
2 peritoneale blaasjes

fascia pelvis visceralis

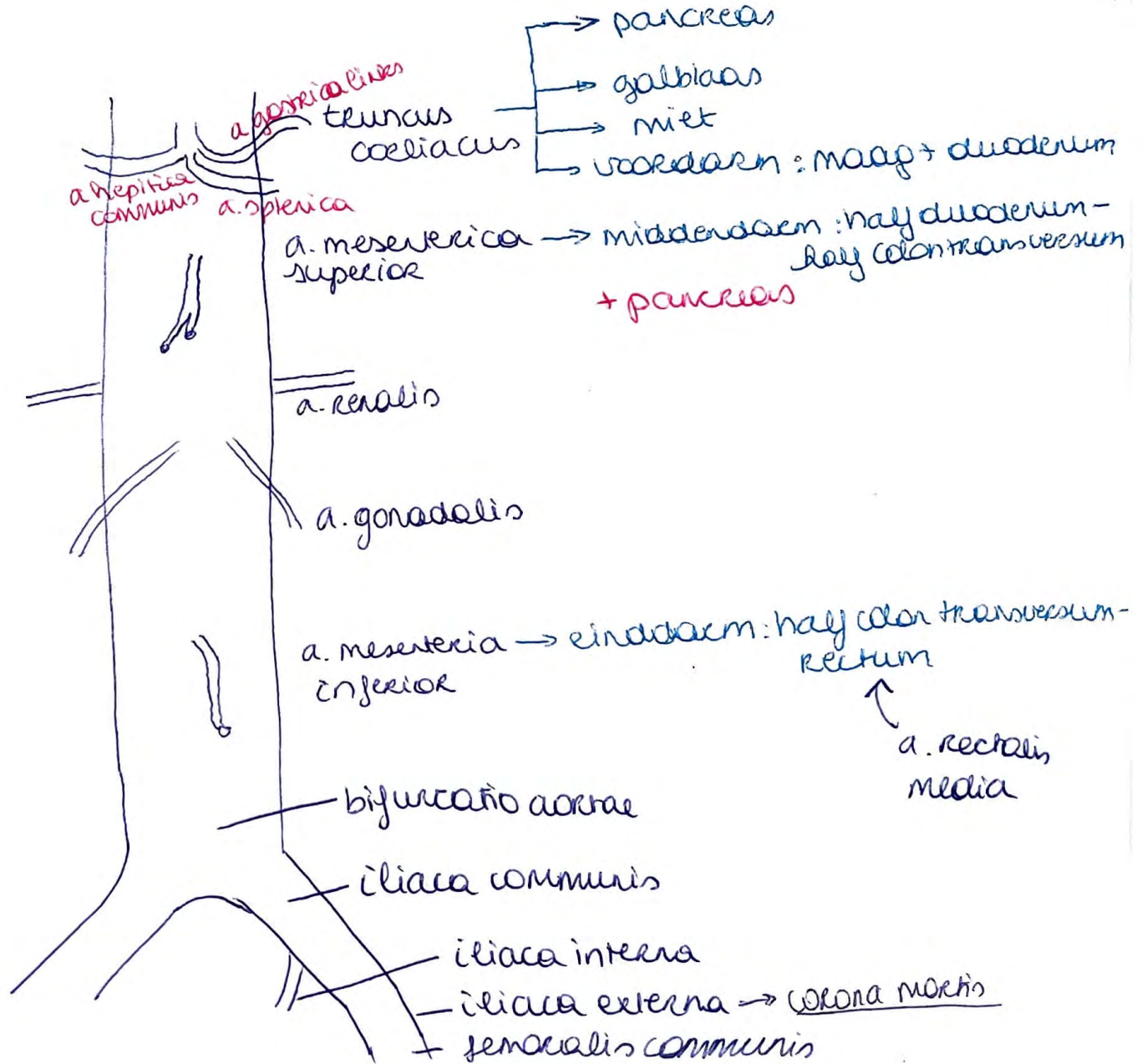
fascia pelvis parietalis

Corona Martii: anastomose

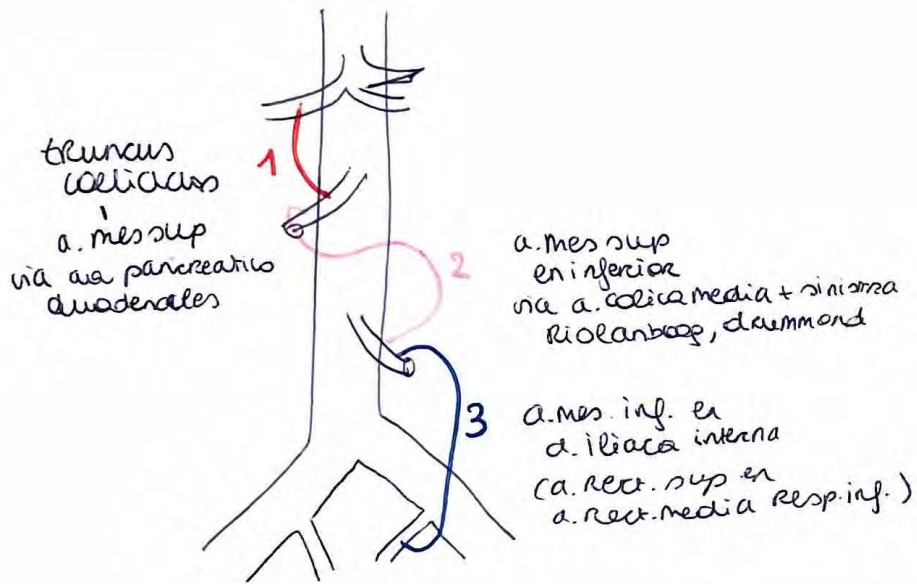
a. iliaca externa /
a. epigastrica inferior prof

en a. obturator
⇒ belangrijk bij OK.

= v. iliaca externa
+ v. obturatoria

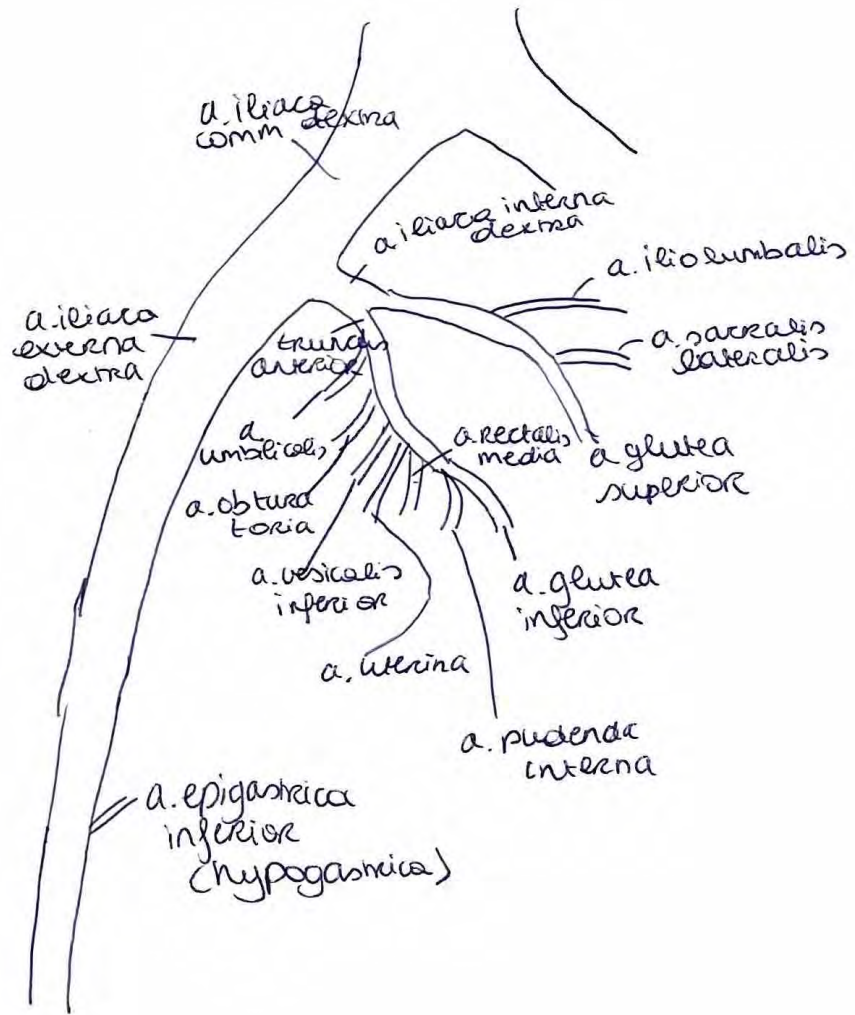


Anastomosen



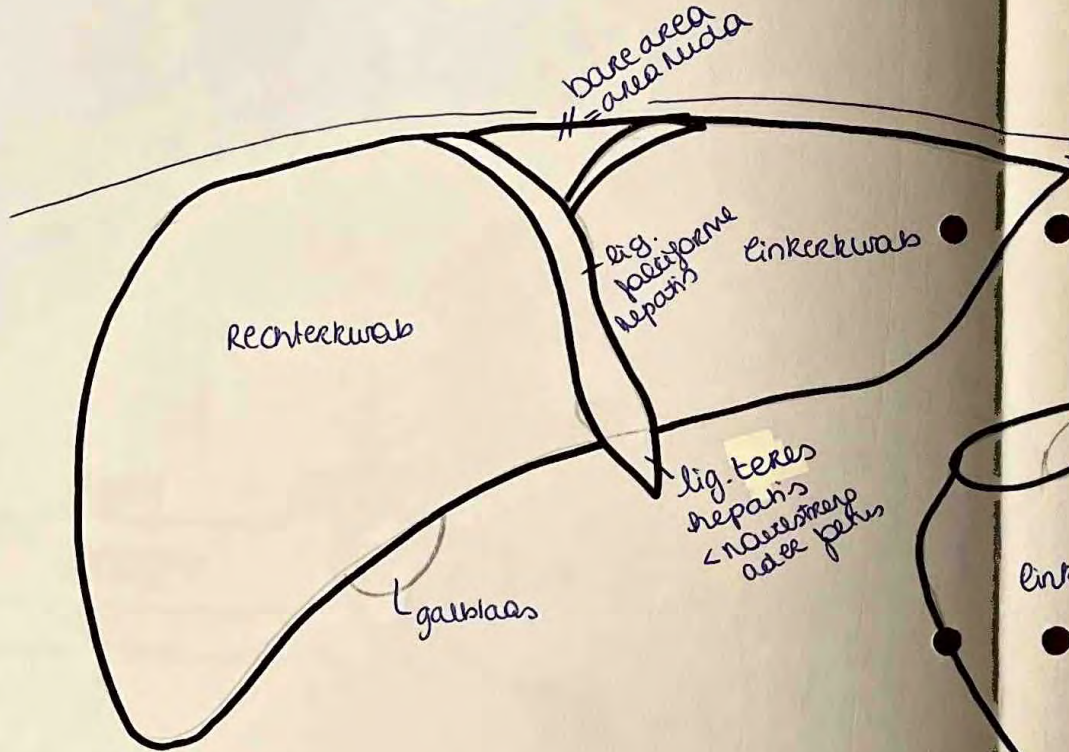
a. mes. sup
 et inferior
 via a. colica media + sinistra
 Riolarbaag, drummond

a. mes. inf. ex
 d. iliaca interna
 (a. rect. sup. et
 a. rect. media resp. inf.)



LEVER

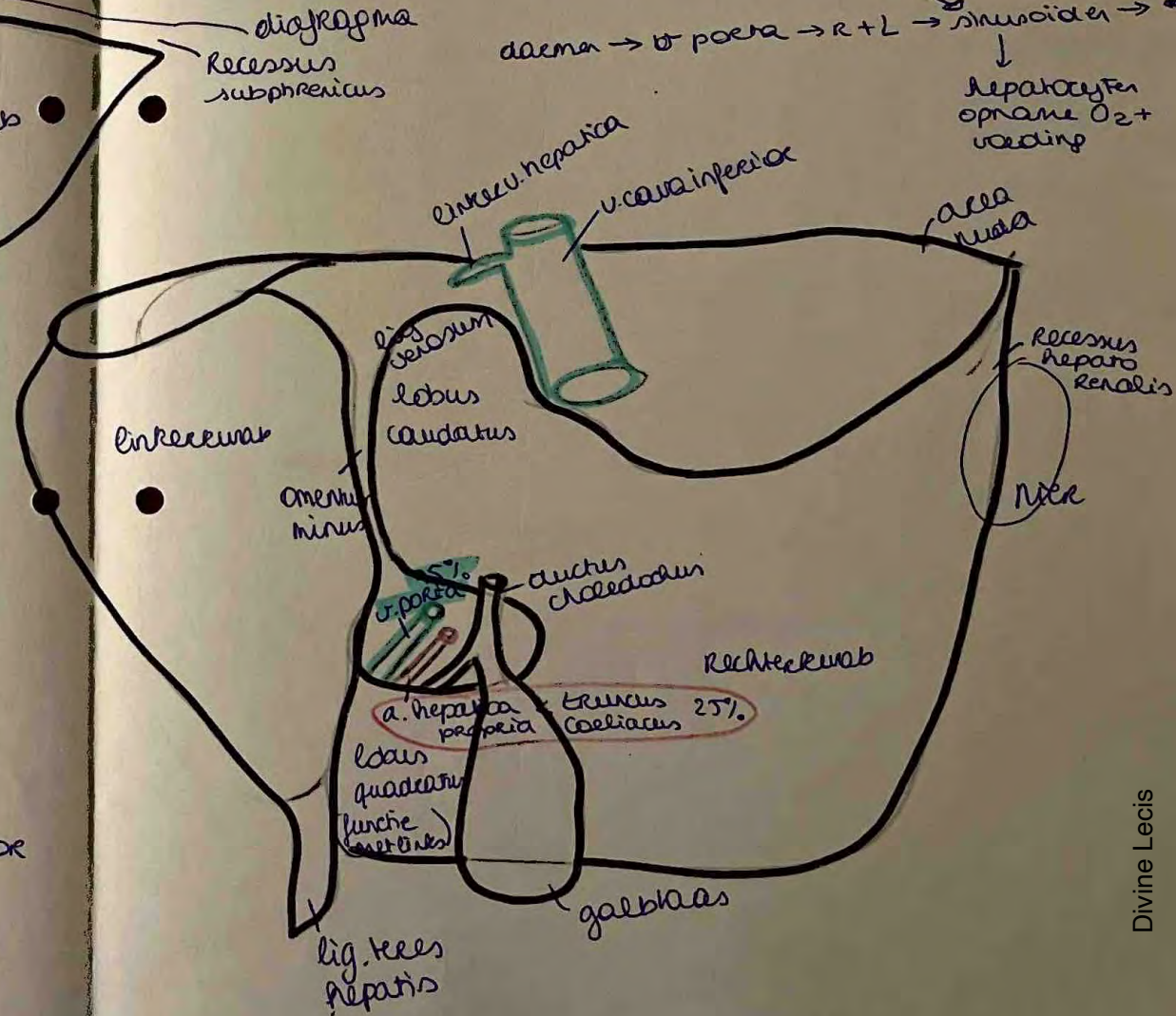

- regulering stofwisseling = samenstelling bloed
 - allemaat verwijderen / tekort aanregieren
 - afval / gif verwijderen (cytotoxisch p. 50)
 - vit. oplosbaar opname (A, D, K, E, g. zee)
 - aanpassen hormonen
- hematologische regulering = resten verwijderend met Kupffercellen
- galvorming

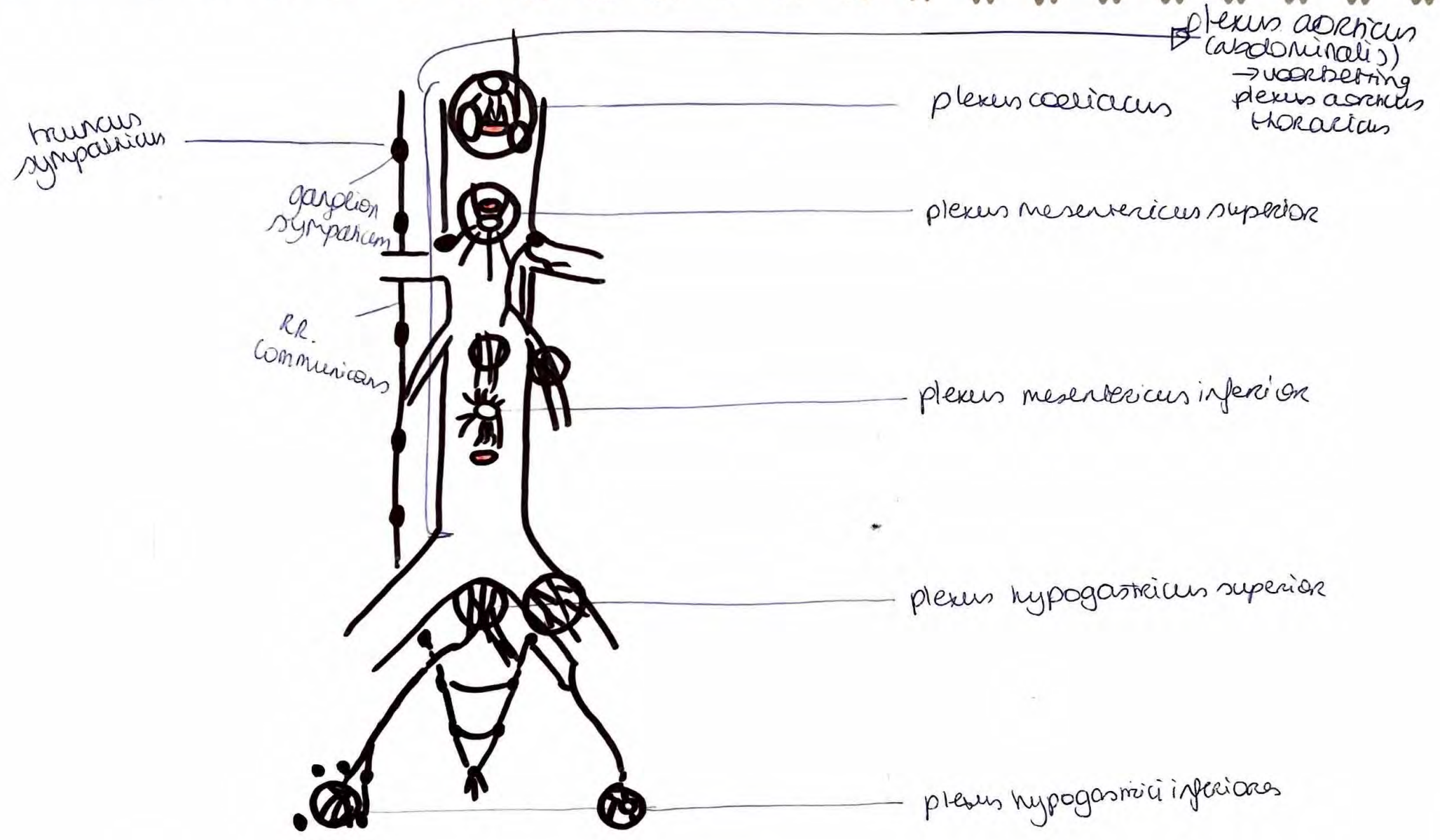


- lever-maag: lig. hepatogastrica
- lever-duodenum: lig. hepatoduodenalis
- diafr- lever: lig. triangulare sinistra + dextra
lig. coronarium anterior + posterior

bloed

- * sinusoiden → centrale vene → subhepatische vene → vv. hepaticae → v. cava inferior.
- truncus coeliacus → a. hepatica → linker + rechter





plexus lumbalis

• n. iliohypogastricus → S: superior gluteal regio
regio supra pubica

M: m. obliquus internus.

• n. ilioinguinalis: S: proximaal mediale dij
mons pubis,
labium majus, clitoris
antrum scrothum + clitoris

M: m. obliquus internus
m. transversus abd.

• n. cutaneus lateralis femoris: huid anterolateraal dij

• n. genitofemoralis: S: boven dij regio
n: anterior scrothum huid
v: mons pubis, labia majora

M: m. m. cremaster

• n. femoralis: S: anteromediale dij, mediaal beenkracht
M: flexor heup, extensor knie

• n. obturator: S: proximaal mediale dij,
art. coxae, art. genu
M: m. adductor longus, brevis
m. gracilis
m. obturatorius externus

Plexus Sacralis

- n. ischiadicus : s. achterkant dij, lateraal + post been, dorsum + zool voet
M: posterior dij spieren ~~en~~ been ant + post + lateraal, voetspieren
- n. pudendus : huid, organen ~~en~~ spieren perineum en externe genitalia
- n. gluteus superior: m. tensor fasciae latae
m. gluteus medius, gluteus minimus
- n. gluteus inferior: m. gluteus maximus
- n. cutaneus femoris posterior : s: bispleet
superomedial dij
externe genitalia
huid posterior dij
fossa poplitea, proximale regio posterior been

