

Autonome Zenuwstelsel Schematisch Opgebouwd

Paul Gobée, dept. Anatomy & Embryology,
LUMC

license CC BY NC SA



v5, Dec. 2024

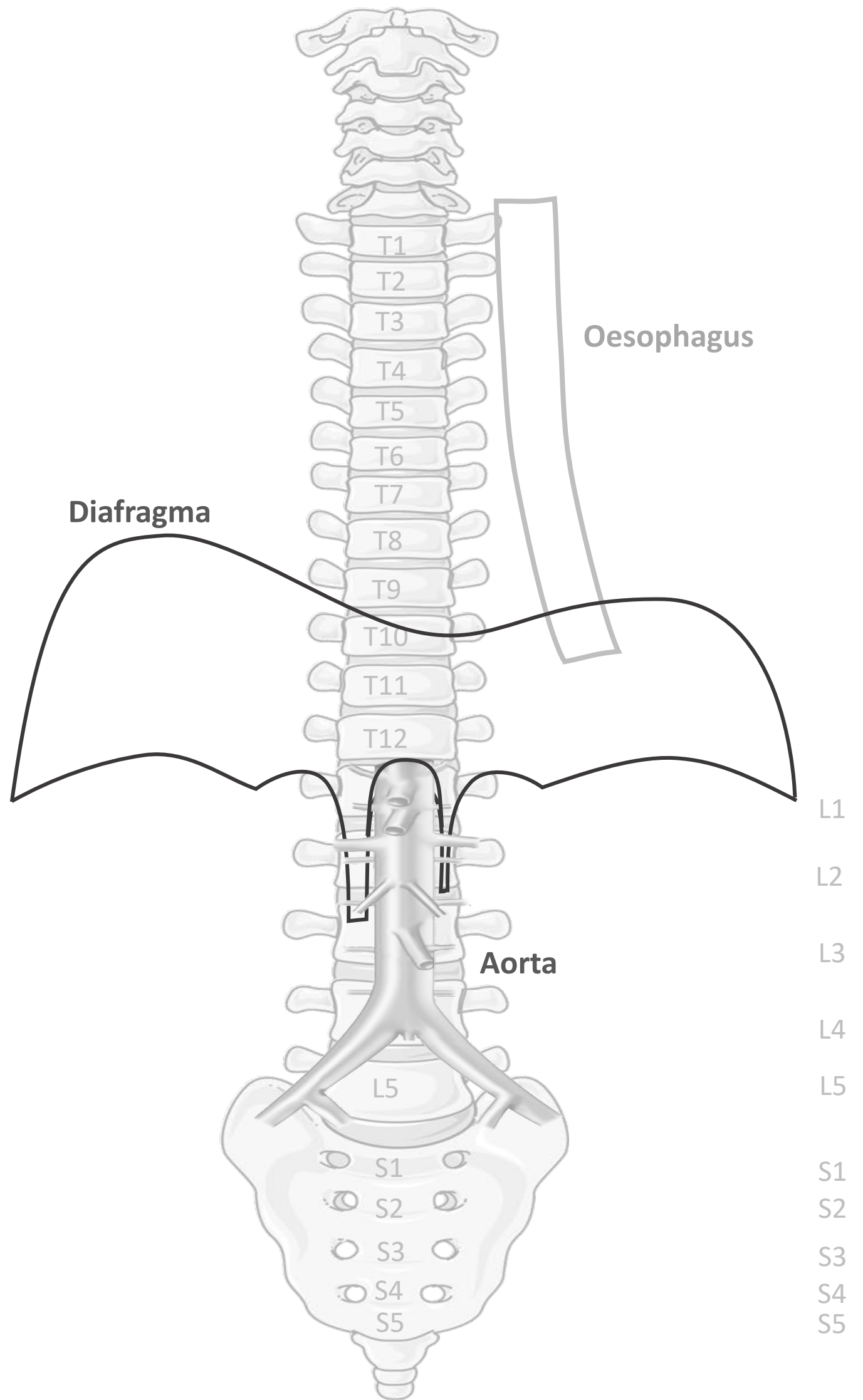
Zenuwstelsel in 5 onderdelen en 3 verbindingen

Onderdelen

1. Spinale zenuwen - (overwegend) **Somatisch**
2. Paravertebraal (truncus sympathicus)- **Sympathisch**
3. Prevertebraal/ preaortaal - (overwegend) **Sympathisch**
4. Nn. vagi - **Parasympathisch**
5. Sacraal - **Parasympathisch**

Verbindingen

1. Rami communicans **Sympathisch**
2. Splanchnische zenuwen **Sympathisch**
3. Pelviene splanchnische zenuwen **Parasympathisch**



Zenuwstelsel

5 onderdelen

Onderdelen

Somatisch

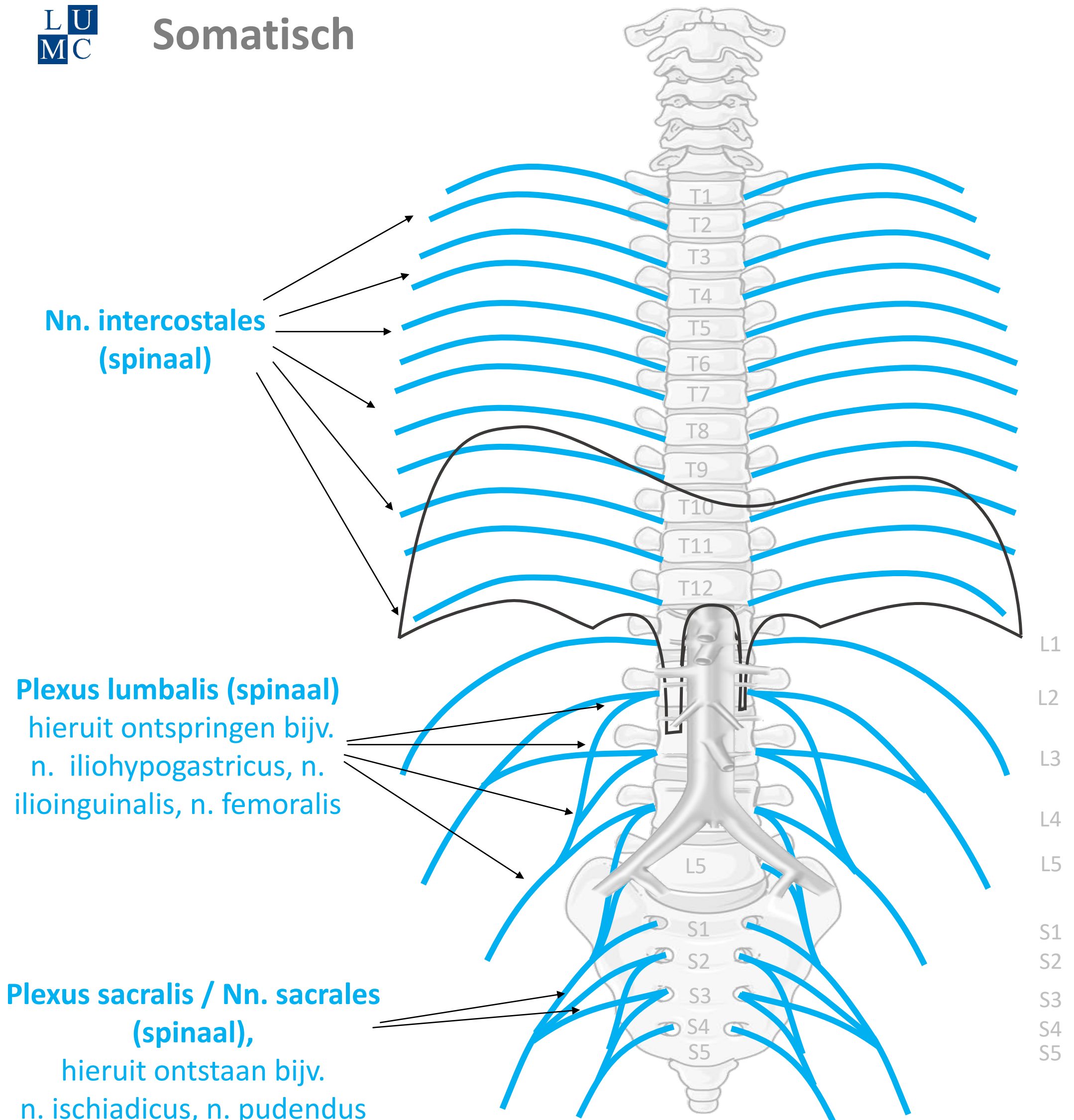
1. Spinale zenuwen

Sympathisch

2. Paravertebraal (truncus sympathicus)
3. Prevertebraal/ preaortaal

Parasympathisch

4. Nn. vagi
5. Sacraal



By Paul Gobée, dept. Anatomy & Embryology, LUMC license CC BY NC SA

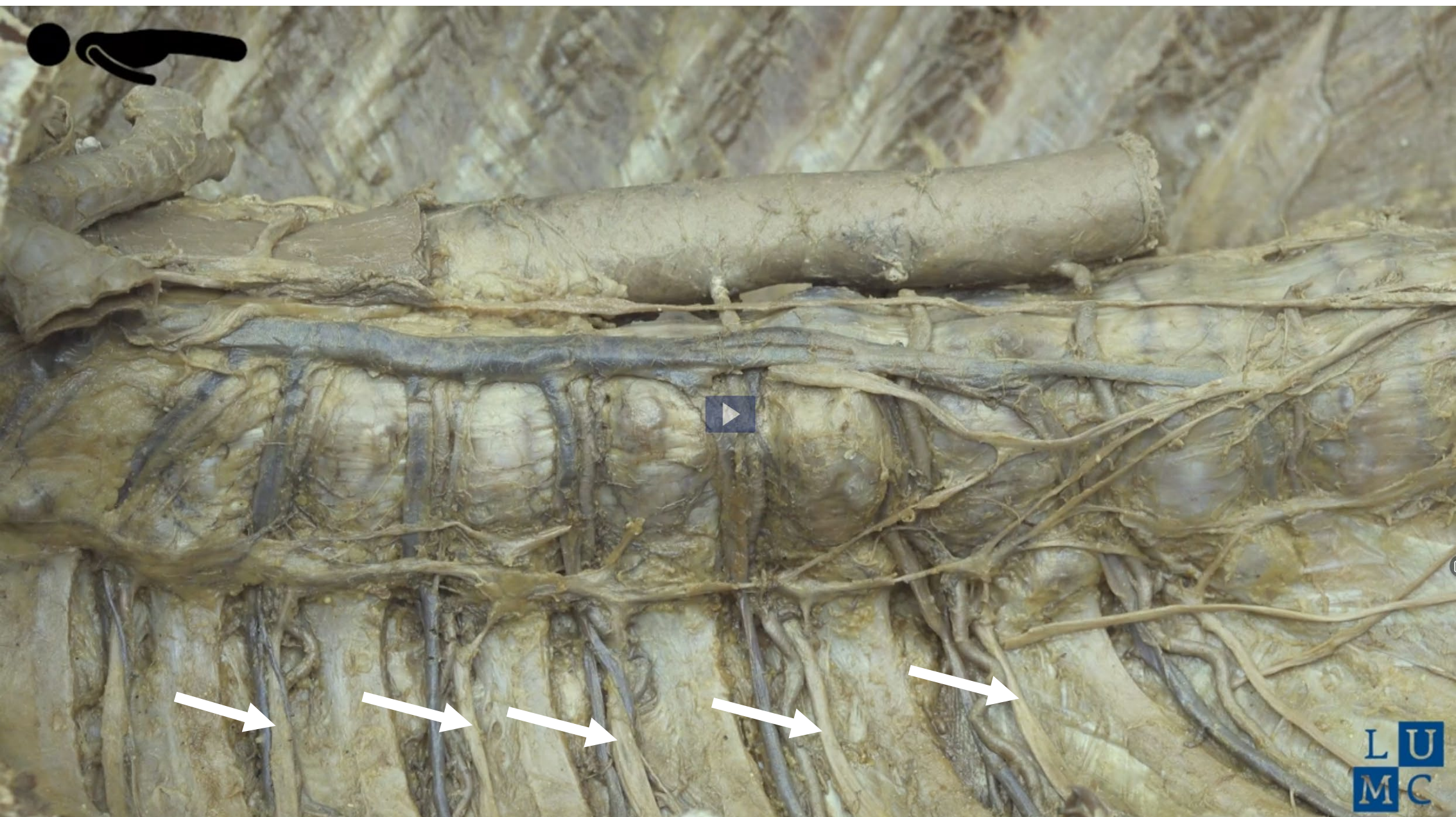
Bronnen: Gray's Anatomy 41st ed., Moore K et al, Clin. Oriented Anatomy, 8th ed.

"Servier - Drawing Vertebral column anterior view - no labels" by Servier Medical Art, license: CC BY

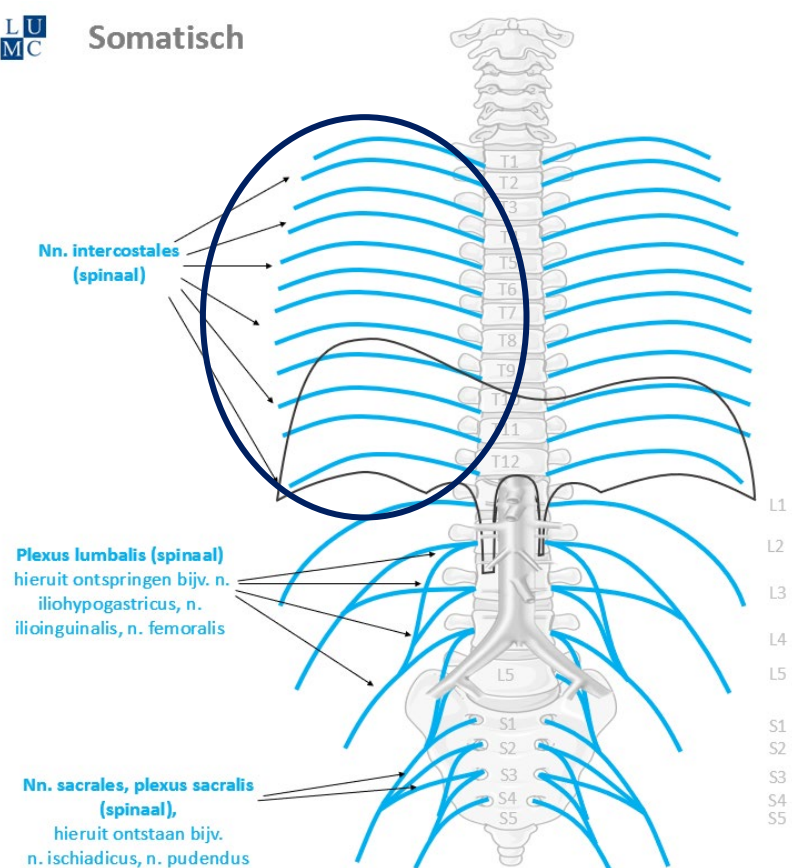
"Branches of the abdominal aorta - English labels" by Open Learning Initiative, license: CC BY-NC-SA



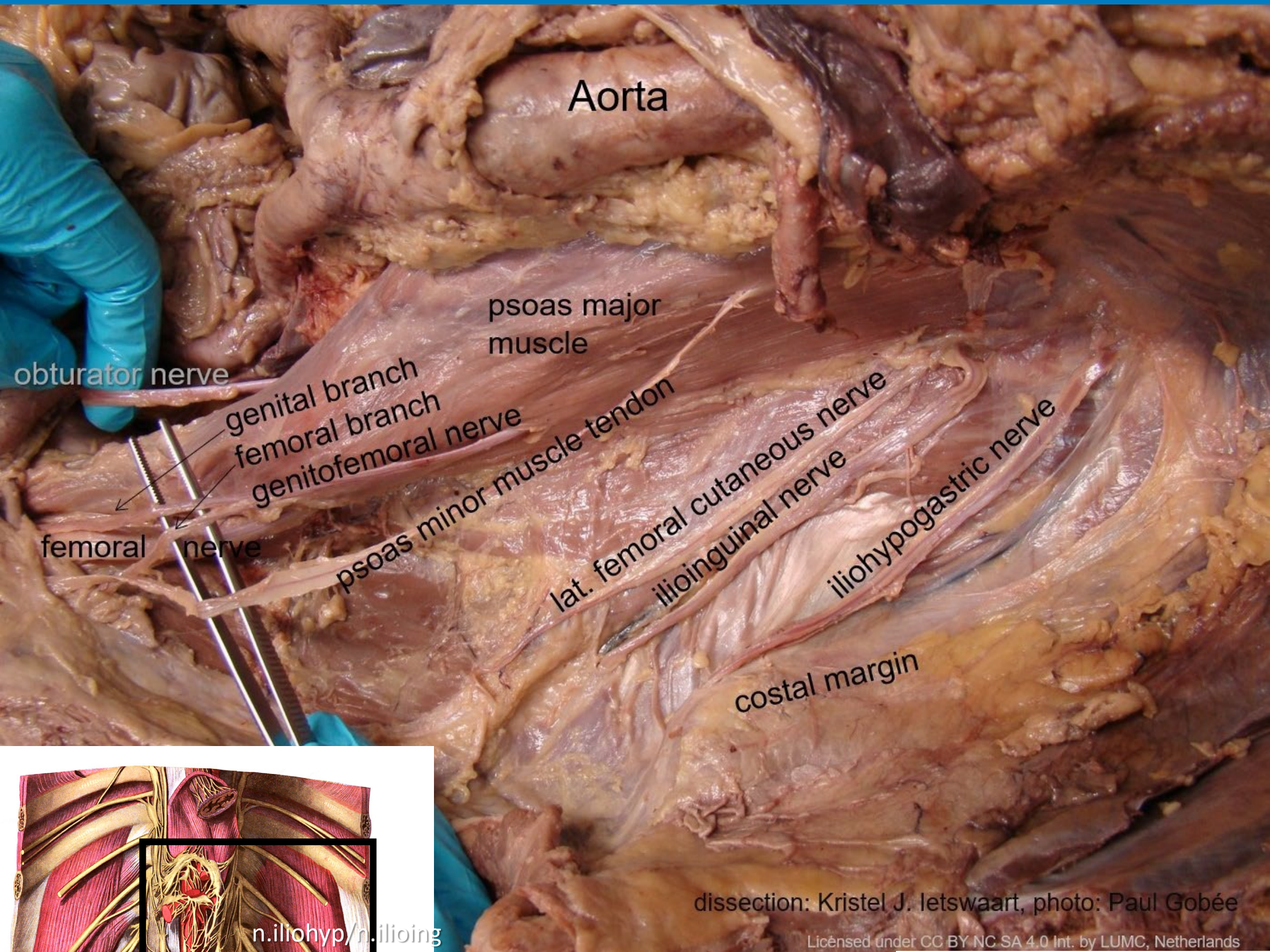
Nn. intercostales



LUMC Somatisch



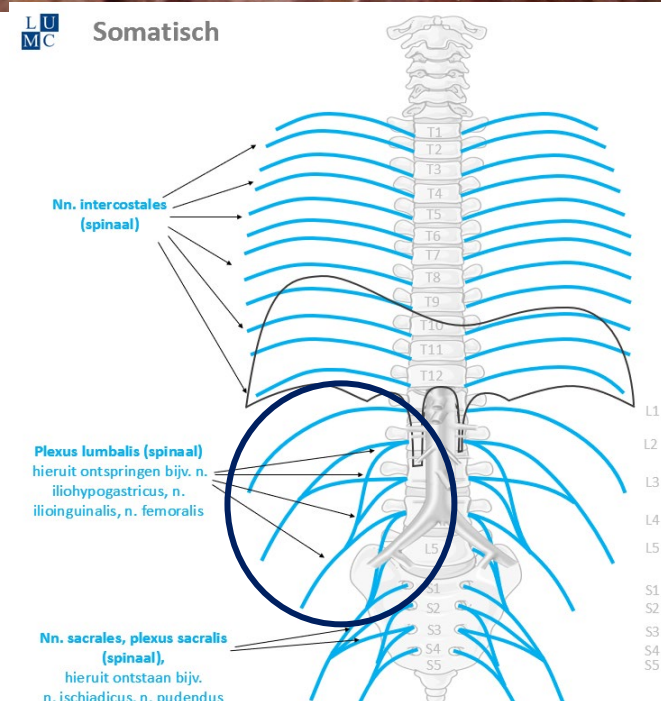
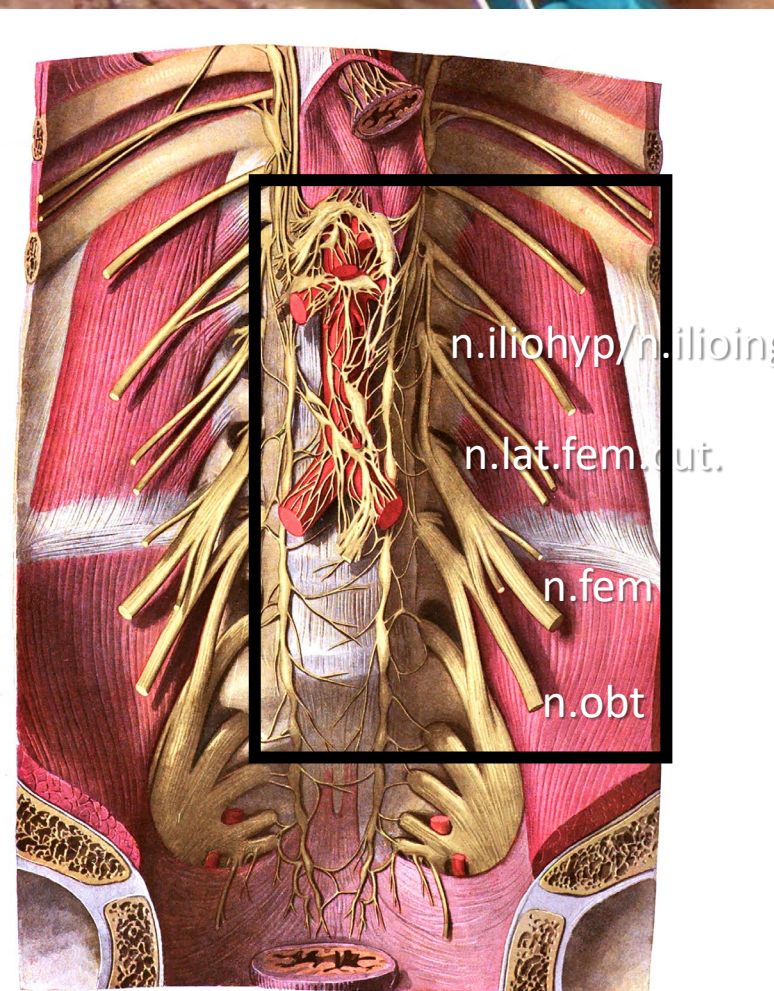
Spinale zenuwen uit plexus lumbalis



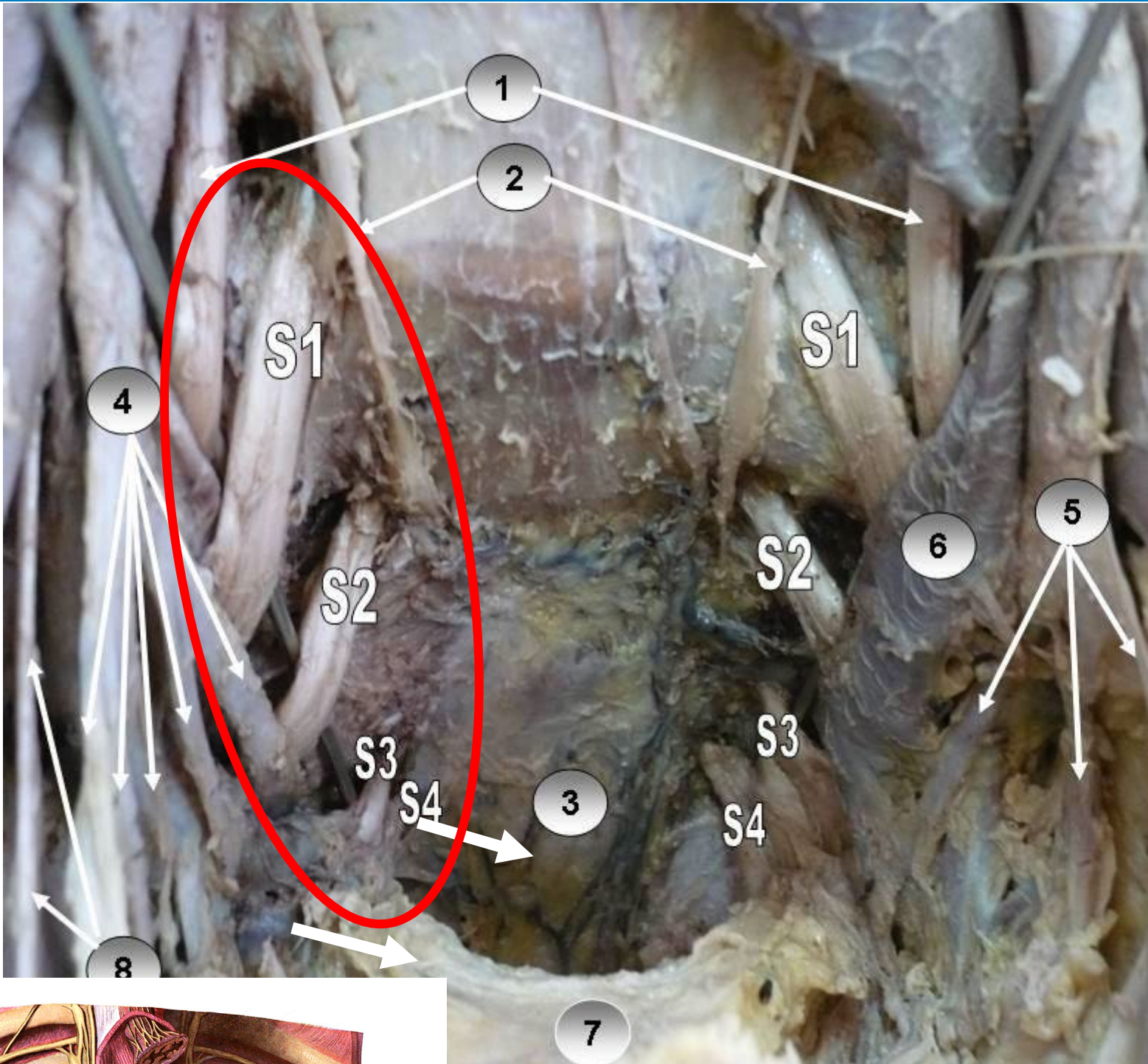
dissection: Kristel J. Ietswaart, photo: Paul Gobée

Licensed under CC BY-NC-SA 4.0 Int. by LUMC, Netherlands

"Leiden - Photo Nerves of posterior abdominal wall (dissection) - English labels" by Kristel J. Ietswaart, LUMC and O. Paul Gobée, LUMC, license: CC BY-NC-SA



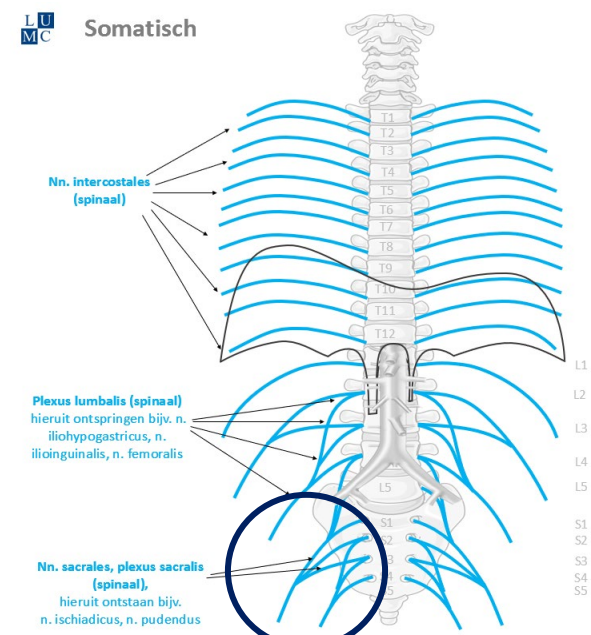
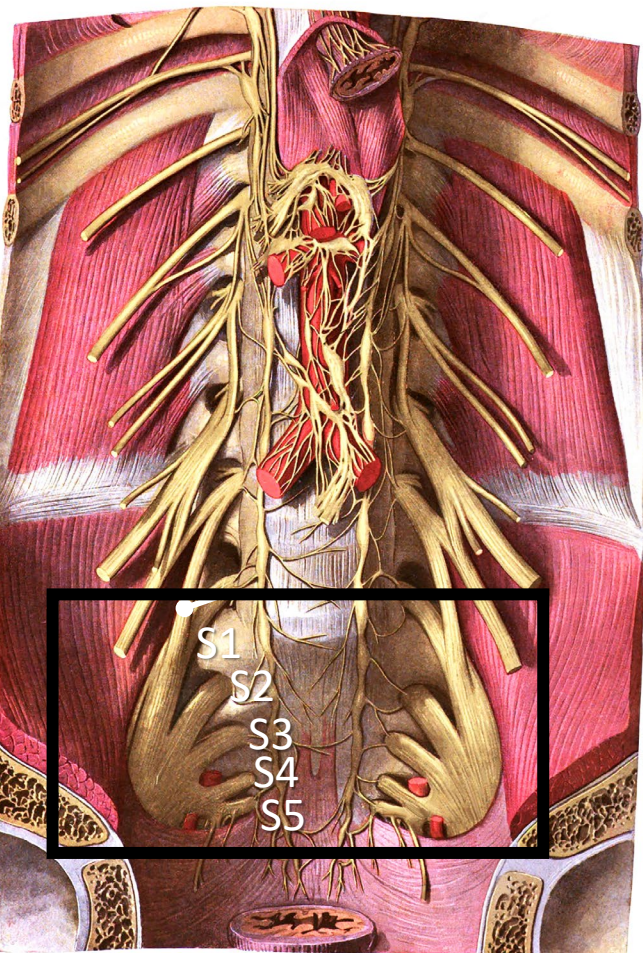
Nn. sacrales



- 1. LOMBO-SACRAL TRUNK
- 2. SACRAL SYMPHATETIC
- 3. RETRORECTAL SPACE
- 4. RIGHT INTERNAL I IAC ARTERY
- 5. LEFT INTERNAL I IAC ARTERY
- 6. LEFT INTERNAL ILIAC VEIN
- 7. RECTUM
- 8. OBTURATOR NERVE



By Anatomist90 - Own work, CC BY-SA 3.0, <https://commons.wikimedia.org/w/index.php?curid=18011854>



Zenuwstelsel

5 onderdelen

Onderdelen

Somatisch

1. Spinale zenuwen

Sympathisch

- 2. Paravertebraal (truncus sympathicus)**
3. Prevertebraal/ preaortaal

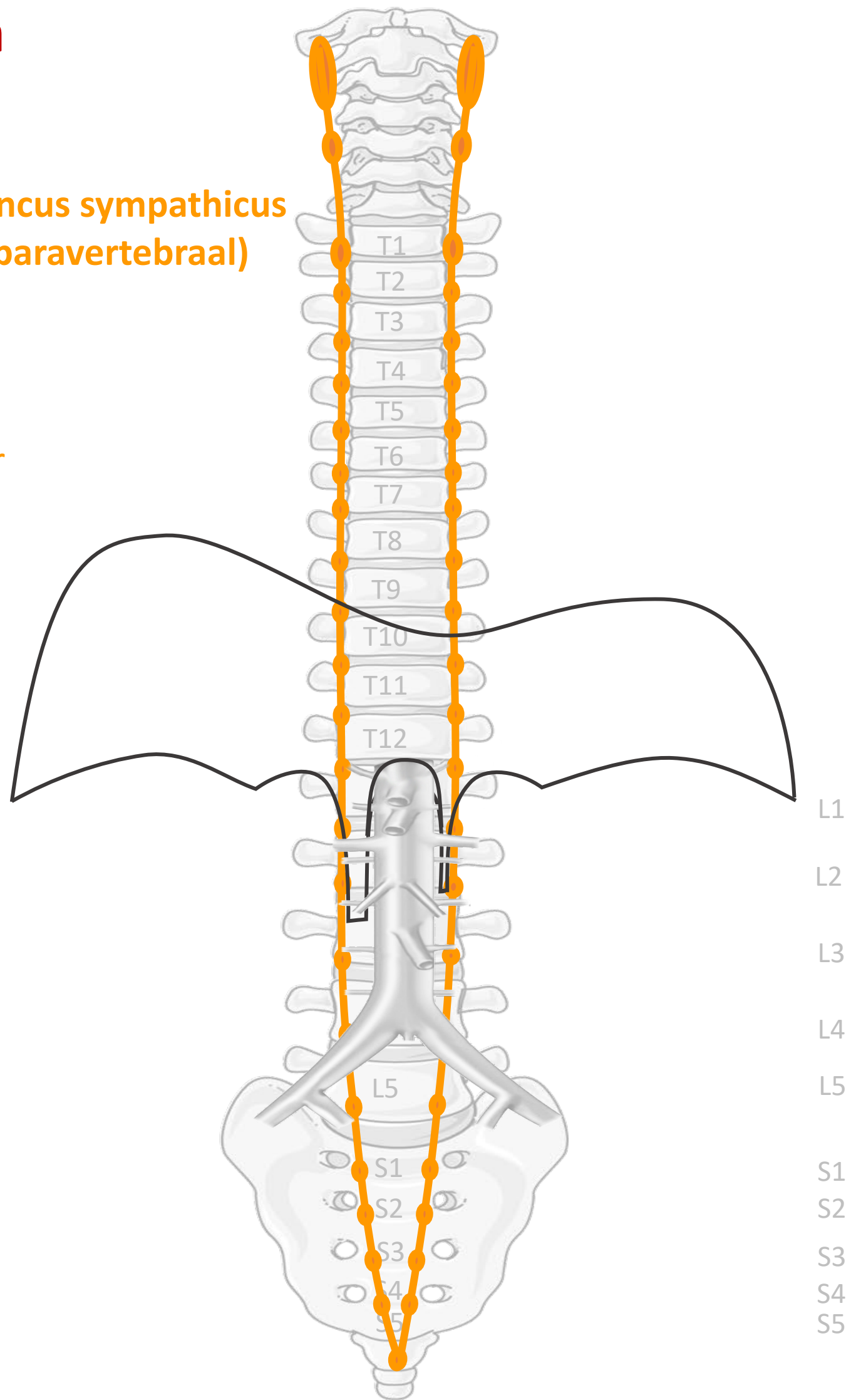
Parasympathisch

4. Nn. vagi
5. Sacraal

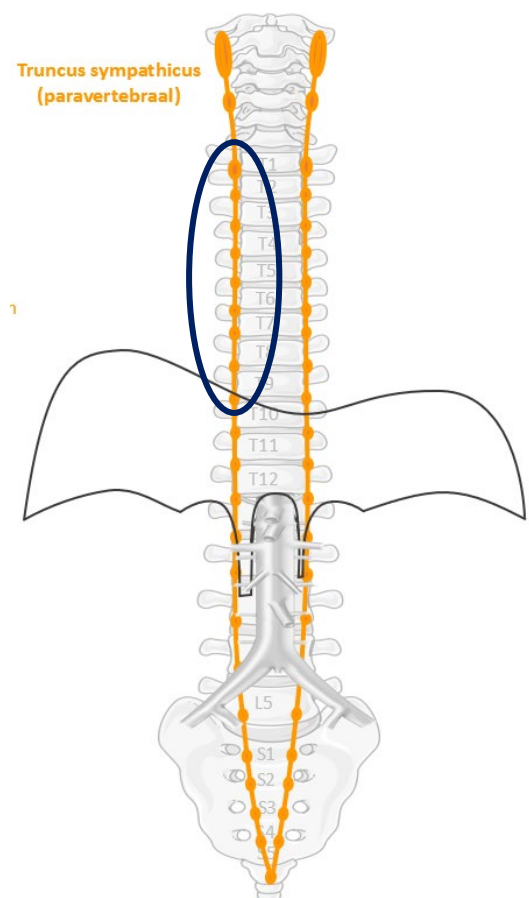

Sympathisch

Truncus sympathicus
(paravertebraal)

Strengen van met elkaar
verbonden ganglia aan
weerszijden van de
wervelkolom



Truncus sympathicus



Zenuwstelsel

5 onderdelen

Onderdelen

Somatisch

1. Spinale zenuwen

Sympathisch

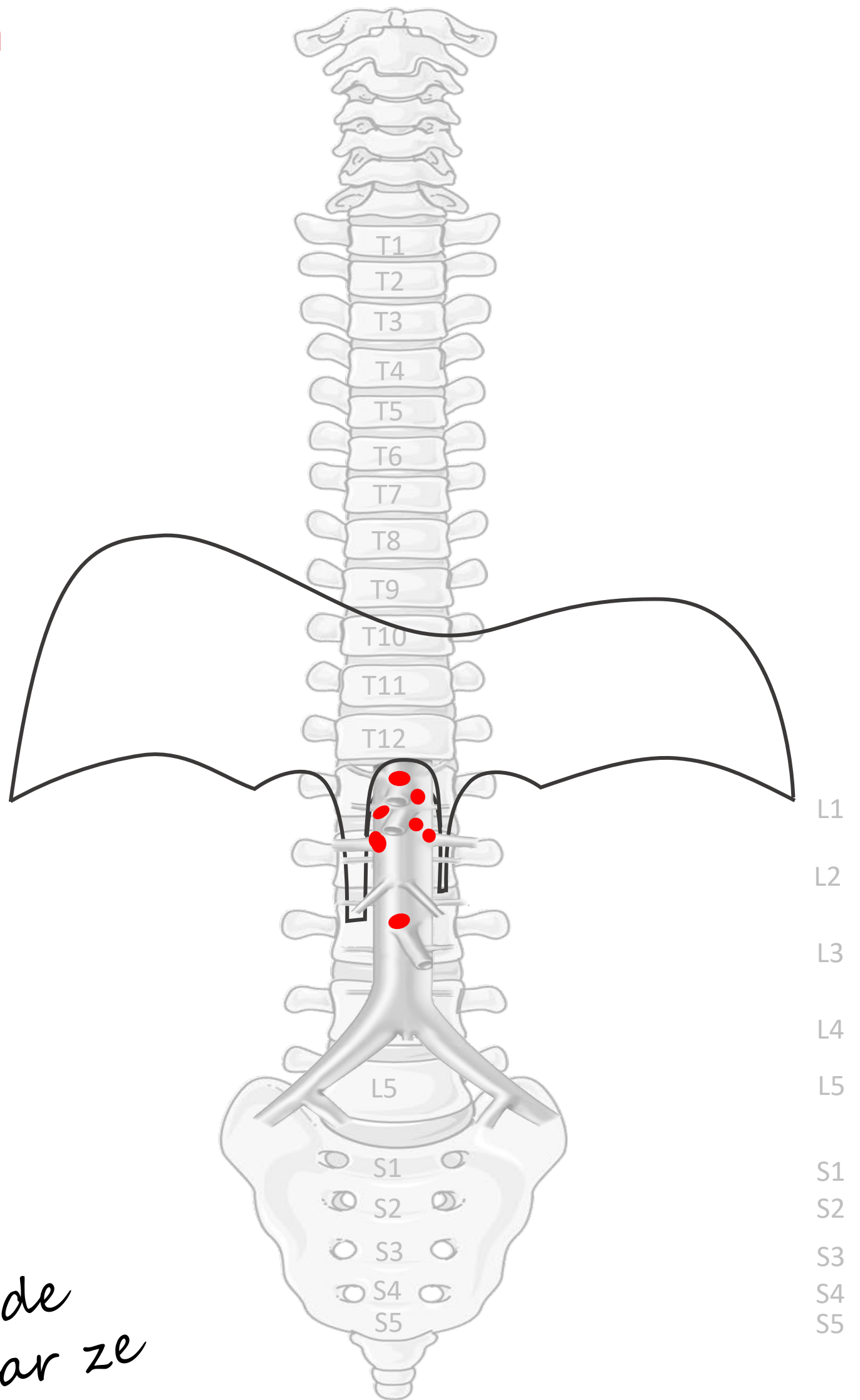
2. Paravertebraal (truncus sympathicus)
- 3. Prevertebraal/ preaortaal**

Parasympathisch

4. Nn. vagi
5. Sacraal

Sympathisch

**Prevertebraal /
preaortaal**
*ganglia coeliaca,
ganglion mesent. sup,
ganglia aorticorenalia
ganglia mesent. inf*

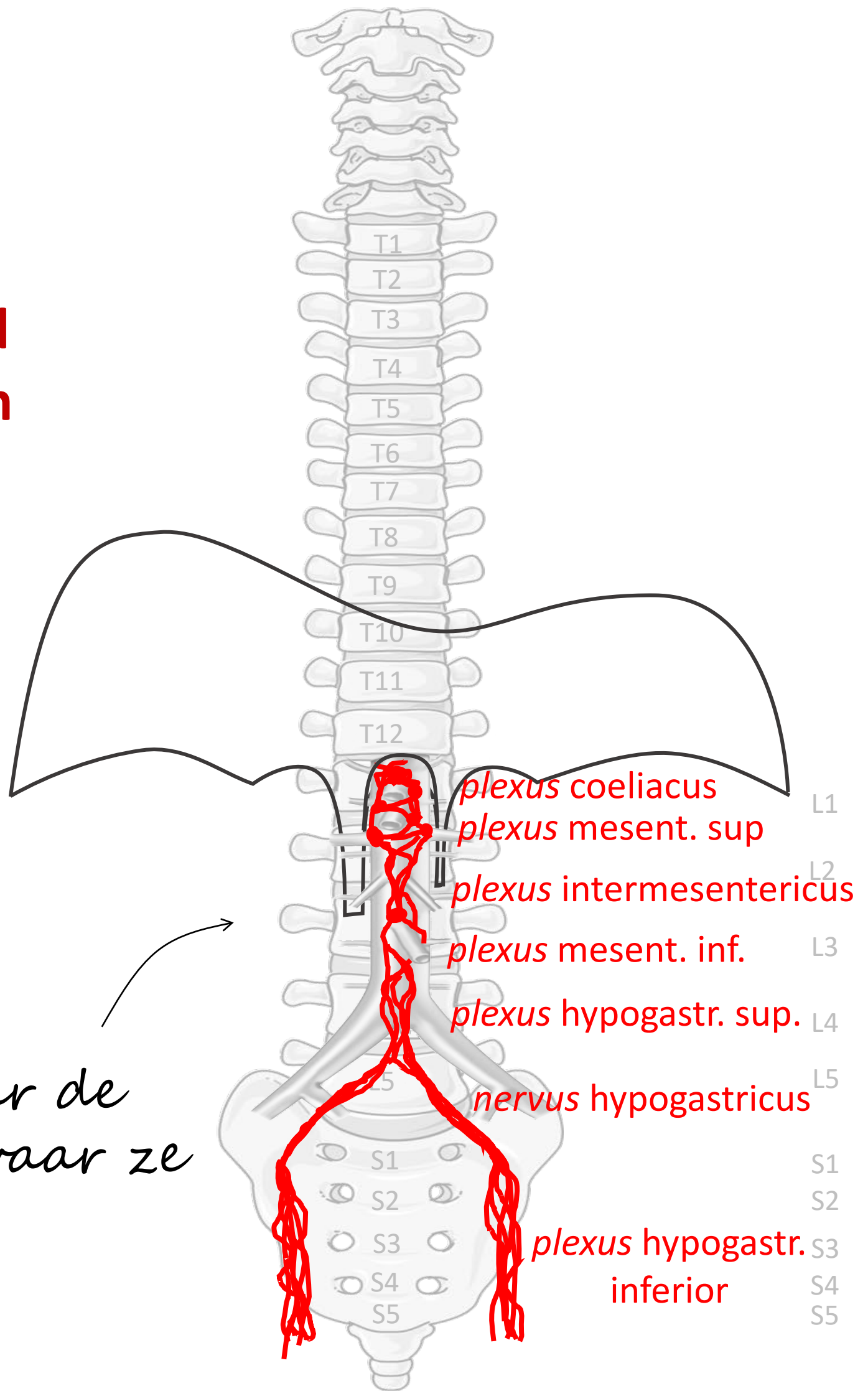


*genoemd naar de
grote vaten waar ze
bij liggen*

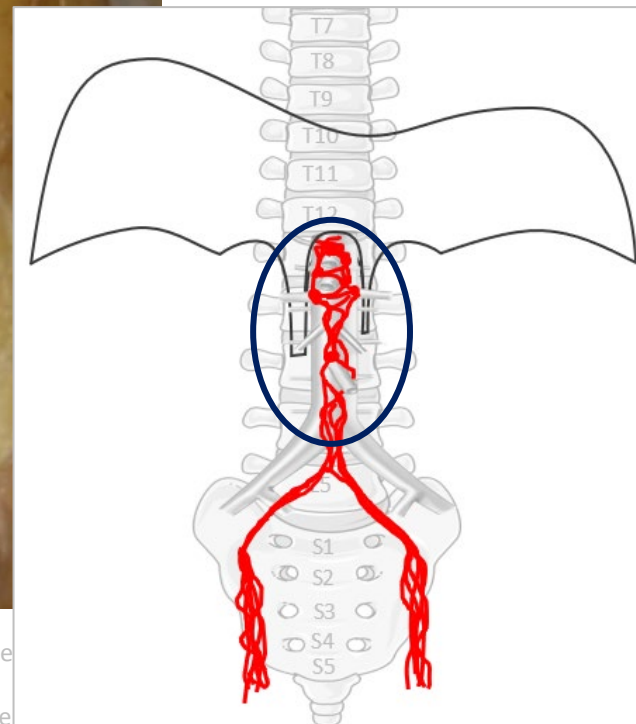
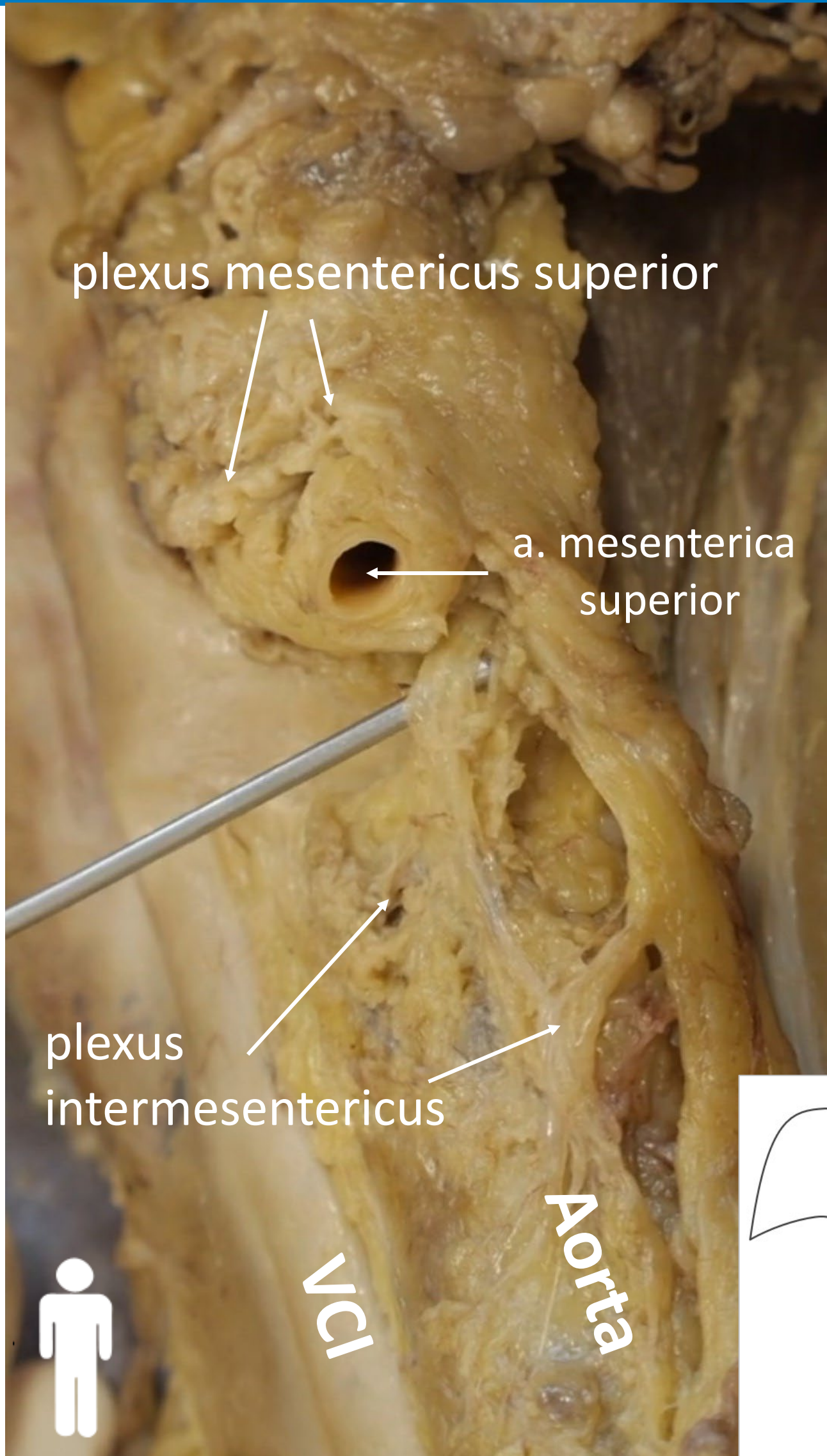
Gemengd
para/symp
maar
overwegend
Sympathisch

Prevertebraal /
preaortaal

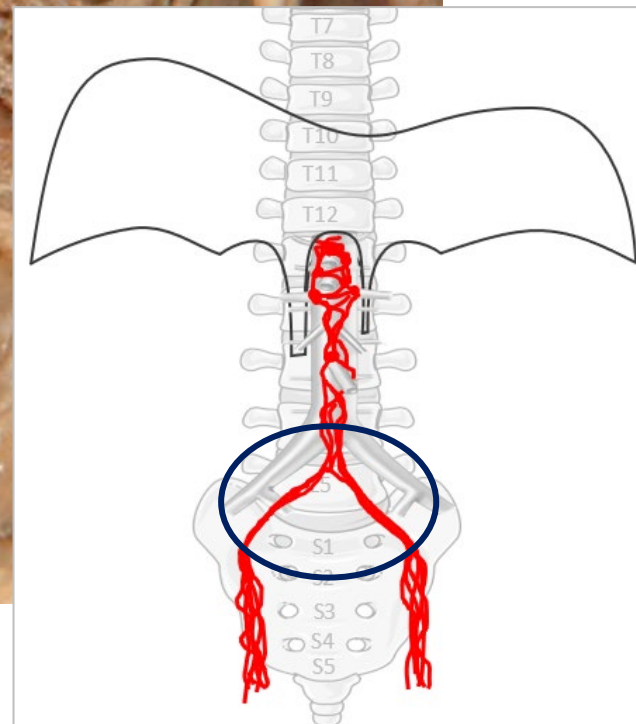

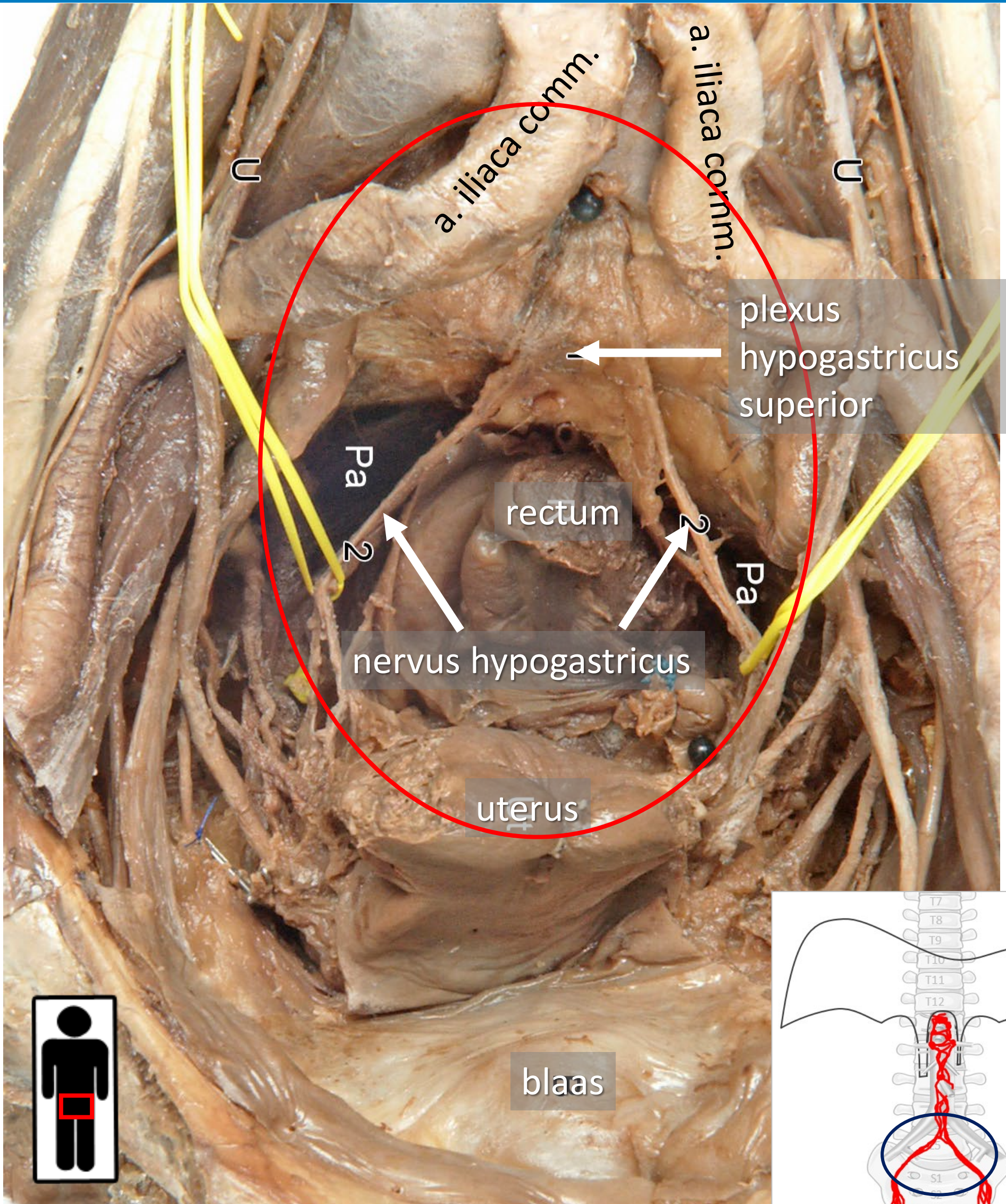
genoemd naar de
grote vaten waar ze
bij liggen



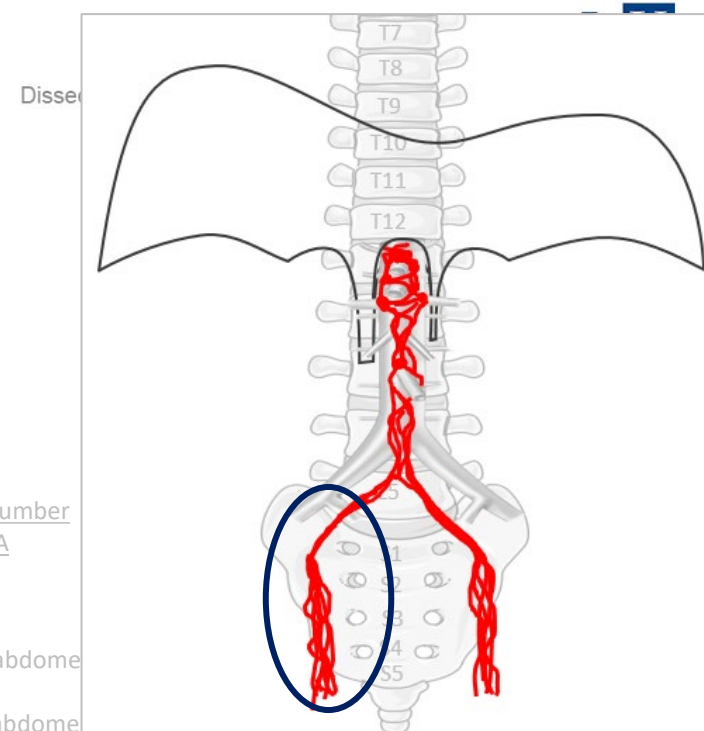
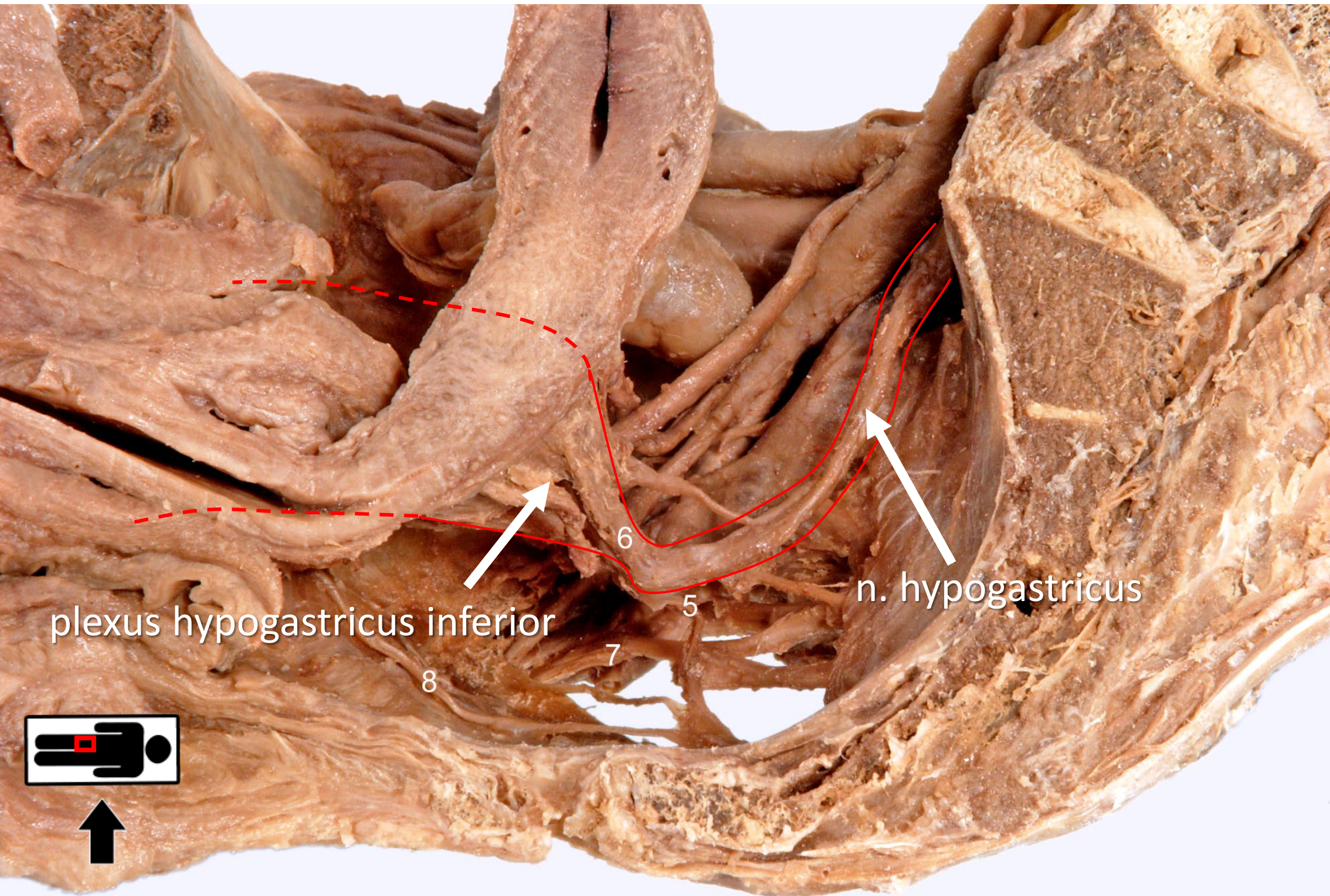
Prevertebrale/ preaortale plexi & ganglia



Prevertebrale/ preaortale plexi & ganglia



Prevertebrale/ preaortale plexi & ganglia



"Leiden, Maas Photo 15 - Sagittal view of the female pelvic nerves (plastination specimen) - number labels" by Kees (C.P.) Maas, LUMC, Marco C. DeRuiter, LUMC and J. Lens, license: CC BY-NC-SA

shot uit video , Leiden MOOC 6.4 - Video Anatomy on the Table: Innervation of the viscera – abdome by Bas Boekestijn, dept. Anatomy & Embryology, LUMC license CC BY NC SA
<https://anatomytool.org/content/leiden-mooc-64-video-anatomy-table-innervation-viscera-abdome>

Zenuwstelsel

5 onderdelen

Onderdelen

Somatisch

1. Spinale zenuwen

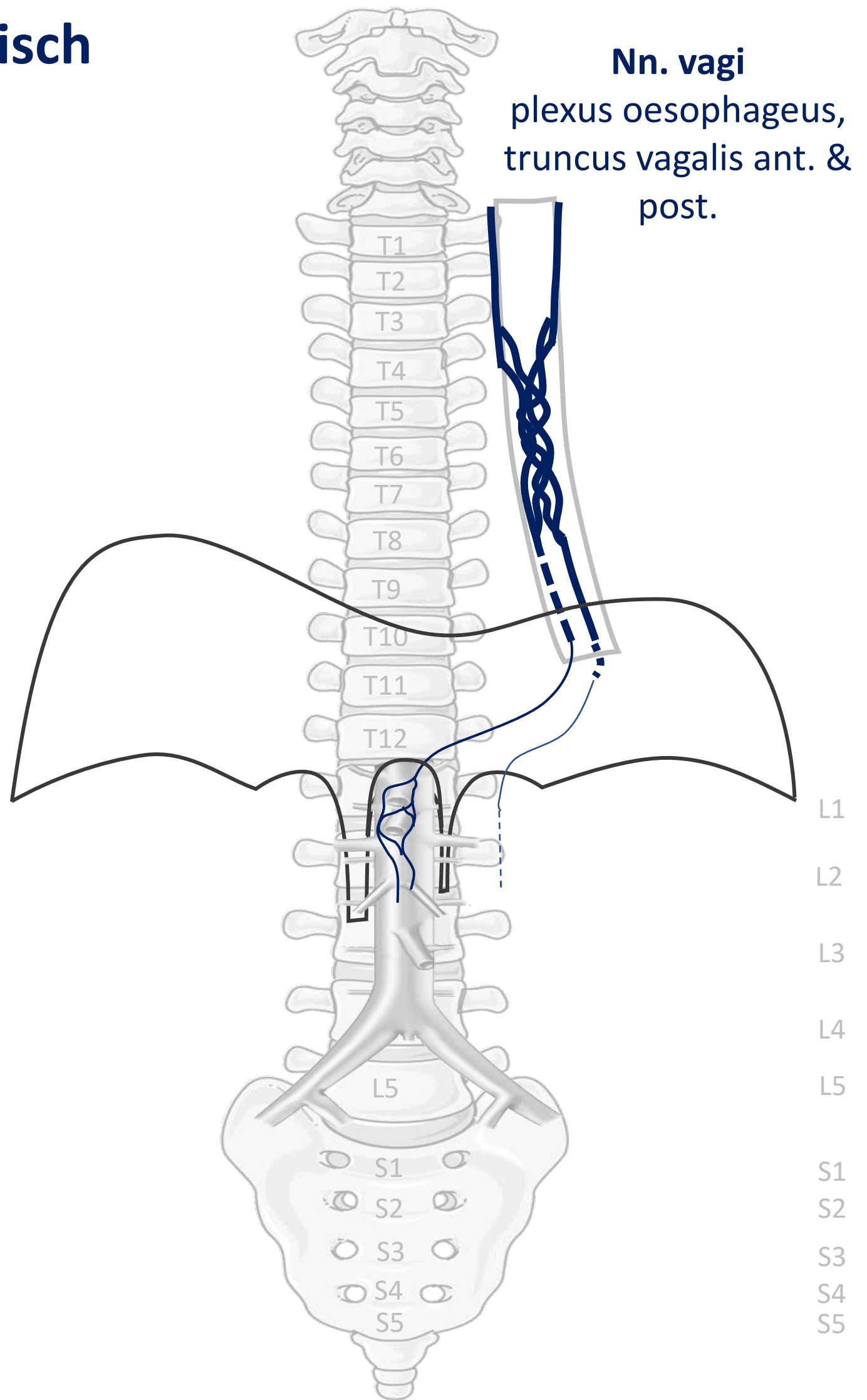
Sympathisch

2. Paravertebraal (truncus sympathicus)
3. Prevertebraal/ preaortaal

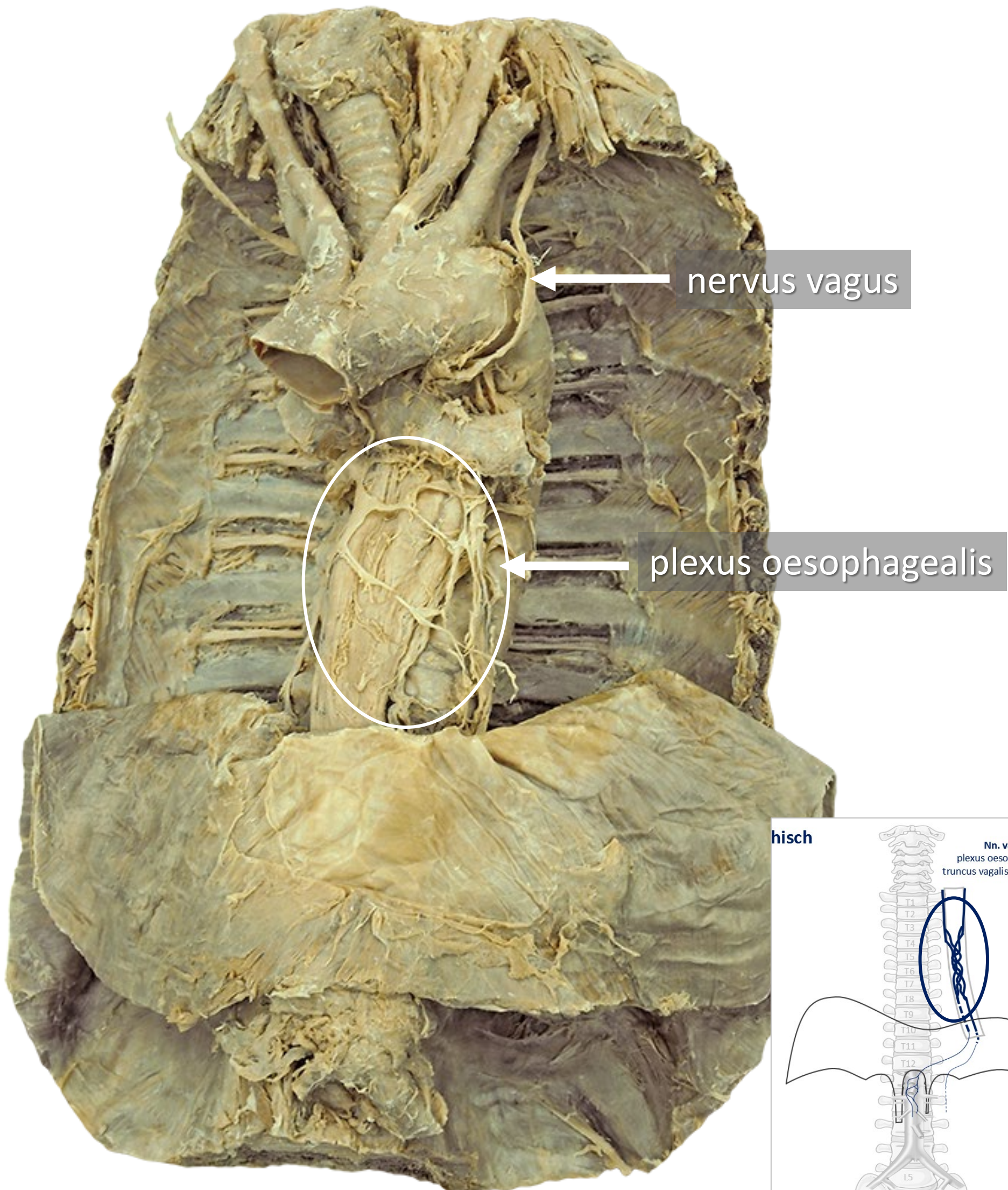
Parasympathisch

- 4. Nn. vagi**
5. Sacraal

Parasympathisch



Nervus vagus & plexus oesophagealis



Zenuwstelsel

5 onderdelen

Onderdelen

Somatisch

1. Spinale zenuwen

Sympathisch

2. Paravertebraal (truncus sympathicus)
3. Prevertebraal/ preaortaal

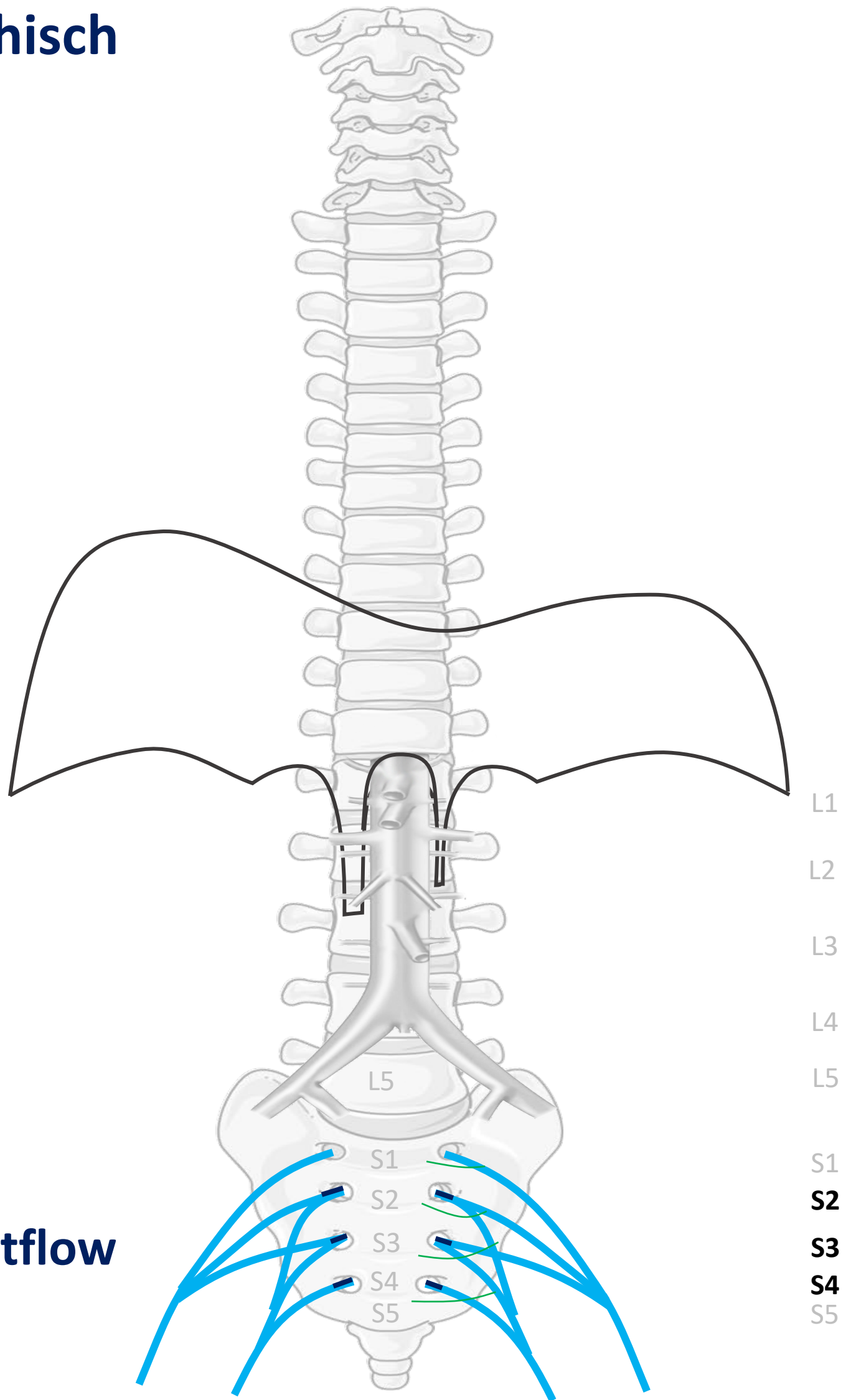
Parasympathisch

4. Nn. vagi
- 5. Sacraal (S2-S4)**

Parasympathisch

Sacrale parasympathische outflow (S2-S4)

Plexus sacralis, Nn. sacrales (spinaal)



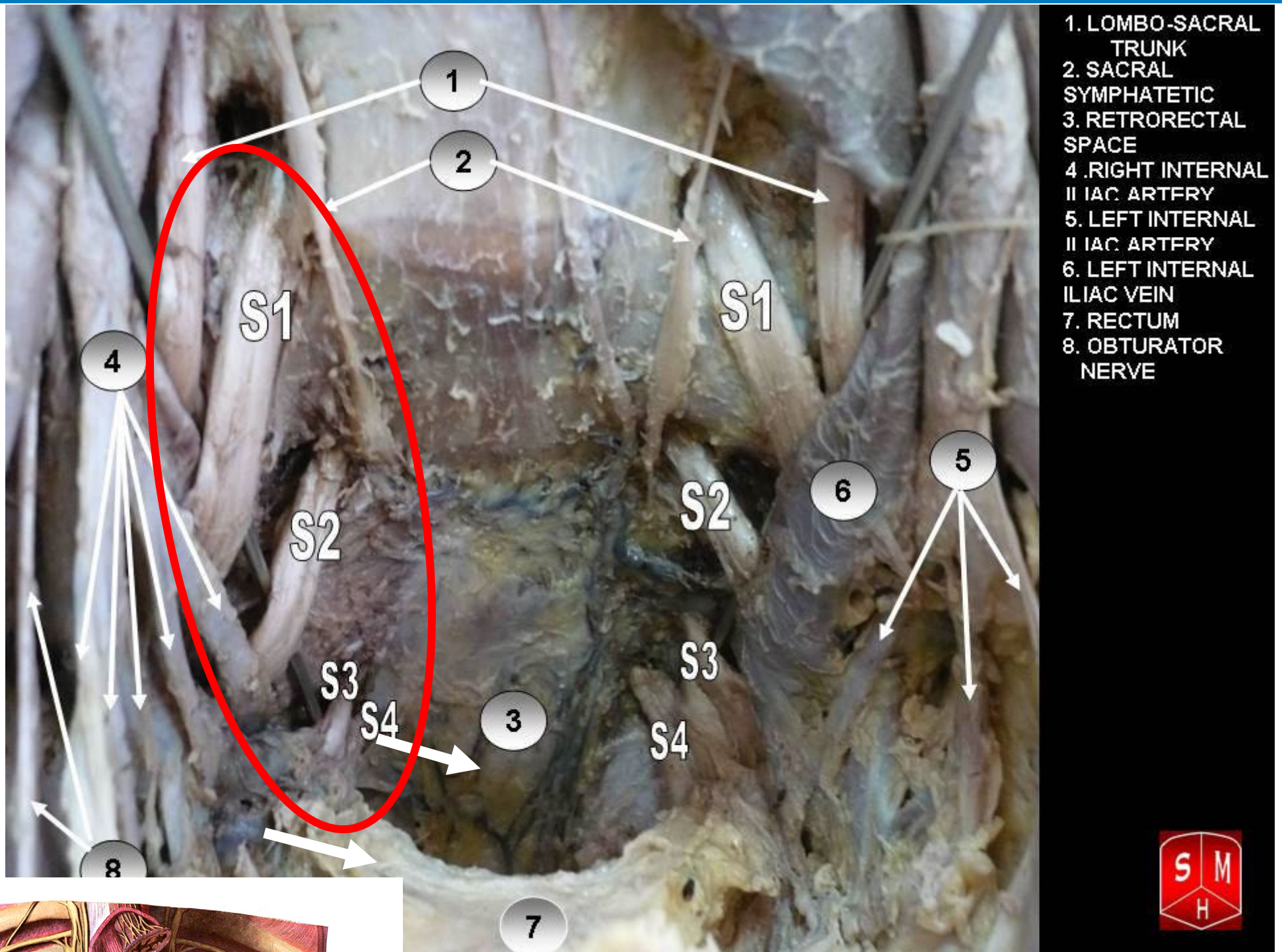
Download dit schema



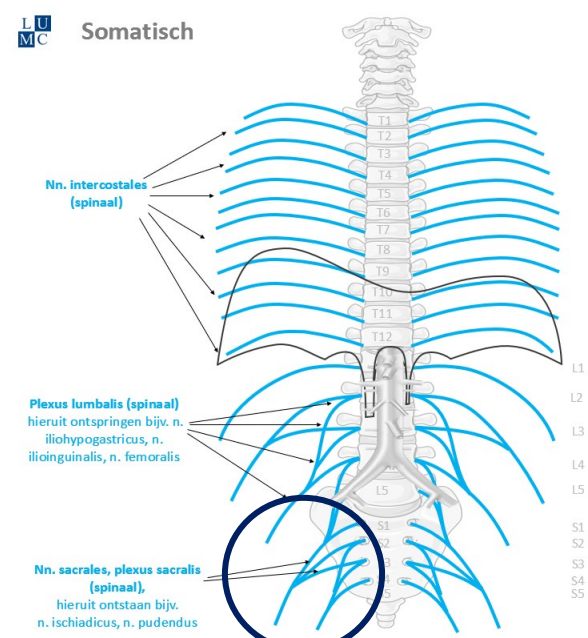
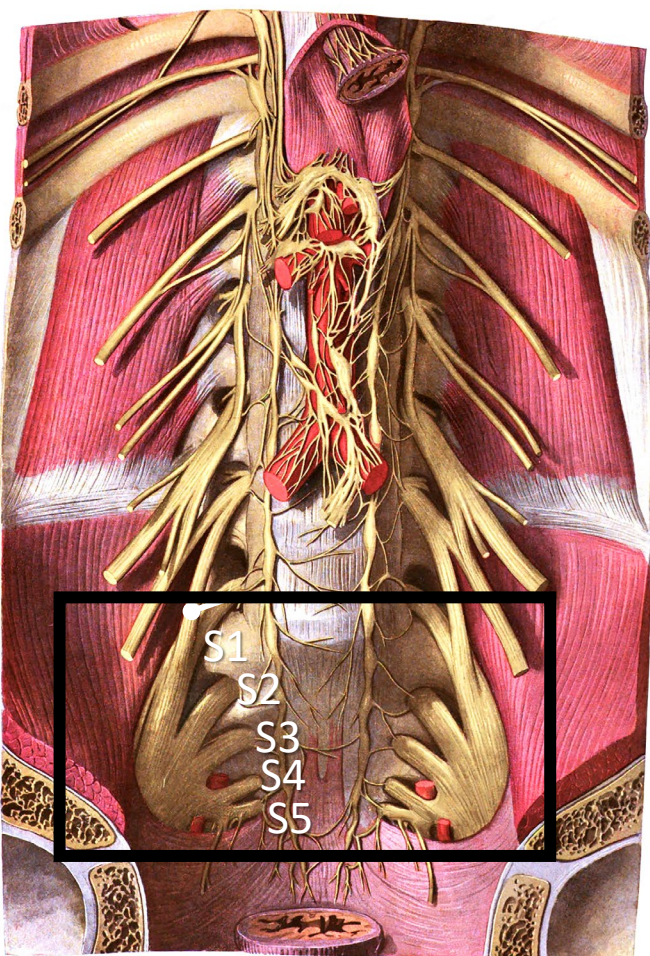
v. 3, March 2024



Sacrale parasymphatische outflow via nn. sacrales



By Anatomist90 - Own work, CC BY-SA 3.0,
<https://commons.wikimedia.org/w/index.php?curid=18011854>



3 verbindingen

Verbindingen

1. Rami communicans (*sympathisch*)
2. Splanchnische zenuwen (*sympathisch*)
3. Pelviene splanchnische zenuwen (*parasympathisch*)

3 verbindingen

Verbindingen

1. **Rami communicans (*sympathisch*)**
2. Splanchnische zenuwen (*sympathisch*)
3. Pelviene splanchnische zenuwen (*parasympathisch*)

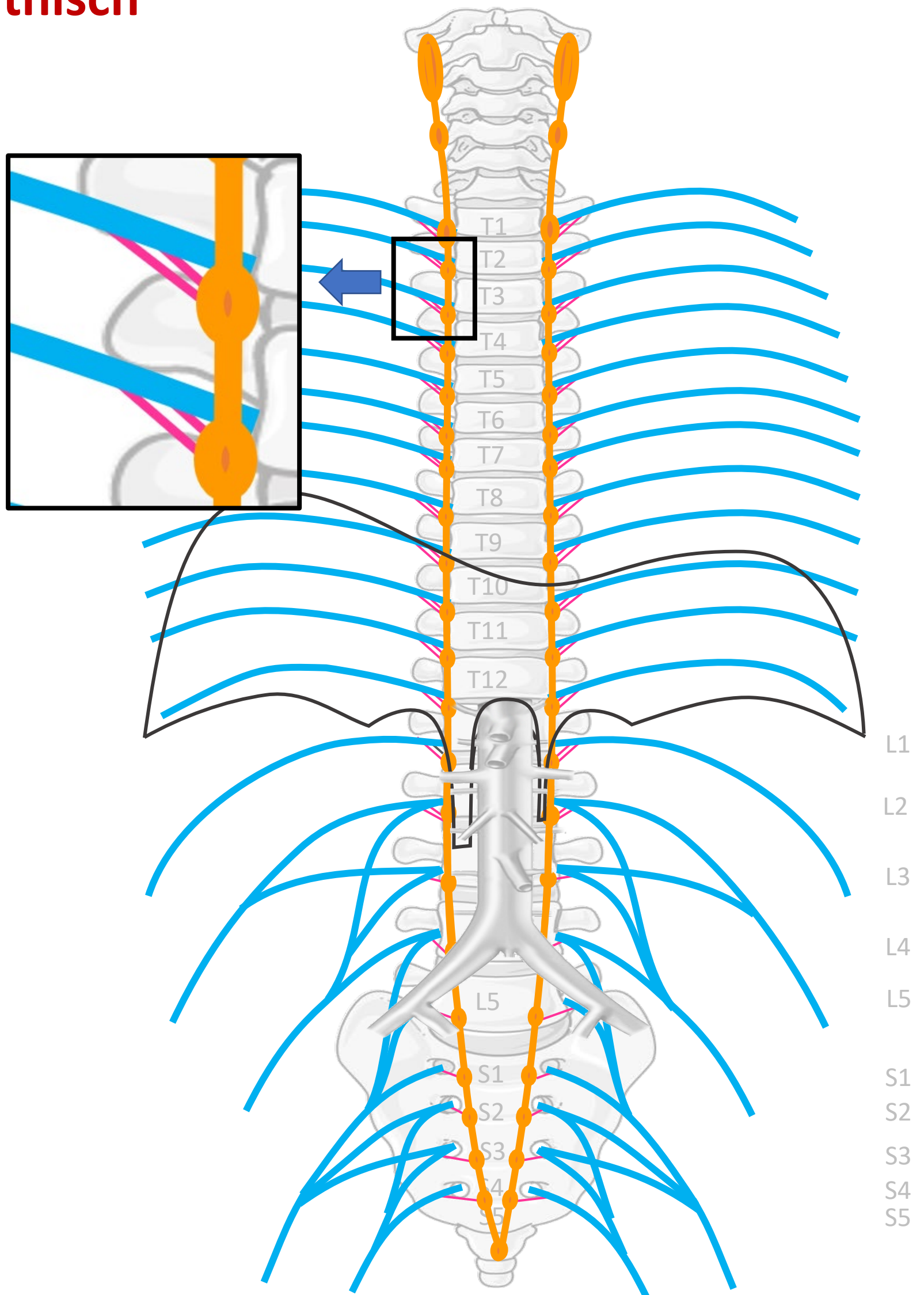


Sympathisch

Rami communicans

verbinden spinale zenuwen

met Truncus sympathicus (paravertebraal)



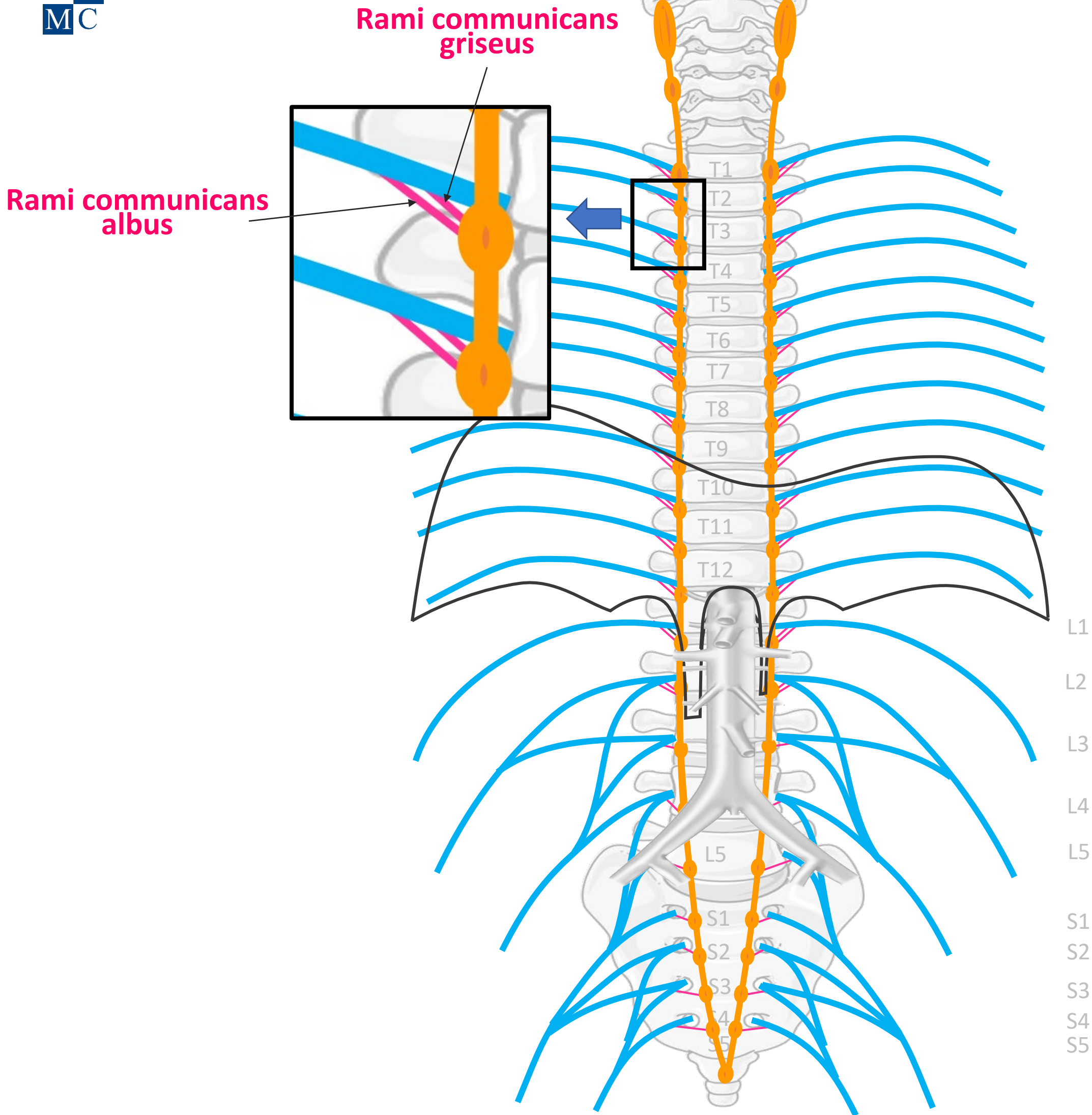
Download dit schema



v. 3, March 2024



Sympathisch



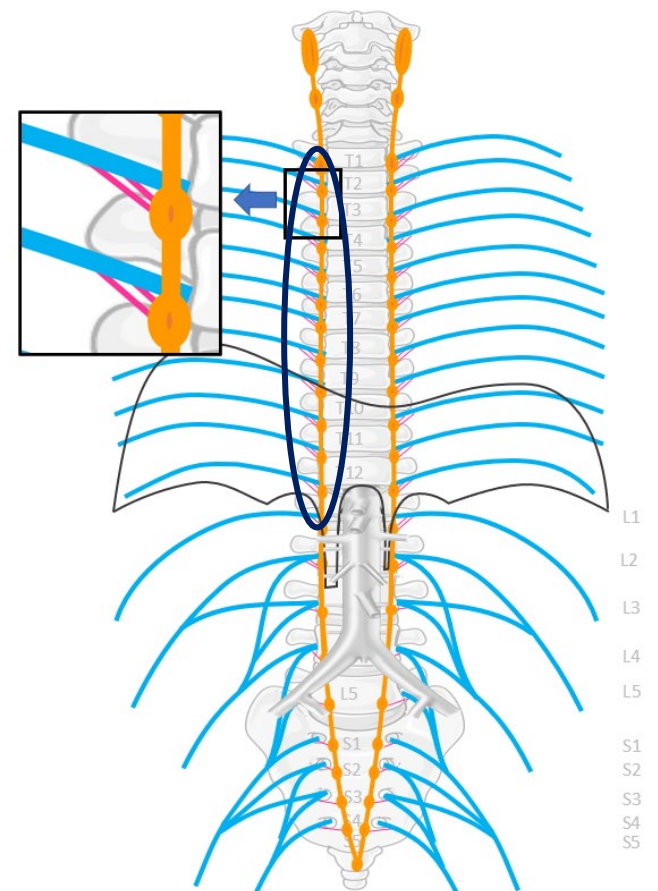
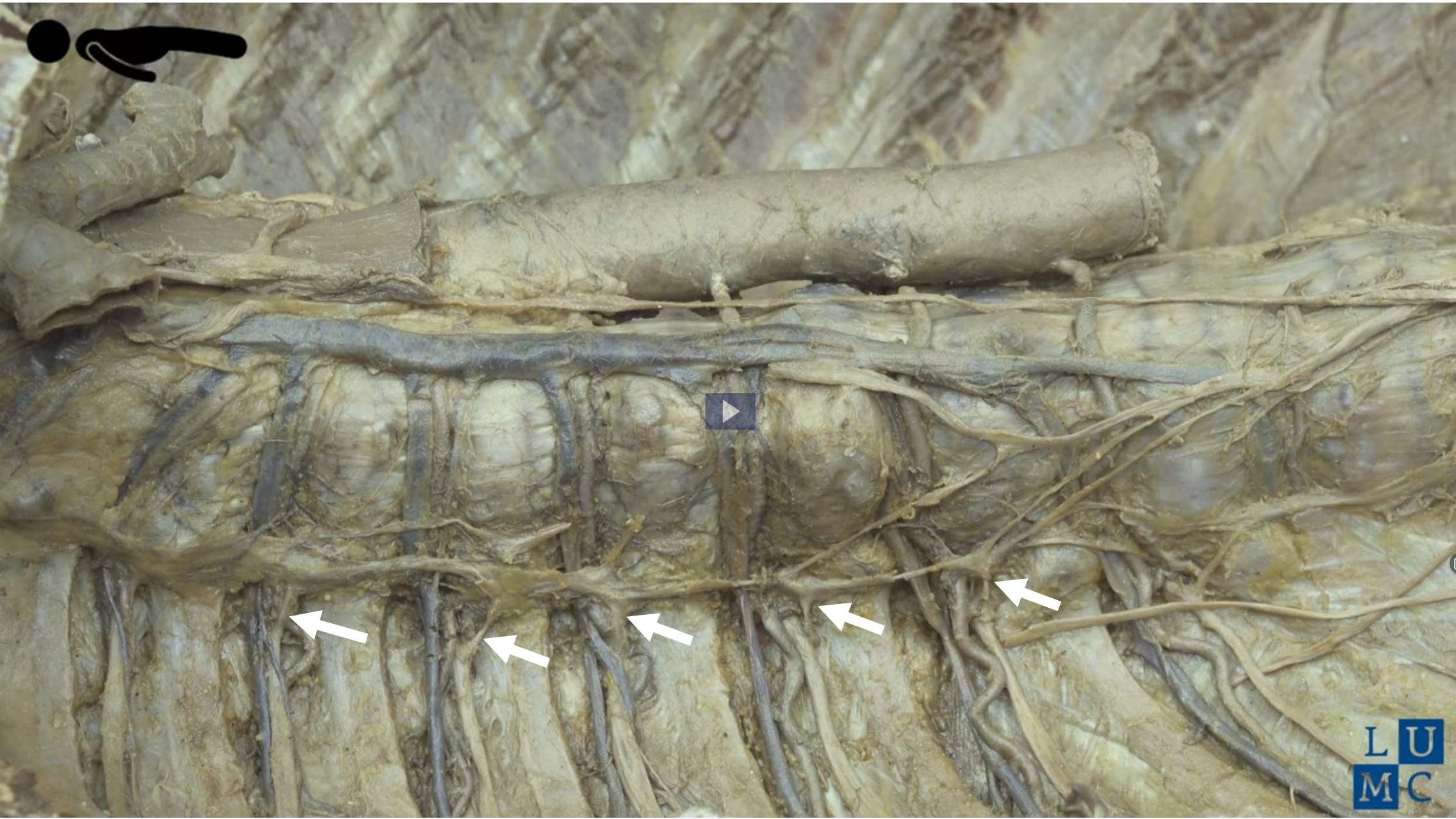
Download dit schema



v. 3, March 2024



Rami communicans



3 verbindingen

Verbindingen

1. Rami communicans (*sympathisch*)
- 2. Splanchnische zenuwen (*sympathisch*)**
3. Pelviene splanchnische zenuwen (*parasympathisch*)

Splanchnische zenuwen (sympathisch)

Voorzien inwendige organen (*splanchn-*) sympathisch:

- 1. Cardiopulmonale splanchnische zenuwen**
naar hart, longen, oesophagus
- 2. Thoracale splanchnische zenuwen**
voorzien *buikorganen (voor- en middendarm)*:
lever, milt, pancreas, nieren,
maag t/m colon transversum, uterus*
- 3. Lumbale splanchnische zenuwen**
voorzien *buik (einddarm) - en bekkenorganen*:
colon descendens t/m rectum,
blaas, uterus*, ovariae, prostaat

*uterus ~ T10-L1/2 (Gray's anatomy 40ed)

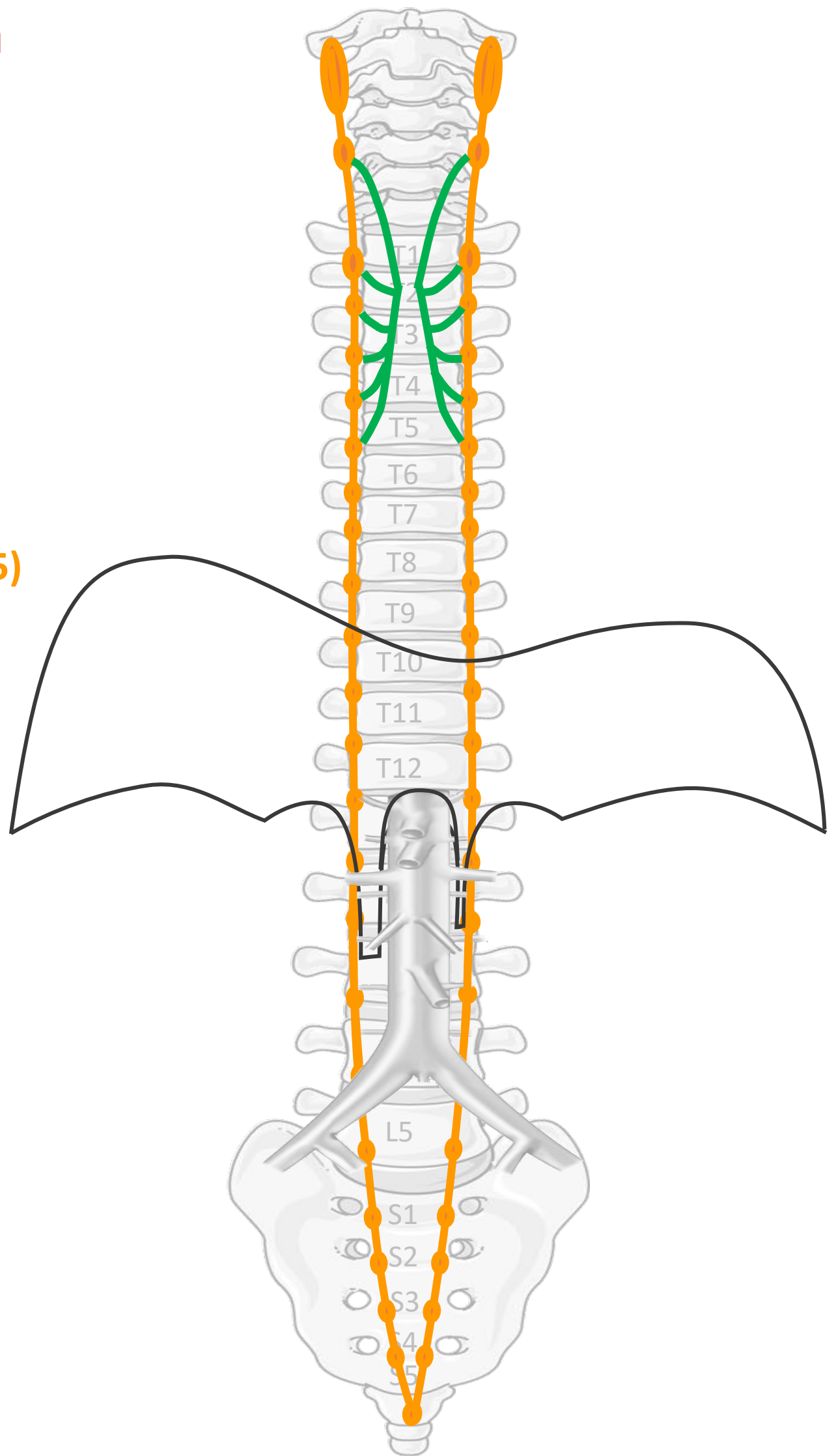
Cardiopulmonale
splanchnische
zenuwen

van

Truncus sympathicus (~C4 – T5)
(paravertebraal)

naar

hart, longen, oesophagus





Sympathisch

Thoracale splanchnische zenuwen:

**N. splanchnicus major (T5-T9),
N. splanchnicus minor (T10-T11),
N. splanchnicus imus (T12)**

van

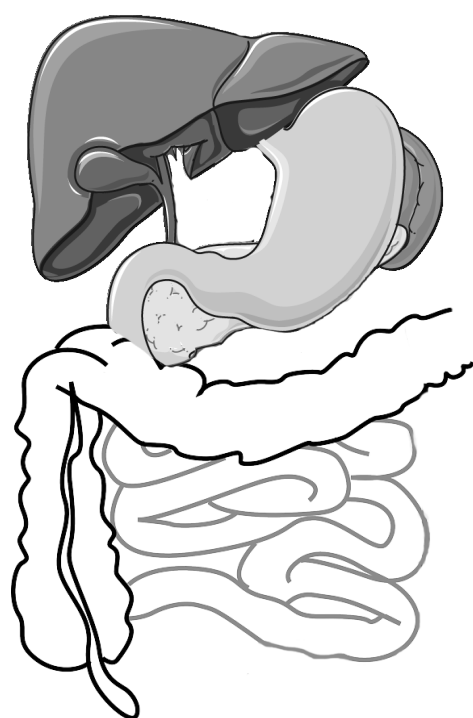
**Truncus sympathicus (T5-T12)
(paravertebraal)**

naar

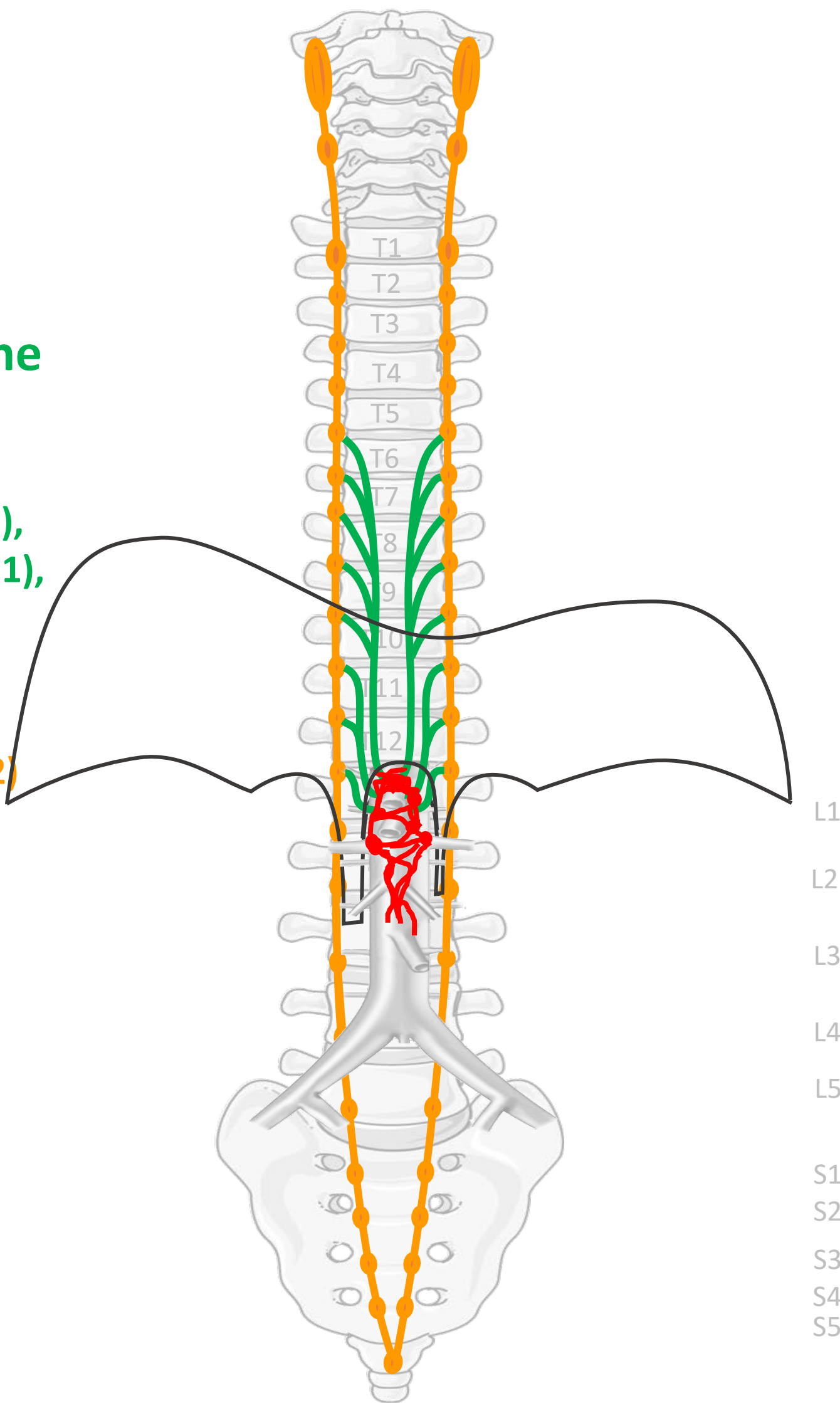
Prevertebrale / preaortale ganglia & plexi

ganglia & plexus coeliacus,
ganglion & plexus mesent. sup,
ganglia aorticorenalia,
plexus intermesentericus,
plexus mesent. inf.

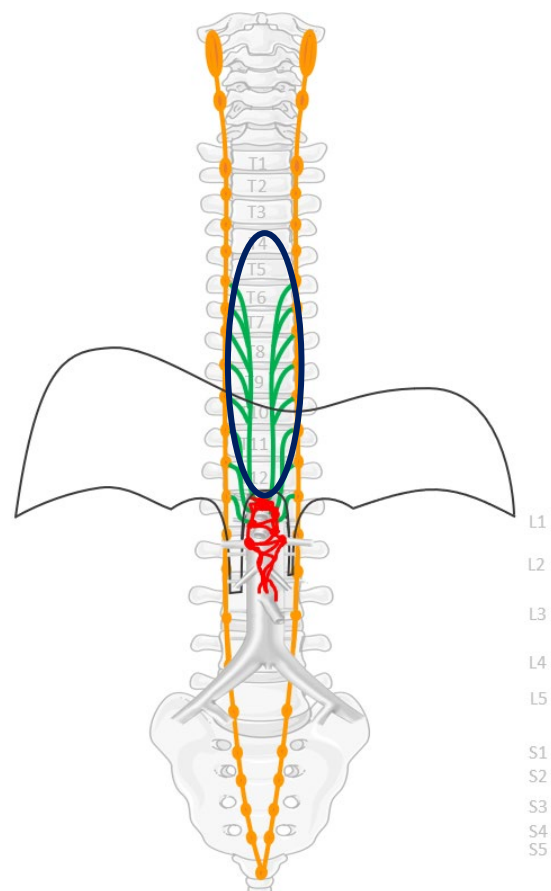
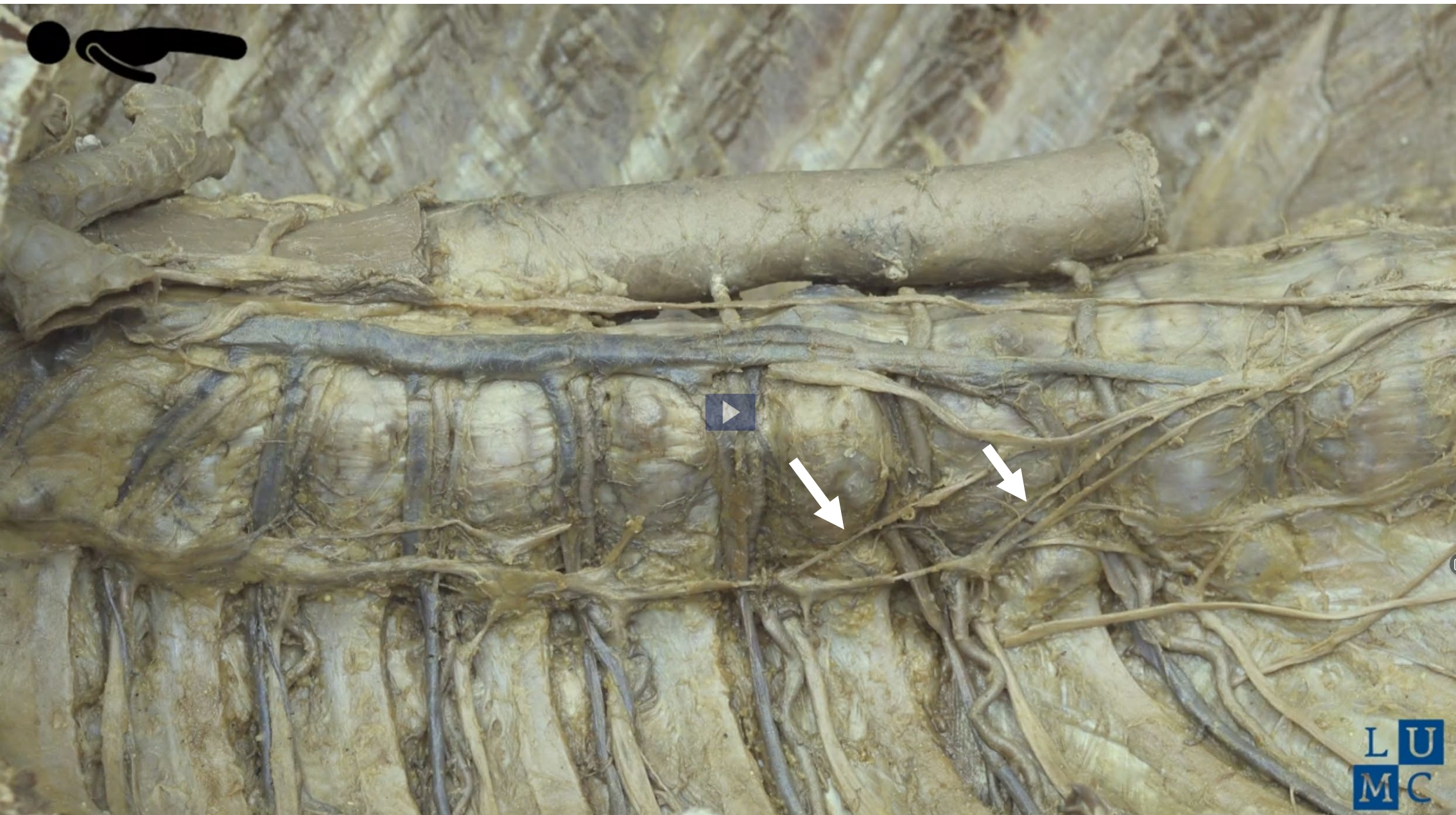
Prikkels daarna verder naar



(voor- en middendarm)

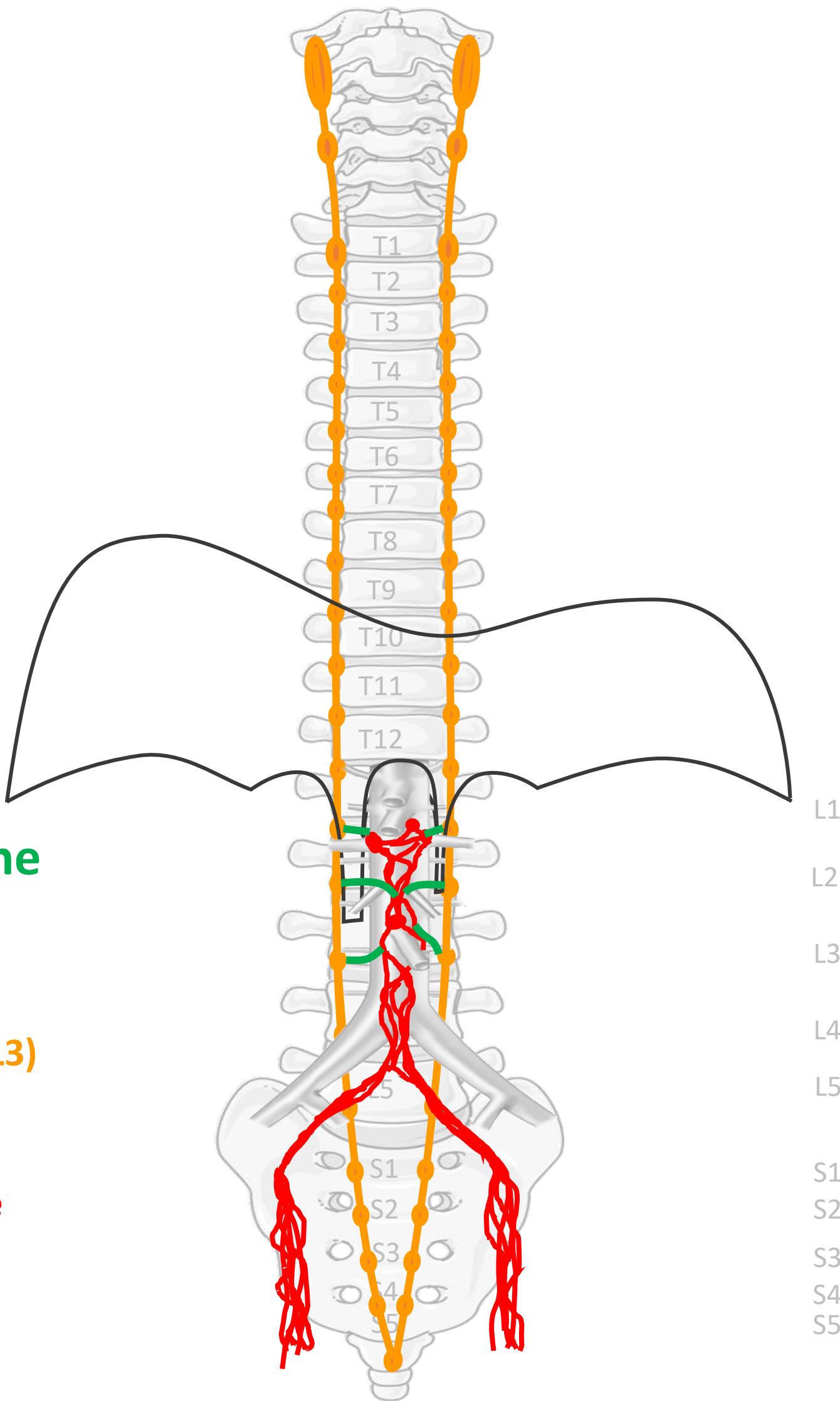


Thoracale splanchnische zenuwen N. splanchnicus major, minor, imus



shot uit video , Leiden - Video Demonstratie Anatomie Thorax (dissectie-preparaat) Friso P. Jansen, Tamara M. Guijt-Alberts en Judith de Roeck-den Boeft, dept. Anatomy & Embryology, LUMC license CC BY NC SA
<https://anatomytool.org/content/leiden-video-demonstratie-anatomie-thorax-dissectie-preparaat>

L1
L2
L3
L4
L5
S1
S2
S3
S4
S5



Lumbale splanchnische zenuwen

van

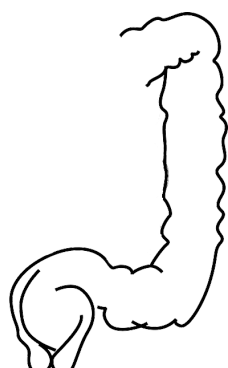
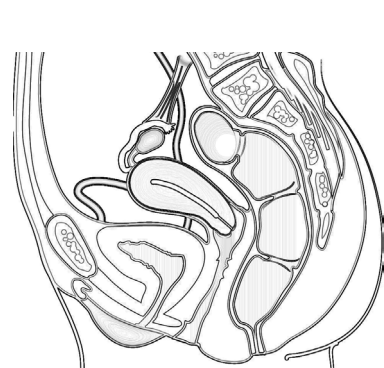
Truncus sympathicus (L1 - ~L3) (paravertebraal)

naar

Prevertebrale / preaortale ganglia & plexi:

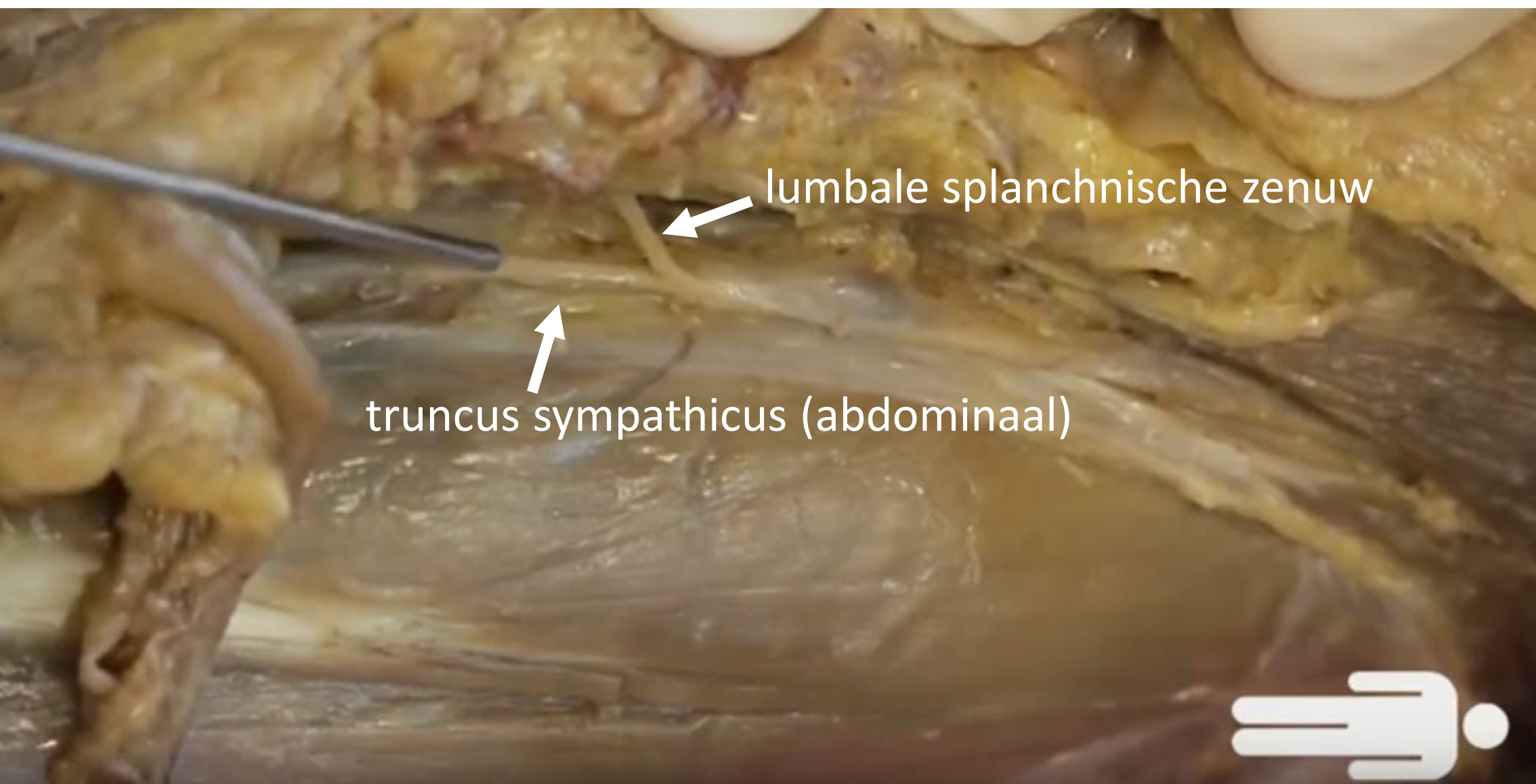
plexus intermesentericus,
ganglia & plexus mesent. inf.,
plexus hypogastricus sup.,
n. hypogastricus,
plexus hypogastricus inf.

Prikkels daarna verder naar



(einddarm en bekkensorganen)

Lumbale splanchnische zenuwen



3 verbindingen

Verbindingen

1. Rami communicans (*sympathisch*)
2. Splanchnische zenuwen (*sympathisch*)
3. **Pelviene splanchnische zenuwen (*parasympathisch*)**



Parasympathisch

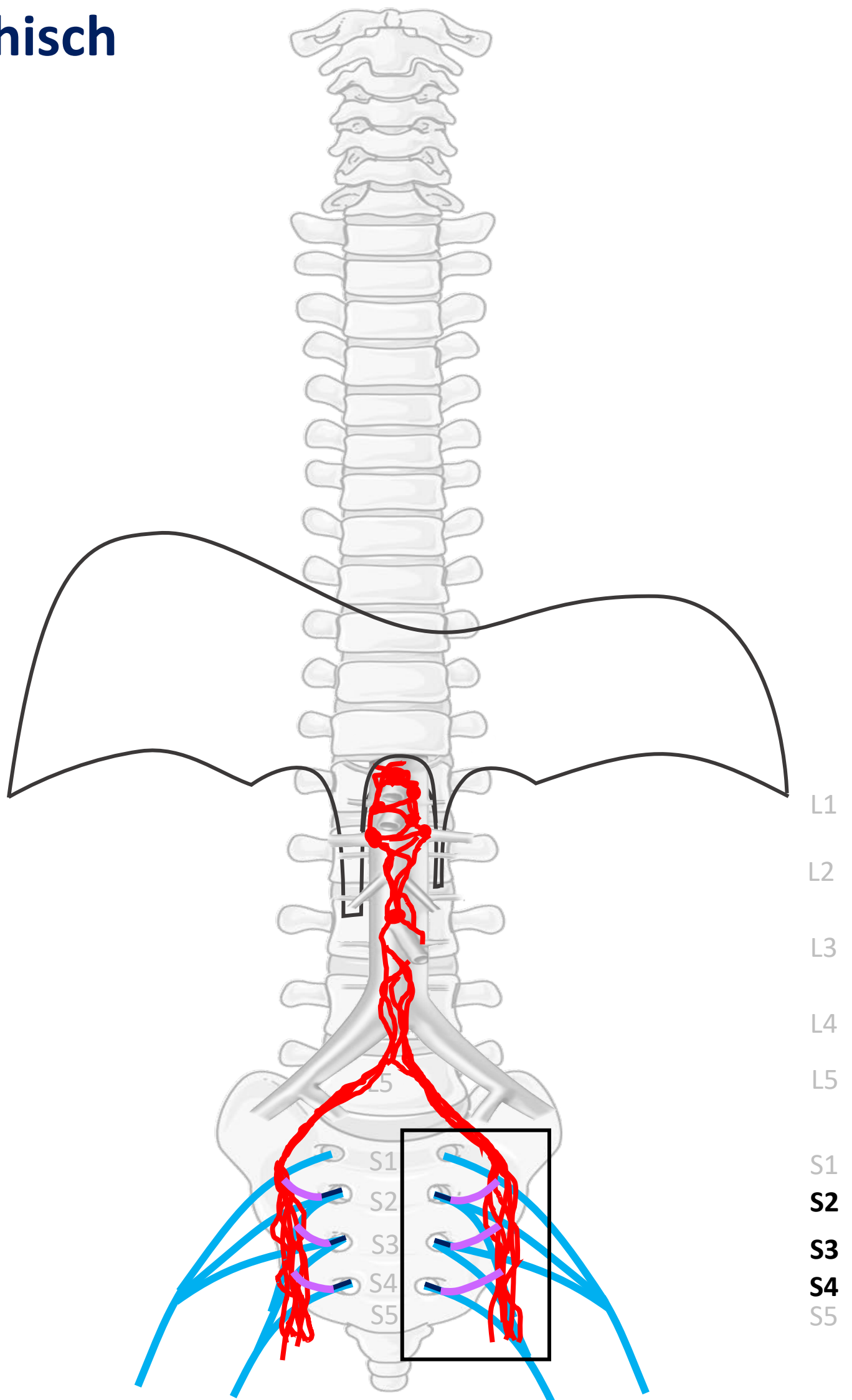
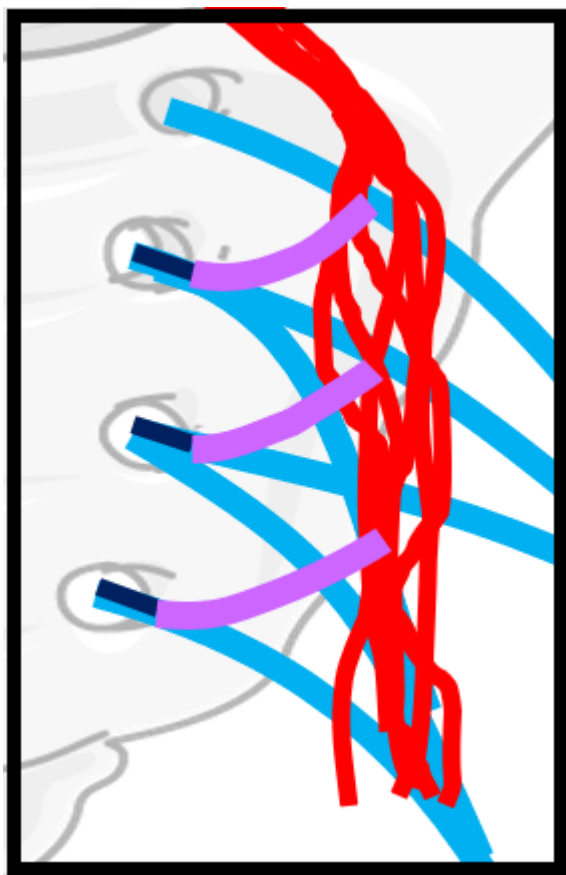
Pelviene
splanchnische
zenuwen

Verbinden

Sacrale parasymp. outflow
(S2-S4)

met

Plexus hypogastr. inf.



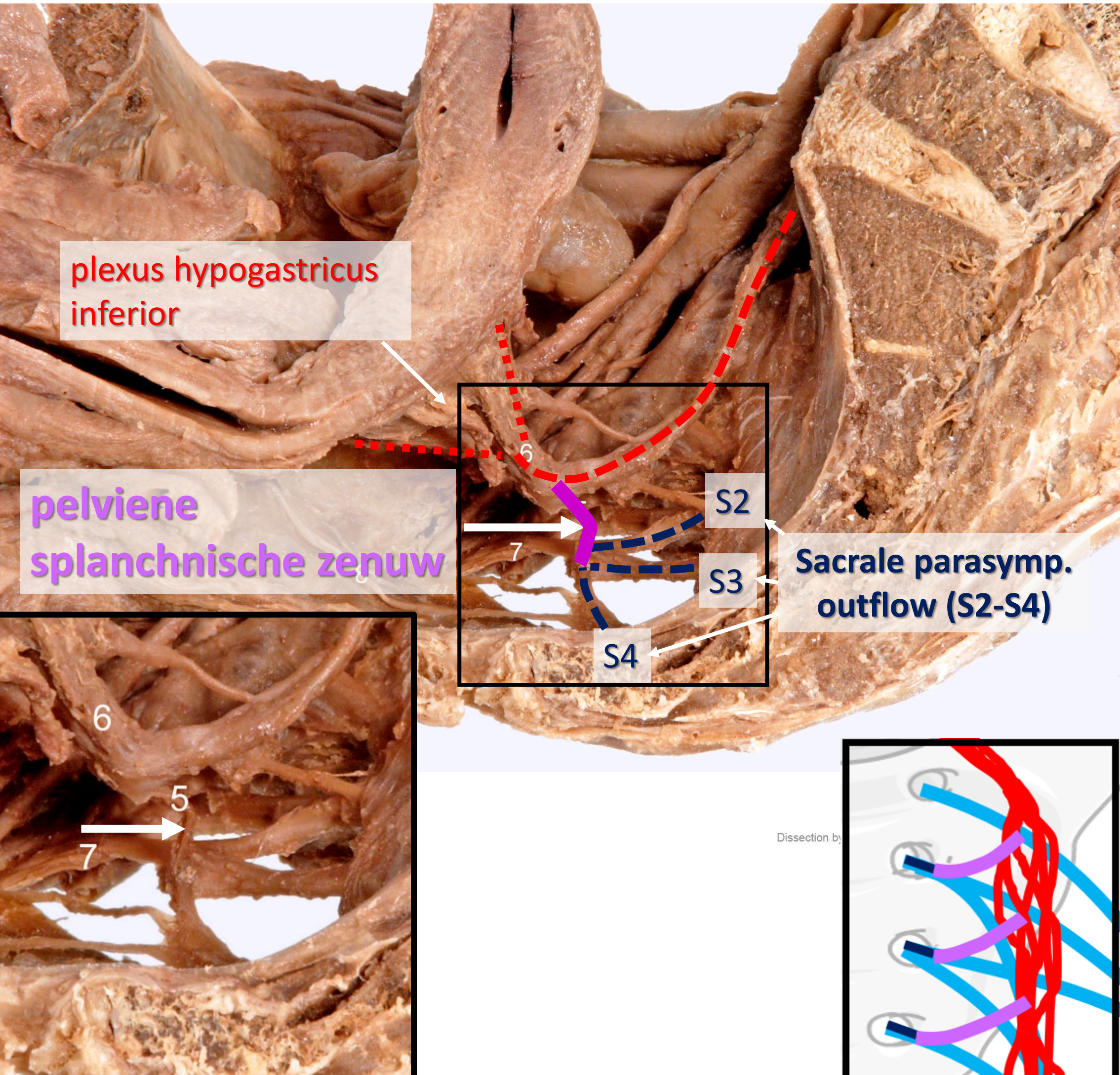
Download dit schema



v. 3, March 2024



Pelviene splanchnische zenuw



Zenuwstelsel in 5 onderdelen en 3 verbindingen

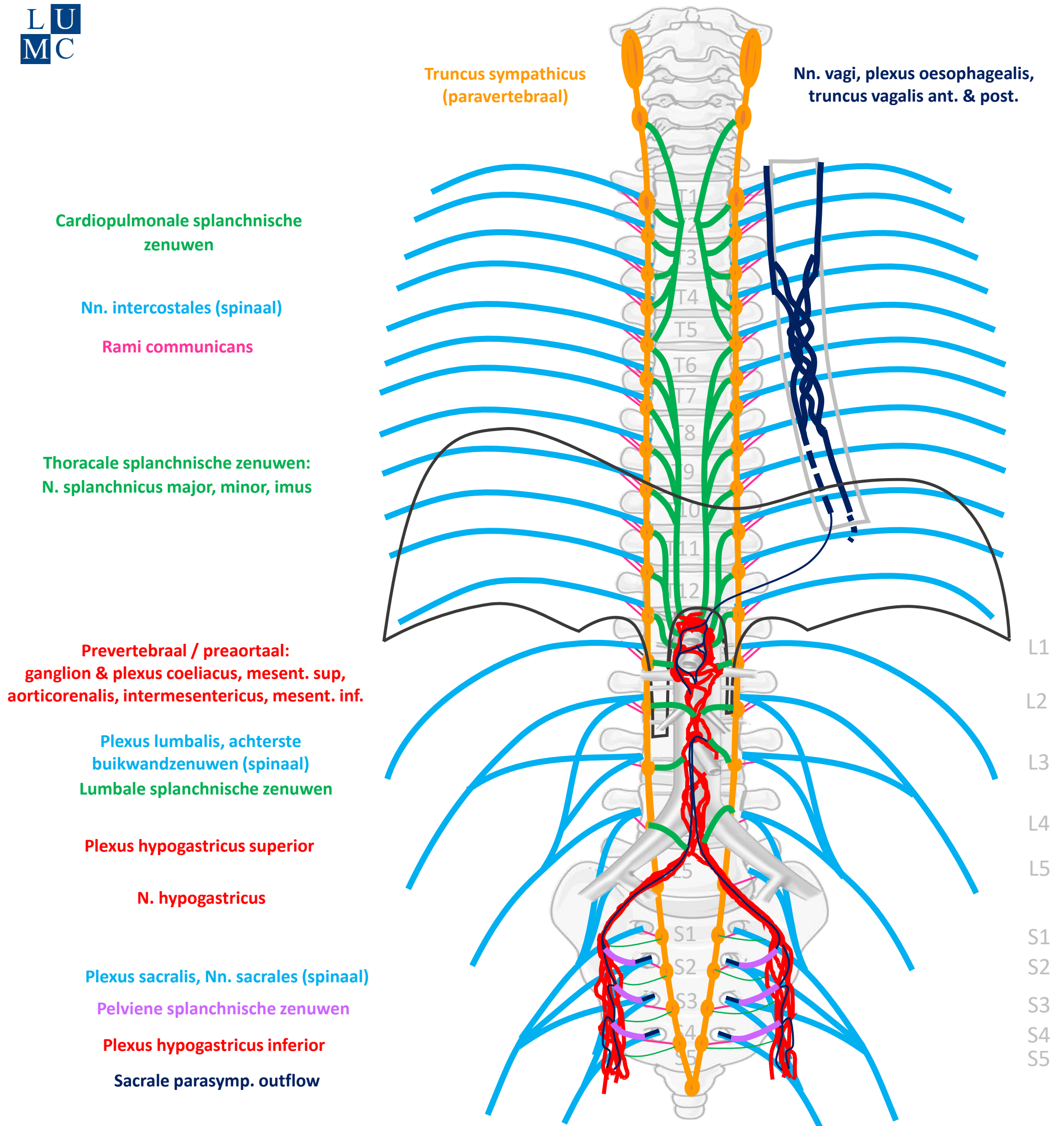
Onderdelen

1. Spinale zenuwen - (overwegend) **Somatisch**
2. Paravertebraal (truncus sympathicus)- **Sympathisch**
3. Prevertebraal/ preaortaal - (overwegend) **Sympathisch**
4. Nn. vagi - **Parasympathisch**
5. Sacraal - **Parasympathisch**

Verbindingen

1. Rami communicans (spinaal – truncus symp.) **Symp**
2. Splanchnische zenuwen (truncus symp. – preaortaal) **Symp**
3. Pelviene splanchnische zenuwen **Para**
(parasymp S2-S4 – plexus hypogastricus inferior)

Schema Autonome Zenuwstelsel



SYMP

CZS

PARASYMP

Rami communicans
Splanchnische zenuwen

Spinale zenuwen

Paravertebraal (truncus sympathicus)

Pelviene splanchnische zenuwen

Prevertebraal / preaortaal

N. vagus

ORGAAN

Download dit schema



v. 3, March 2024

By Paul Gobée, dept. Anatomy & Embryology, LUMC license CC BY NC SA

Bronnen: Gray's Anatomy 41st ed., Moore K et al, Clin. Oriented Anatomy, 8th ed.

"Servier - Drawing Vertebral column anterior view - no labels" by Servier Medical Art, license: CC BY

"Branches of the abdominal aorta - English labels" by Open Learning Initiative, license: CC BY-NC-SA

