

Autonome Zenuwstelsel Schematisch Opgebouwd

Paul Gobée, dept. Anatomy & Embryology,
LUMC

license CC BY NC SA



v3, Maart 2023

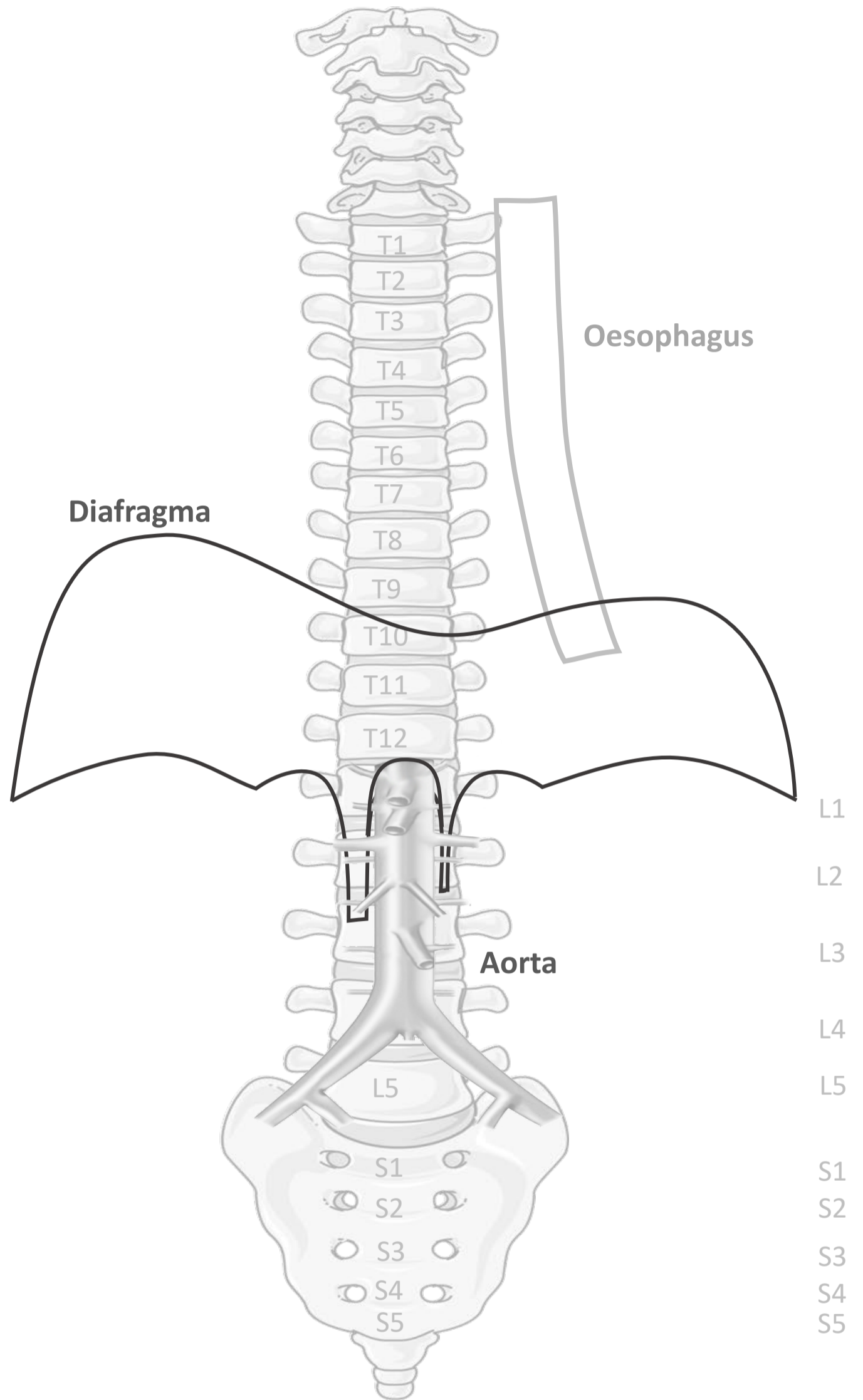
Zenuwstelsel in 5 onderdelen en 3 verbindingen

Onderdelen

1. Spinale zenuwen - **Somatisch**
2. Paravertebraal (truncus sympathicus)- **Sympathisch**
3. Prevertebraal/ preaortaal - **Sympathisch**
4. Nn. vagi - **Parasympathisch**
5. Sacraal - **Parasympathisch**

Verbindingen

1. Rami communicans **Sympathisch**
2. Splanchnische zenuwen **Sympathisch**
3. Pelviene splanchnische zenuwen **Parasympathisch**



By Paul Gobée, dept. Anatomy & Embryology, LUMC license CC BY NC SA

Bronnen: Gray's Anatomy 41st ed., Moore K et al, Clin. Oriented Anatomy, 8th ed.

"Servier - Drawing Vertebral column anterior view - no labels" by Servier Medical Art, license: CC BY

"Branches of the abdominal aorta - English labels" by Open Learning Initiative, license: CC BY-NC-SA



Zenuwstelsel

5 onderdelen

Onderdelen

Somatisch

1. Spinale zenuwen

Sympathisch

2. Paravertebraal (truncus sympathicus)
3. Prevertebraal/ preaortaal

Parasympathisch

4. Nn. vagi
5. Sacraal

Zenuwstelsel

5 onderdelen

Onderdelen

Somatisch

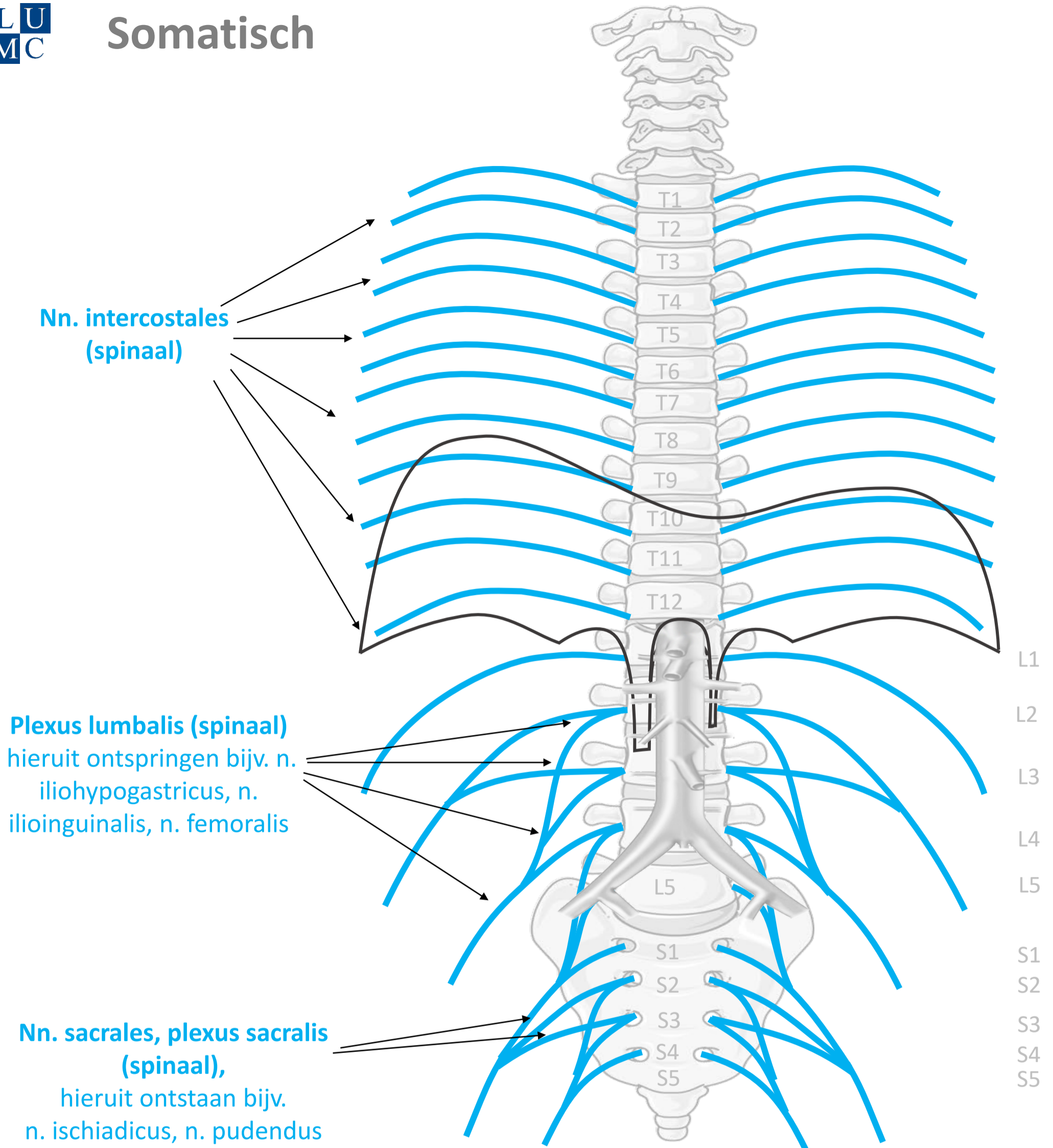
1. Spinale zenuwen

Sympathisch

2. Paravertebraal (truncus sympathicus)
3. Prevertebraal/ preaortaal

Parasympathisch

4. Nn. vagi
5. Sacraal



By Paul Gobée, dept. Anatomy & Embryology, LUMC license CC BY NC SA

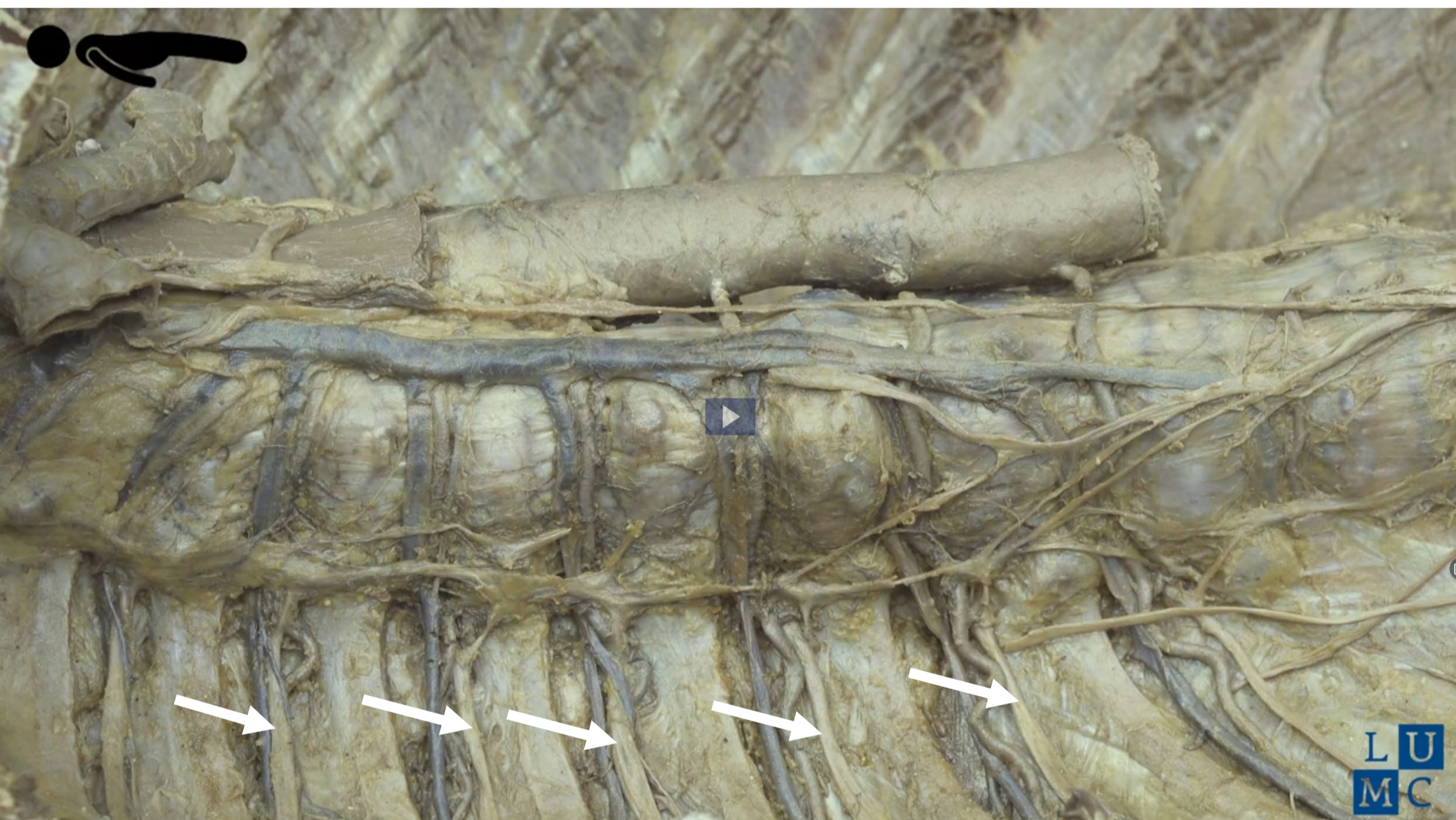
Bronnen: Gray's Anatomy 41st ed., Moore K et al, Clin. Oriented Anatomy, 8th ed.

"Servier - Drawing Vertebral column anterior view - no labels" by Servier Medical Art, license: CC BY

"Branches of the abdominal aorta - English labels" by Open Learning Initiative, license: CC BY-NC-SA



Nn. intercostales



Zenuwstelsel

5 onderdelen

Onderdelen

Somatisch

1. Spinale zenuwen

Sympathisch

2. Paravertebraal (truncus sympathicus)
3. Prevertebraal/ preaortaal

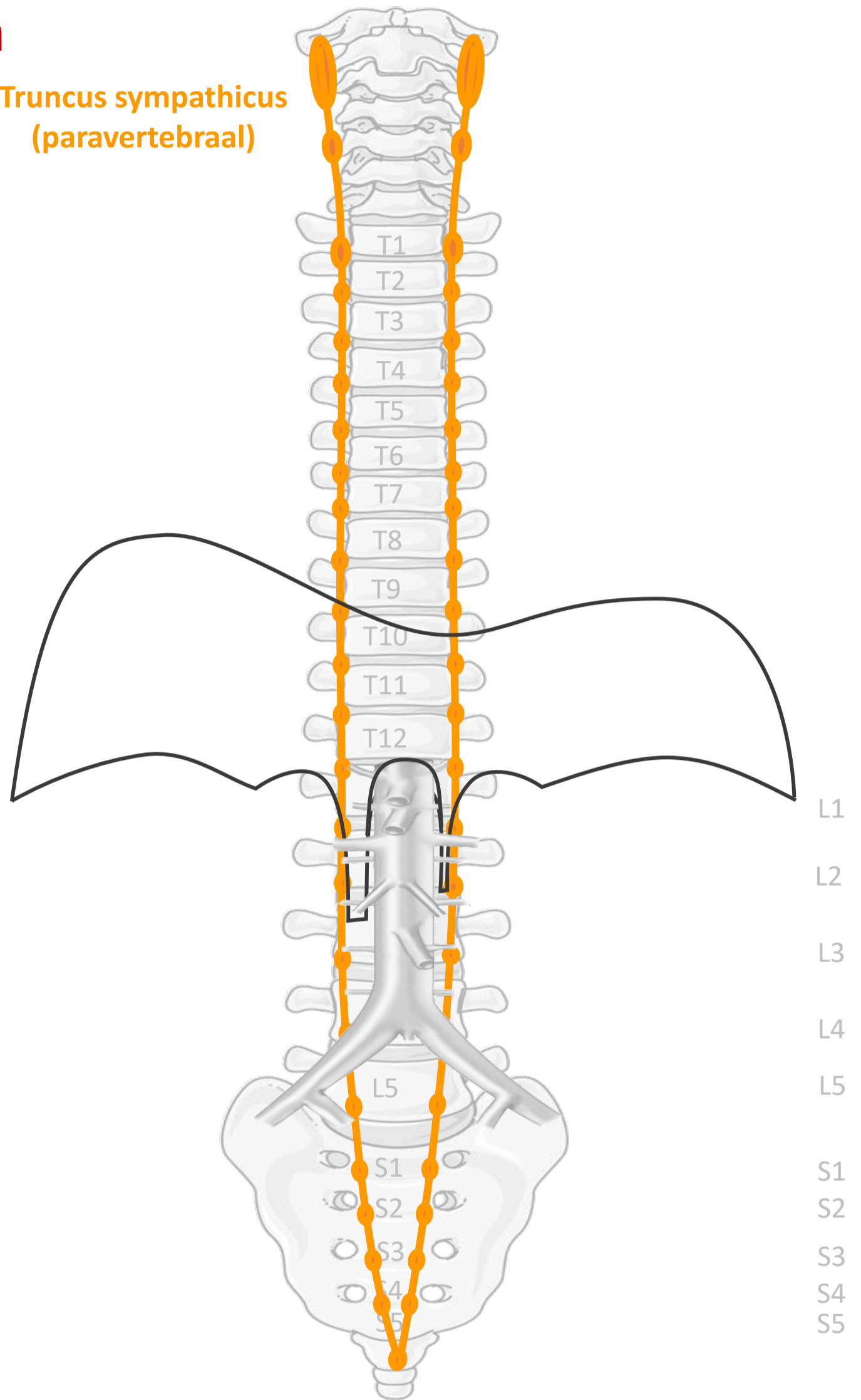
Parasympathisch

4. Nn. vagi
5. Sacraal


Sympathisch

Truncus sympathicus
(paravertebraal)

Strengen van met elkaar
verbonden ganglia aan
weerszijden van de wervelkolom



Truncus sympathicus



Zenuwstelsel

5 onderdelen

Onderdelen

Somatisch

1. Spinale zenuwen

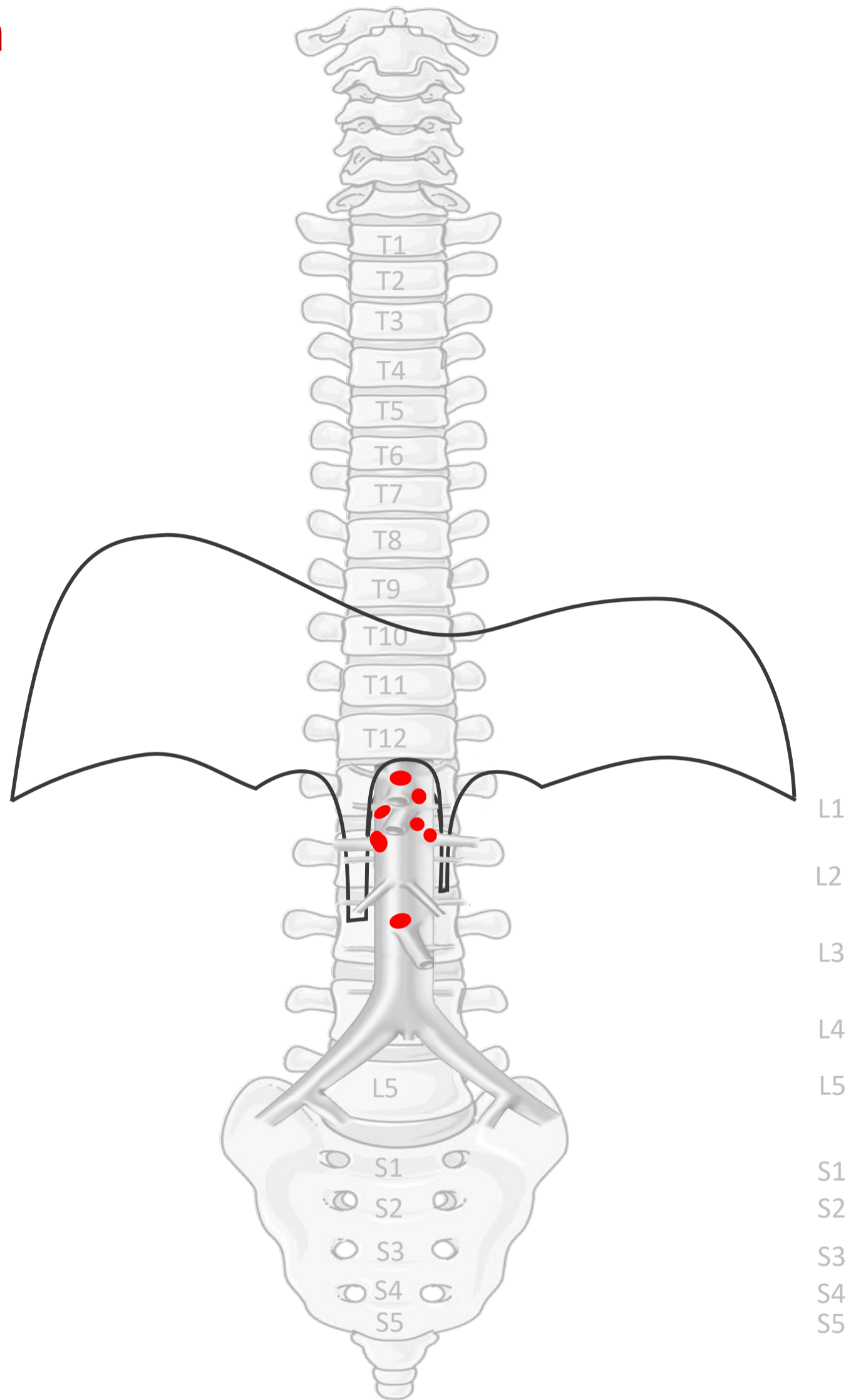
Sympathisch

2. Paravertebraal (truncus sympathicus)
3. Prevertebraal/ preaortaal

Parasympathisch

4. Nn. vagi
5. Sacraal

Prevertebraal / preaortaal :
ganglia coeliaca,
ganglion mesent. sup,
ganglia aorticorenalia
ganglia mesent. inf



Gemengd para/symp maar overwegend Sympathisch

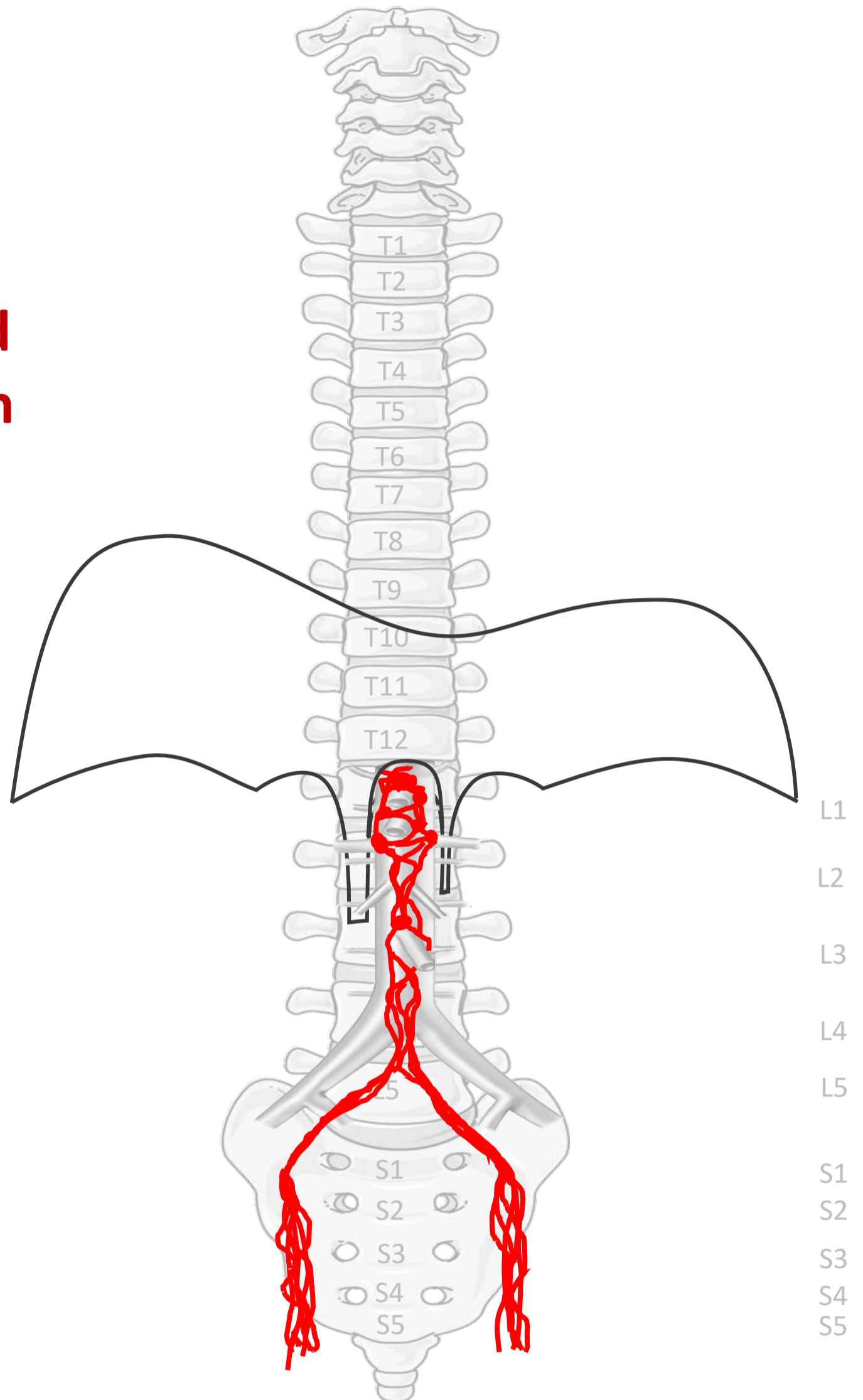
Prevertebraal / preaortaal :

plexus coeliacus,
plexus mesent. sup,
plexus intermesentericus,
plexus mesent. inf.

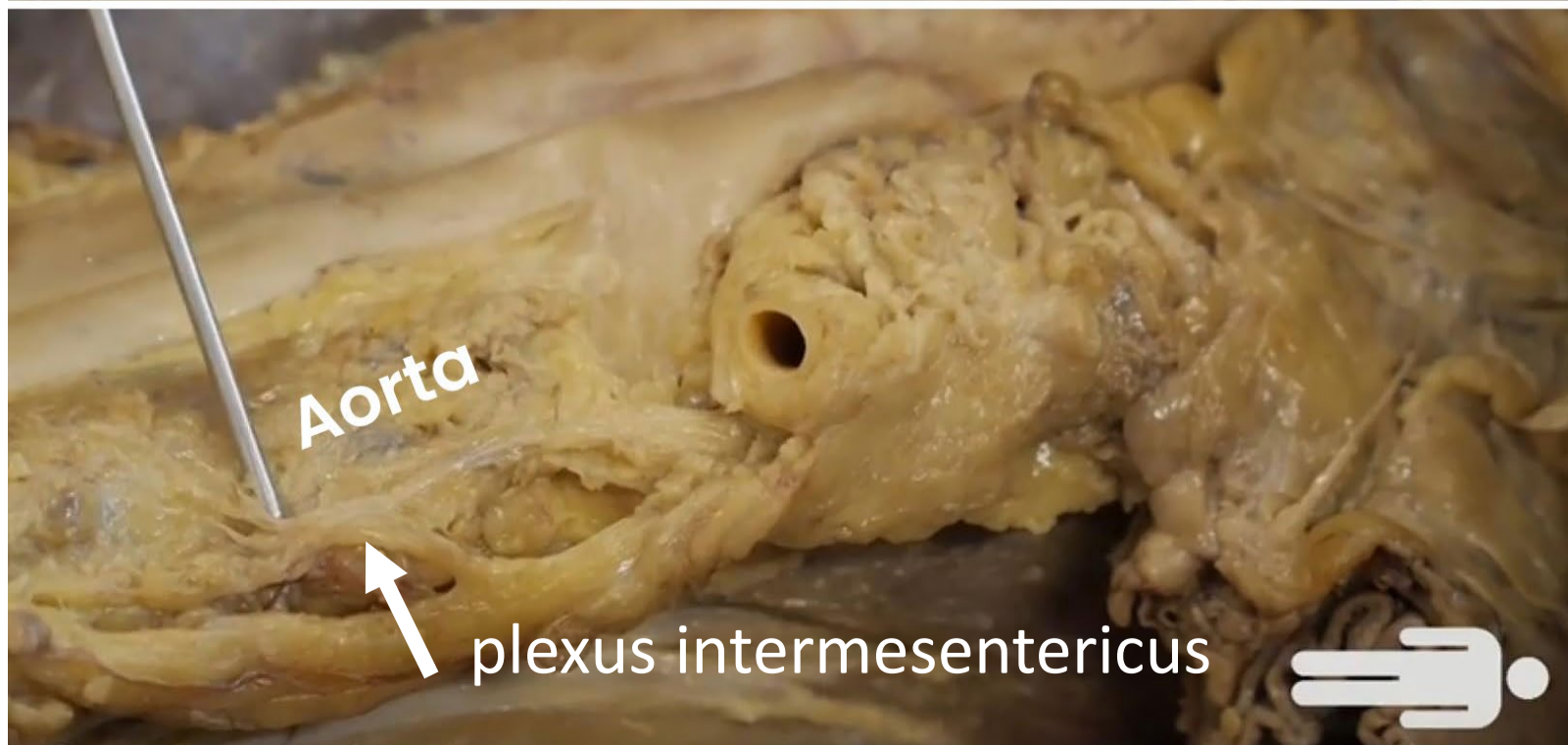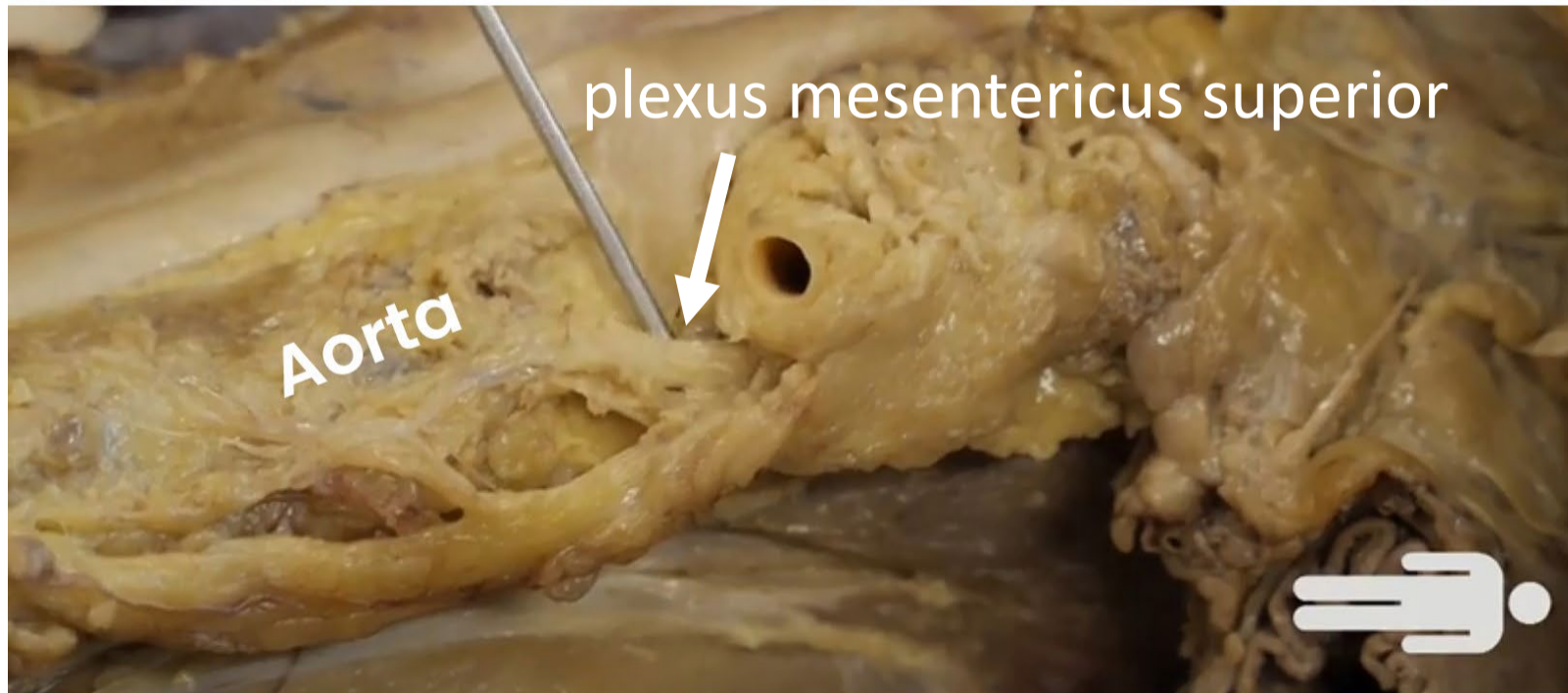
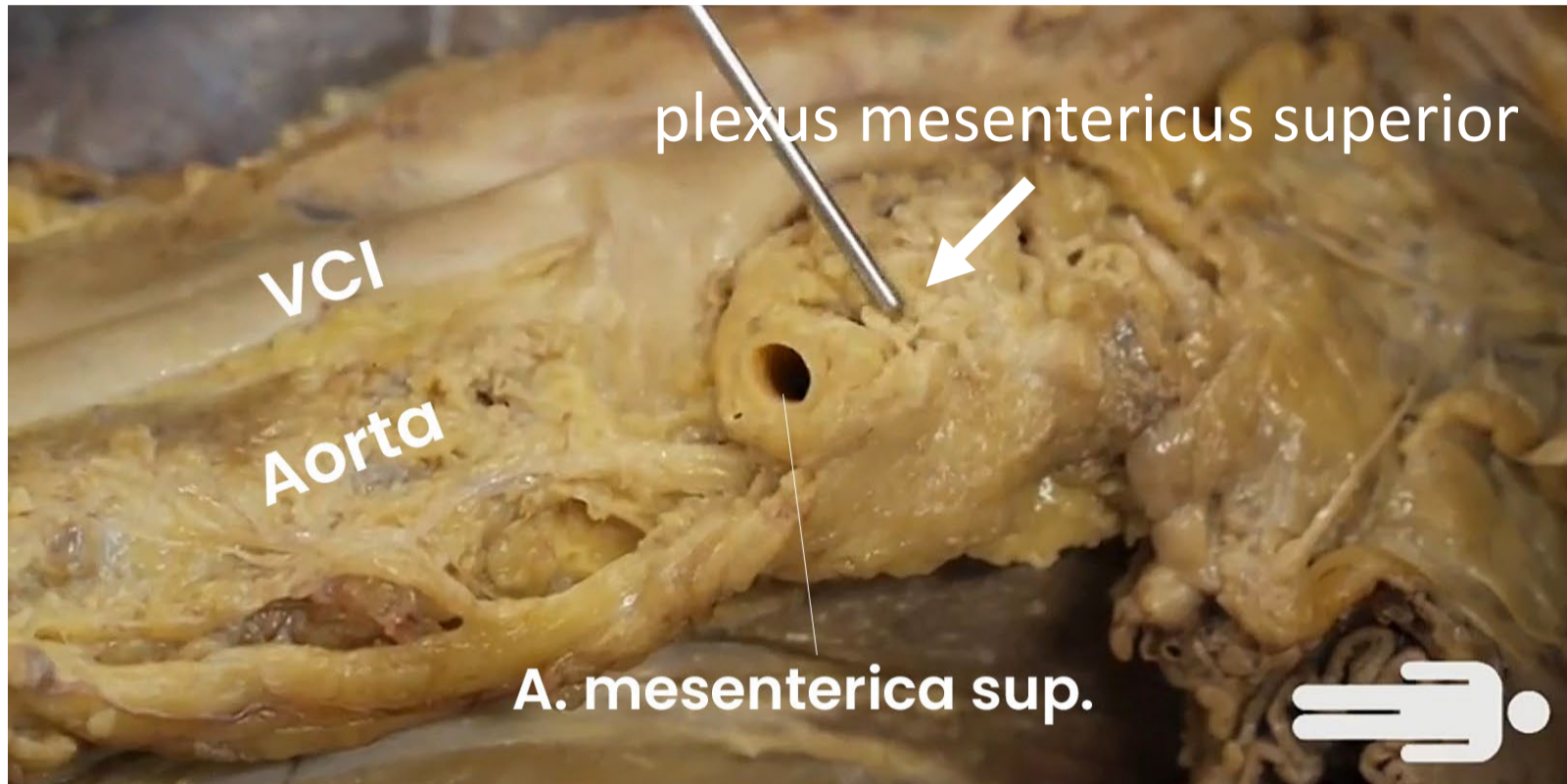
plexus hypogastr. sup.

n. hypogastricus

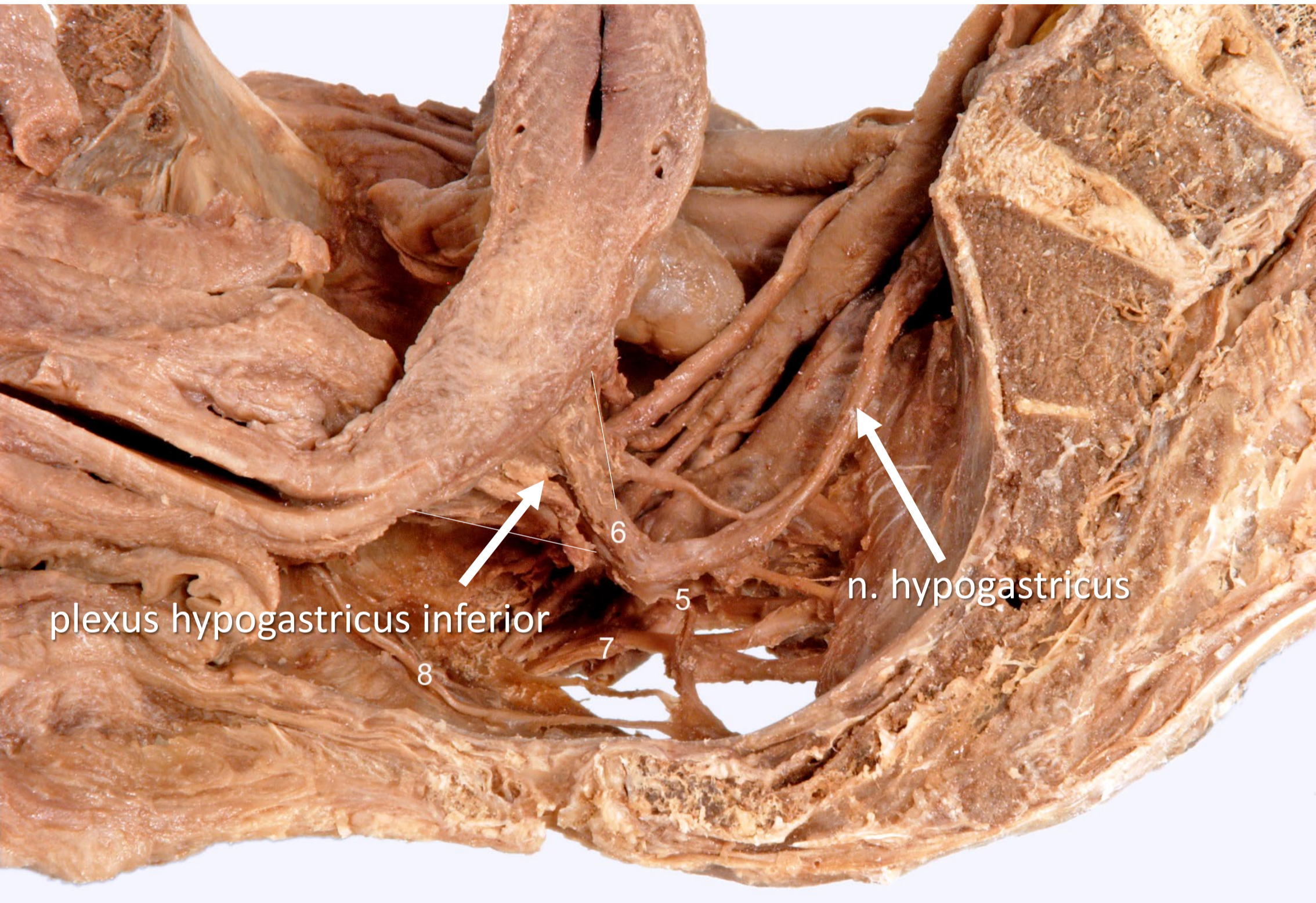
plexus hypogastr. inf.



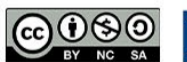Prevertebrale/ preaortale plexi & ganglia



Prevertebrale/ preaortale plexi & ganglia



Dissection by Kees Maas MD PhD



"Leiden, Maas Photo 15 - Sagittal view of the female pelvic nerves (plastination specimen) - number labels" by Kees (C.P.) Maas, LUMC, Marco C. DeRuiter, LUMC and J. Lens, license: [CC BY-NC-SA](https://creativecommons.org/licenses/by-nc-sa/4.0/)

shot uit video , Leiden MOOC 6.4 - Video Anatomy on the Table: Innervation of the viscera – abdomen by Bas Boekestijn, dept. Anatomy & Embryology, LUMC license [CC BY NC SA](https://creativecommons.org/licenses/by-nc-sa/4.0/)
<https://anatomytool.org/content/leiden-mooc-64-video-anatomy-table-innervation-viscera-abdomen>



Zenuwstelsel

5 onderdelen

Onderdelen

Somatisch

1. Spinale zenuwen

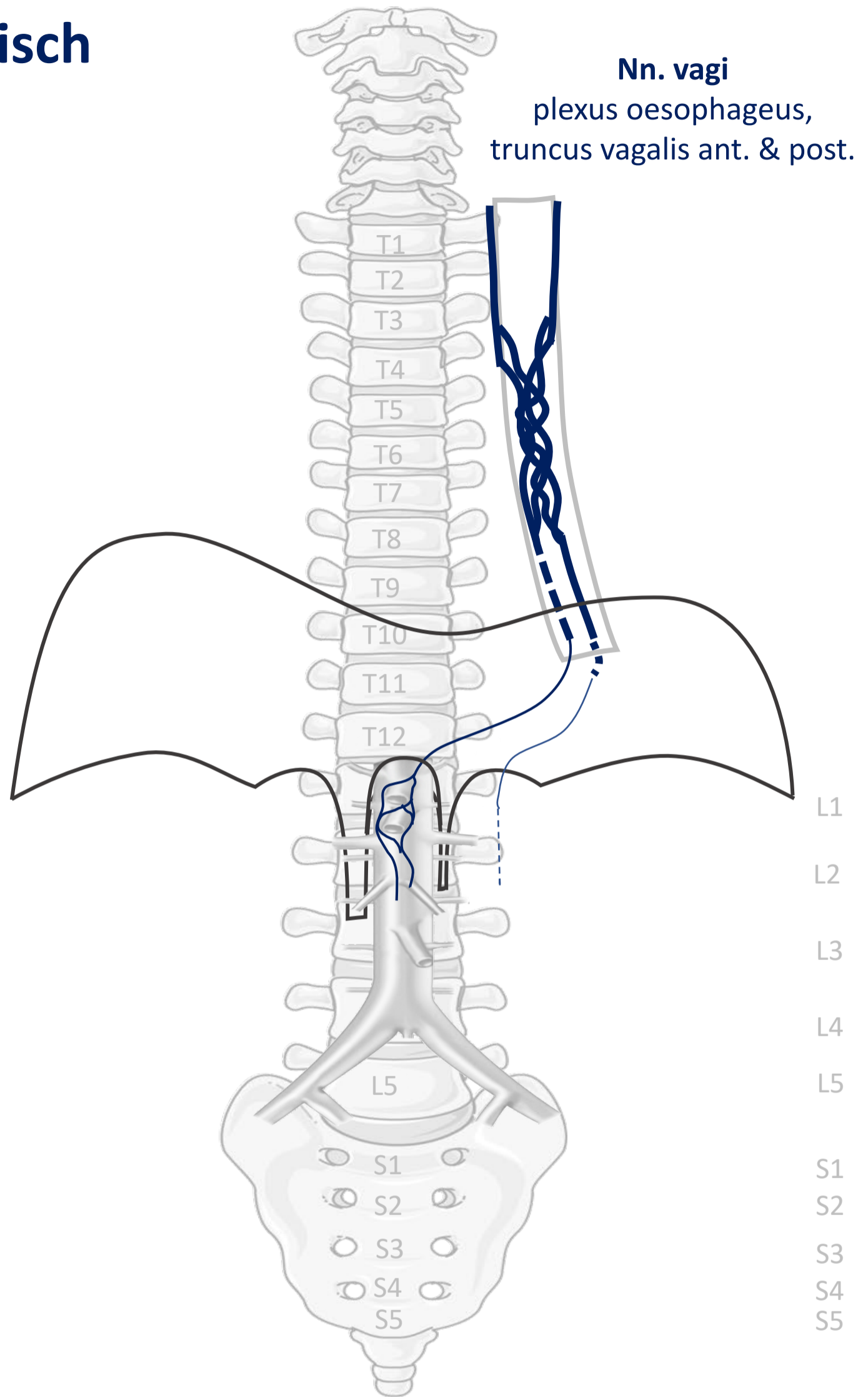
Sympathisch

2. Paravertebraal (truncus sympathicus)
3. Prevertebraal/ preaortaal

Parasympathisch

4. Nn. vagi
5. Sacraal

Parasympathisch



Zenuwstelsel

5 onderdelen

Onderdelen

Somatisch

1. Spinale zenuwen

Sympathisch

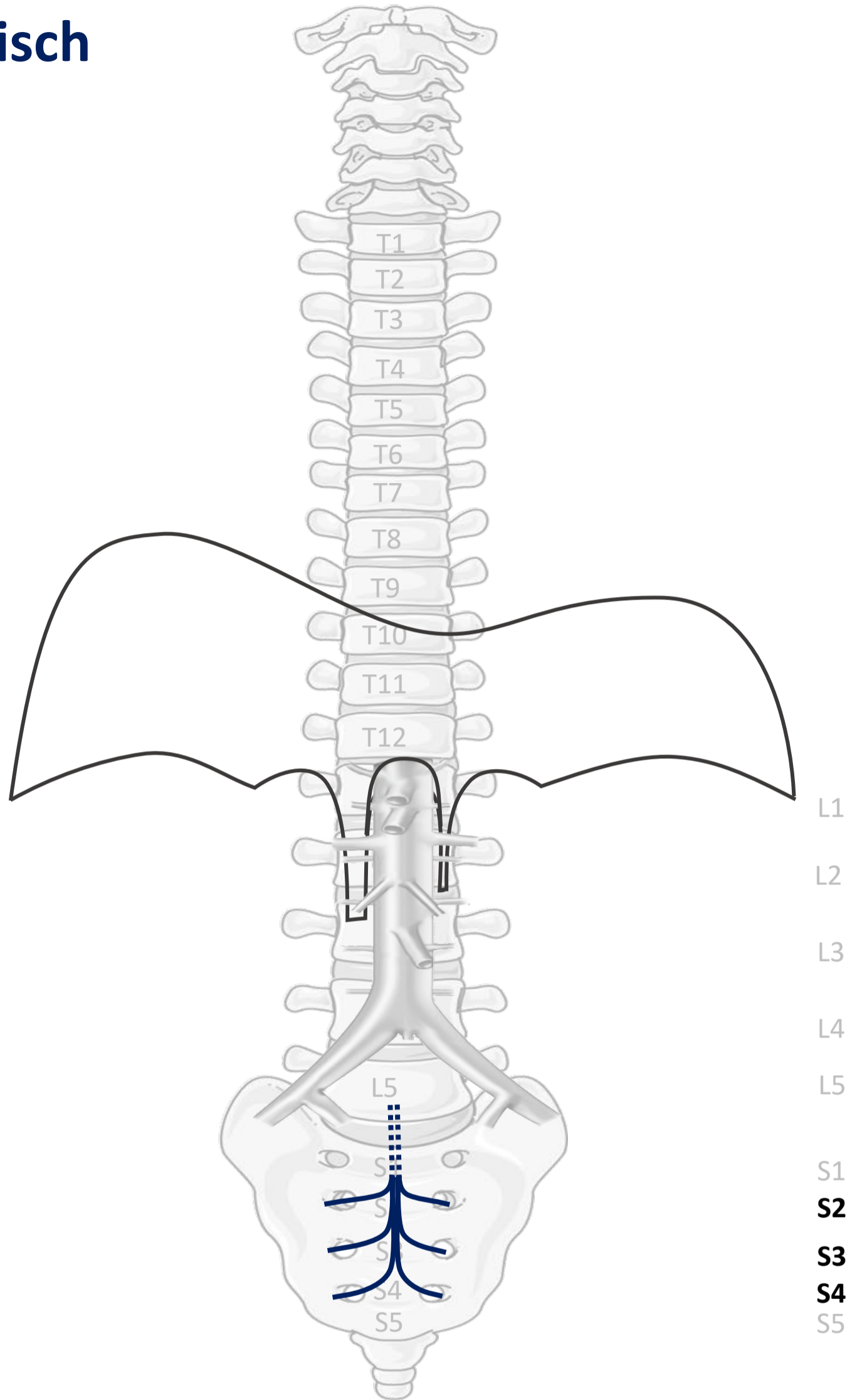
2. Paravertebraal (truncus sympathicus)
3. Prevertebraal/ preaortaal

Parasympathisch

4. Nn. vagi
5. Sacraal (S2-S4)



Parasympathisch



Sacrale parasymp. outflow
→ S2-S4



3 verbindingen

Verbindingen

1. Rami communicans (*sympathisch*)
2. Splanchnische zenuwen (*sympathisch*)
3. Pelviene splanchnische zenuwen (*parasympathisch*)

3 verbindingen

Verbindingen

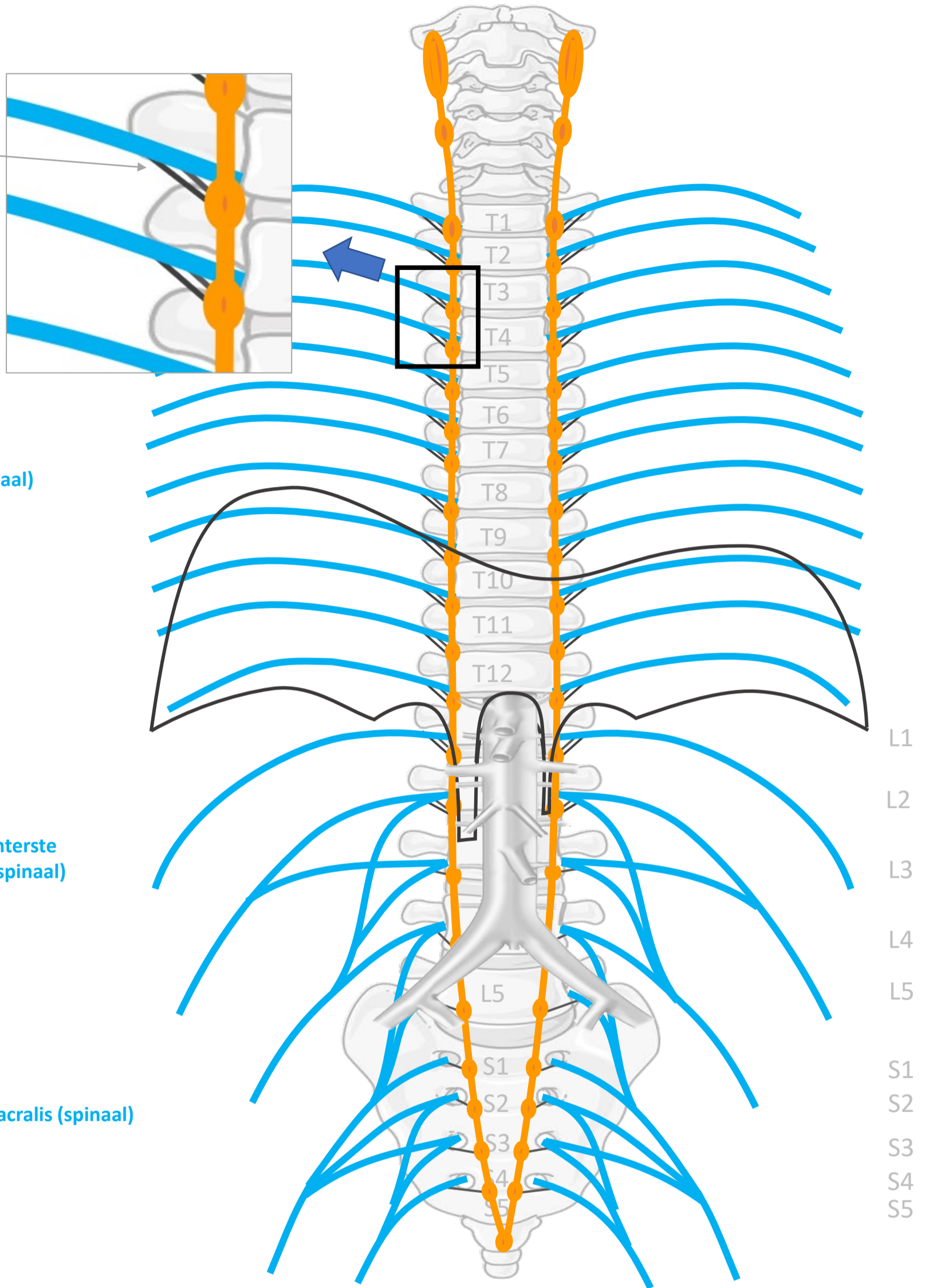
1. Rami communicans (*sympathisch*)
2. Splanchnische zenuwen (*sympathisch*)
3. Pelviene splanchnische zenuwen (*parasympathisch*)

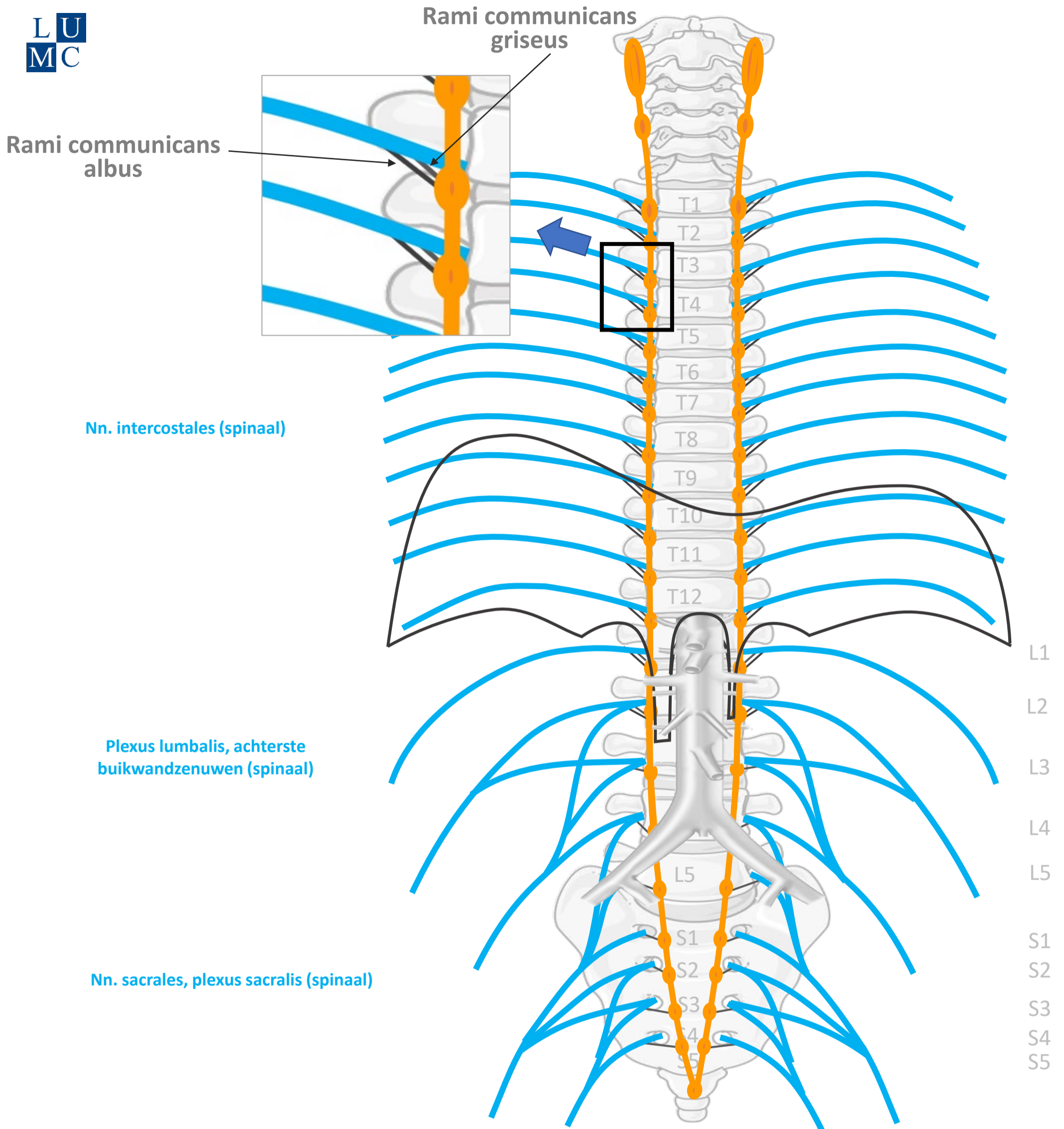
Rami communicans
 verbinden
 spinale zenuwen
 met
 Truncus sympathicus
 (paravertebraal)

Nn. intercostales (spinaal)

Plexus lumbalis, achterste
 buikwandzenuwen (spinaal)

Nn. sacrales, plexus sacralis (spinaal)





NB: Vanaf L3/L4 naar beneden zijn er alleen nog ramus communicans griseus, maar geen ramus communicans albus meer.

By Paul Gobée, dept. Anatomy & Embryology, LUMC license CC BY NC SA


Bronnen: Gray's Anatomy 41st ed., Moore K et al, Clin. Oriented Anatomy, 8th ed.

"Servier - Drawing Vertebral column anterior view - no labels" by Servier Medical Art, license: CC BY

"Branches of the abdominal aorta - English labels" by Open Learning Initiative, license: CC BY-NC-SA



Rami communicans



3 verbindingen

Verbindingen

1. Rami communicans (*sympathisch*)
2. Splanchnische zenuwen (*sympathisch*)
3. Pelviene splanchnische zenuwen (*parasympathisch*)

Splanchnische zenuwen (sympathisch)

Voorzien inwendige organen (*splanchn-*) sympathisch:

- 1. Cardiopulmonale splanchnische zenuwen**
naar hart, longen, oesophagus
- 2. Thoracale splanchnische zenuwen**
voorzien *buikorganen*:
lever, milt, pancreas, nieren,
maag t/m colon transversum (*voordarm en
middendarm*)
- 3. Lumbale splanchnische zenuwen**
voorzien *buik- en bekkenorganen*:
colon descendens t/m rectum (*einddarm*),
blaas, uterus, ovariae, prostaat

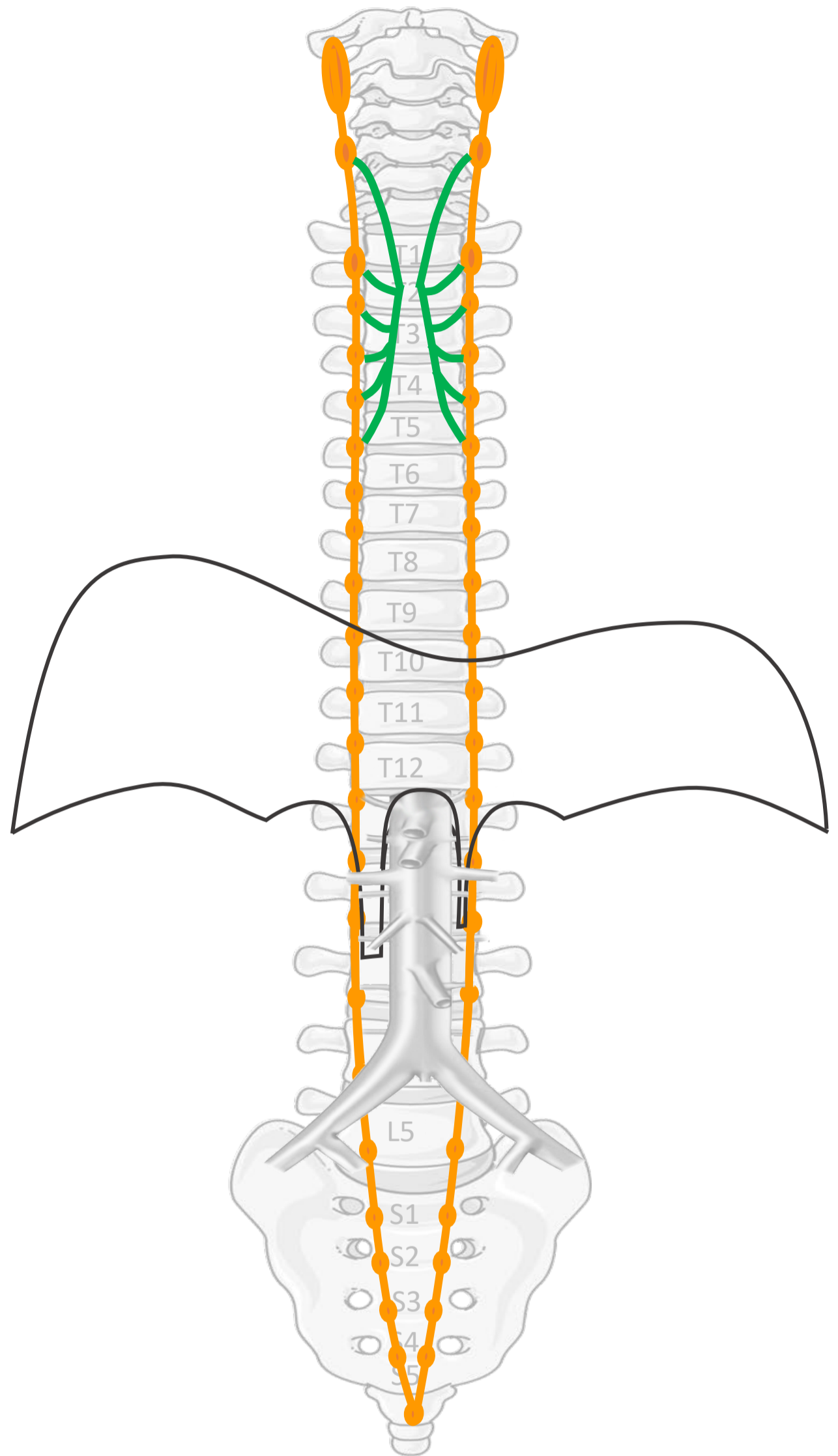
Splanchnische zenuwen (sympathisch)

Voorzien inwendige organen (*splanchn-*) sympathisch:

Cardiopulmonale splanchnische zenuwen
(komen van *truncus sympathicus* ~C4 – T5)
naar hart, longen, oesophagus

Cardiopulmonale splanchnische zenuwen

van
Truncus sympathicus (~C4 – T5)
(paravertebraal)
naar
hart, longen, oesophagus



Splanchnische zenuwen (sympathisch)

Voorzien inwendige organen (*splanchn-*) sympathisch:

Thoracale splanchnische zenuwen

(komen van truncus sympathicus T5-T12)

naar **prevertebrale / preaortale plexi/ ganglia**

voorzien *buikorganen*:

lever, milt, pancreas, nieren,

maag t/m colon transversum (*voordarm en middendarm*)

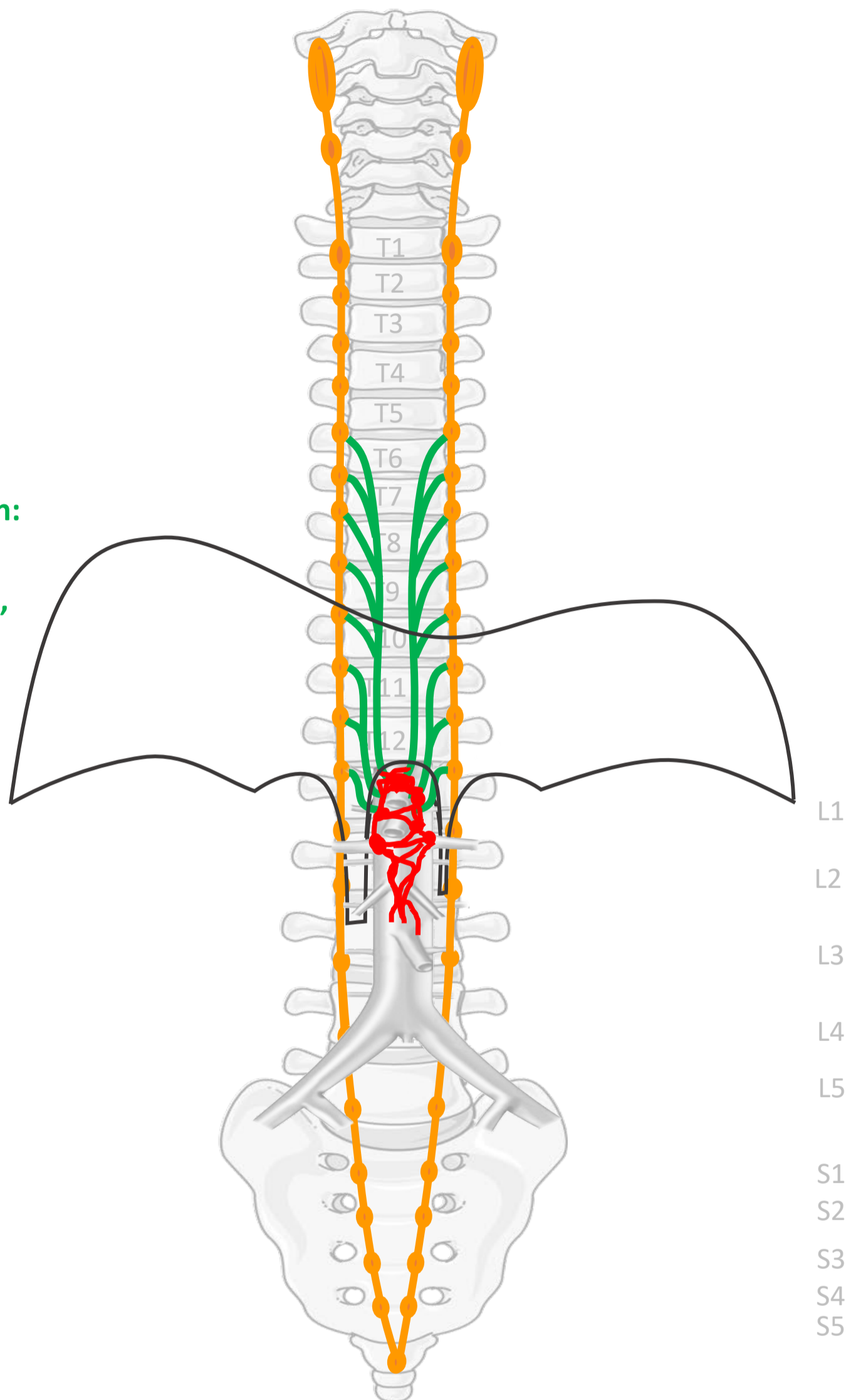
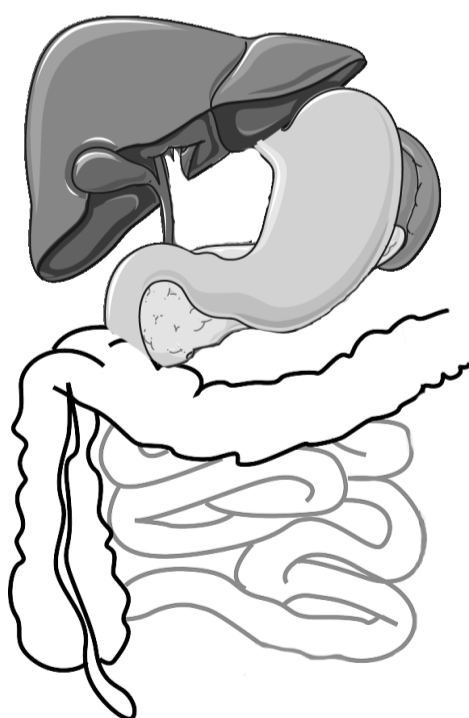
Thoracale splanchnische zenuwen:

**N. splanchnicus major (T5-T9),
N. splanchnicus minor (T10-T11),
N. splanchnicus imus (T12)**

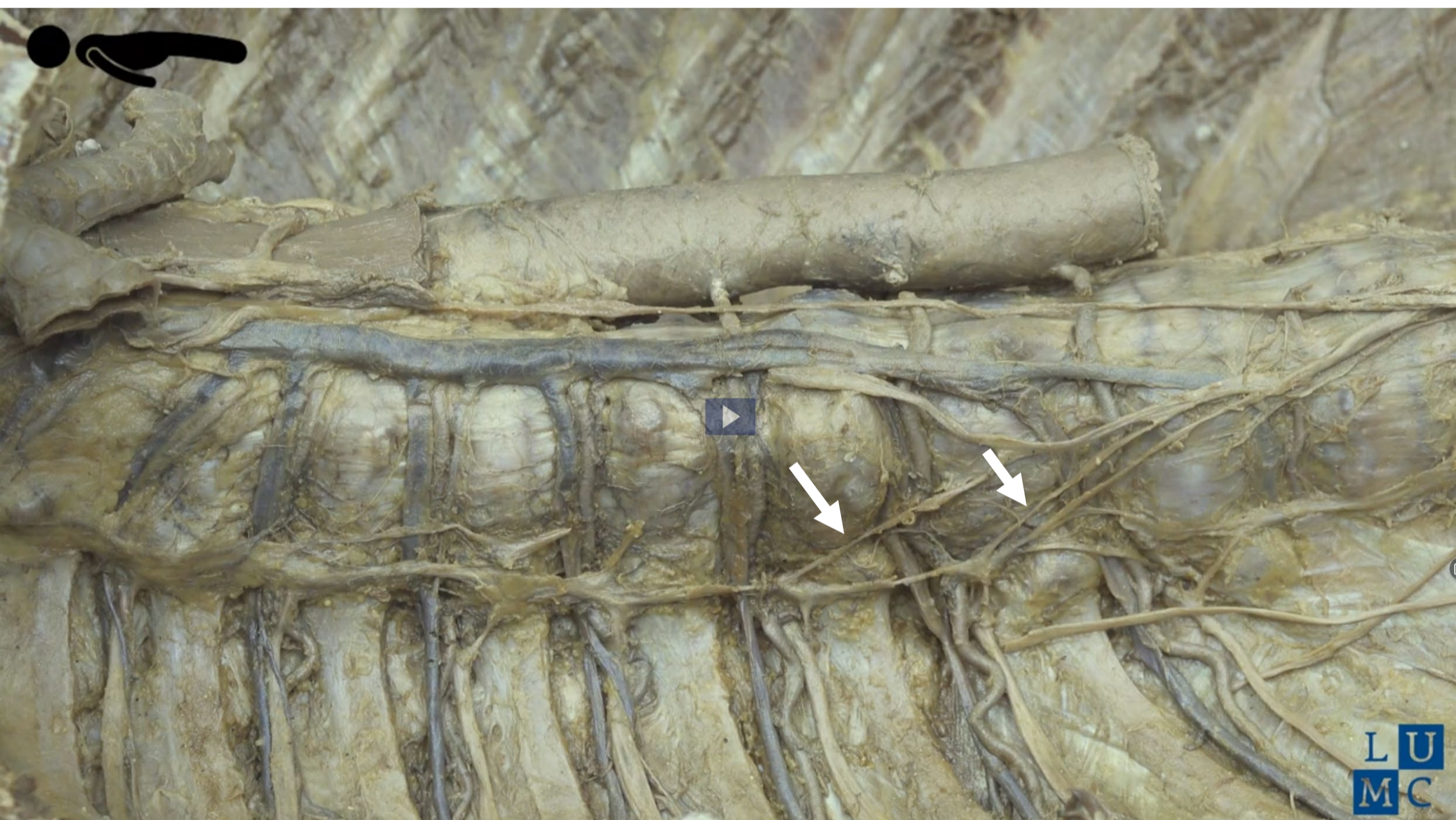
van
**Truncus sympathicus (T5-T12)
(paravertebraal)**

naar
**Prevertebrale / preaortale
ganglia & plexi:
ganglia & plexus coeliacus,
ganglion & plexus mesent. sup,
ganglia aorticorenalia,
plexus intermesentericus,
plexus mesent. inf.**

Prikkels daarna verder naar



Thoracale splanchnische zenuwen N. splanchnicus major, minor, imus



Splanchnische zenuwen (sympathisch)

Voorzien inwendige organen (*splanchn-*) sympathisch:

Lumbale splanchnische zenuwen

(komen van truncus sympathicus L1-~L3)

naar **prevertebrale / preaortale plexi/ ganglia**

voorzien *buik- en bekkenorganen*:

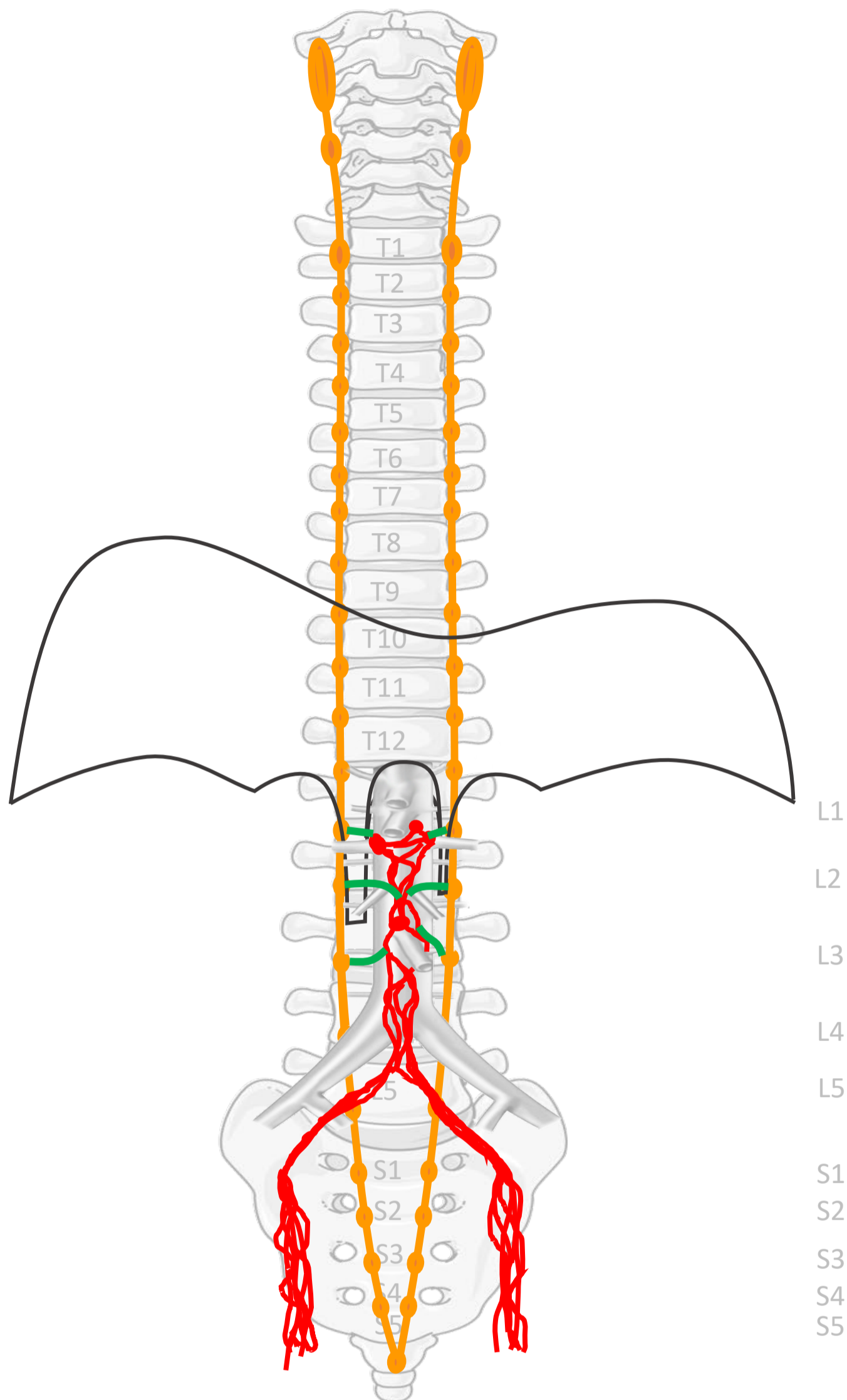
colon descendens t/m rectum (*einddarm*),

blaas, uterus, ovariae, prostaat

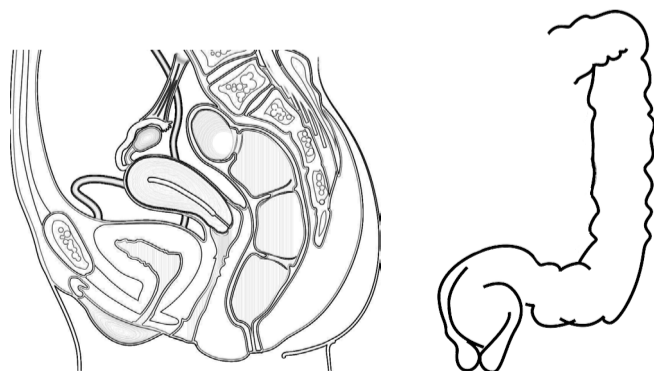
Lumbale splanchnische zenuwen

van
Truncus sympathicus (L1 - ~L3)
(paravertebraal)

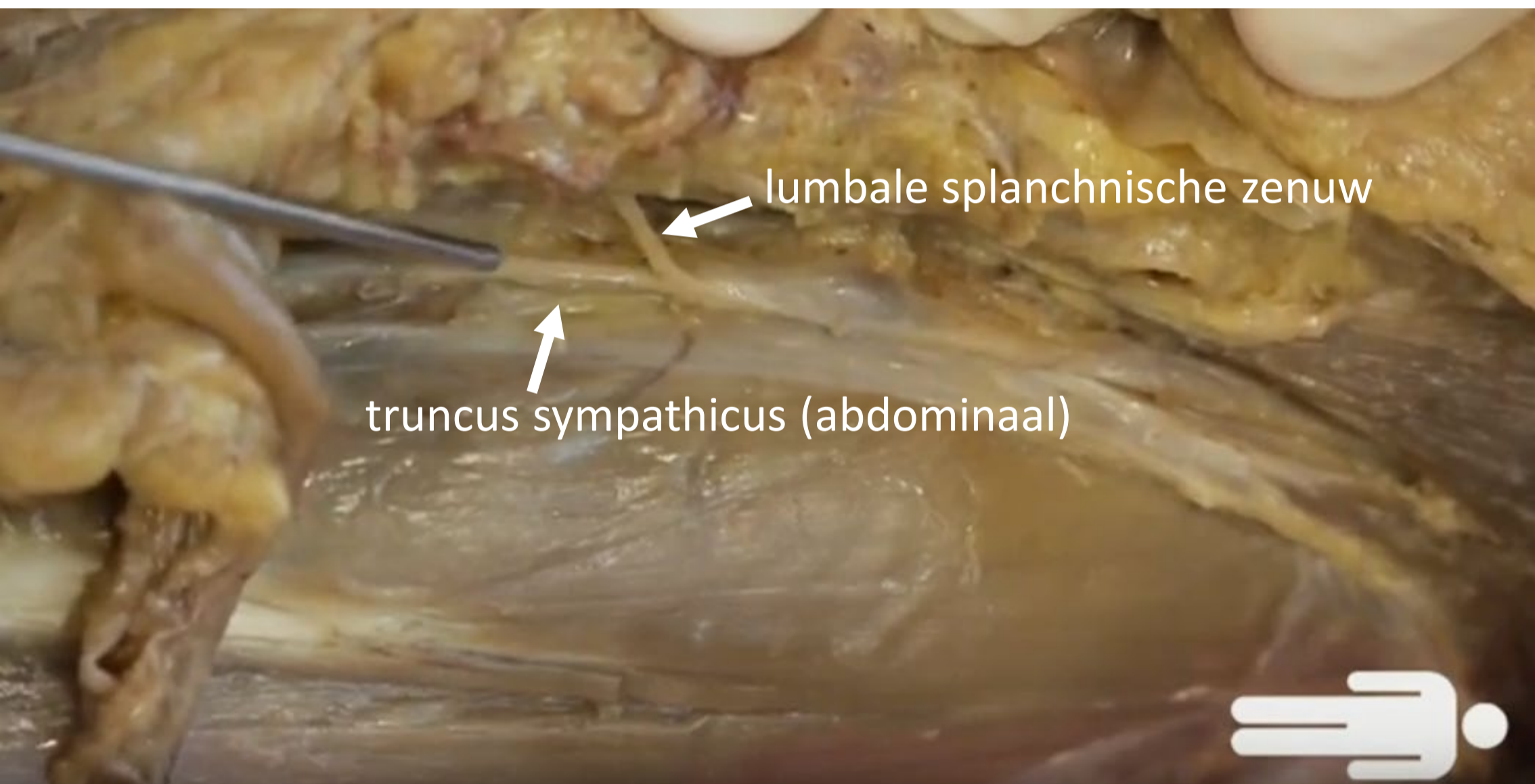
naar
Prevertebrale / preaortale ganglia & plexi:
plexus intermesentericus,
ganglia & plexus mesent. inf.,
plexus hypogastricus sup.,
n. hypogastricus,
plexus hypogastricus inf.



Prikkels daarna verder naar



Lumbale splanchnische zenuwen



3 verbindingen

Verbindingen

1. Rami communicans (*sympathisch*)
2. Splanchnische zenuwen (*sympathisch*)
3. Pelviene splanchnische zenuwen (*parasympathisch*)

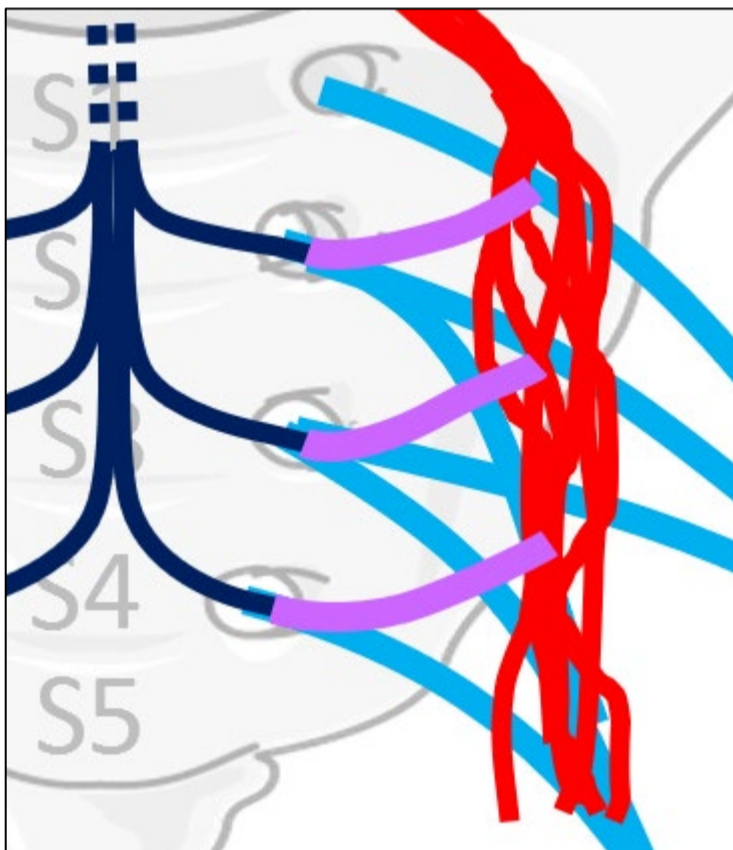
Pelviene splanchnische zenuwen (parasymphathisch)

Verbinden

Sacrale parasymphathische outflow (S2-S4)

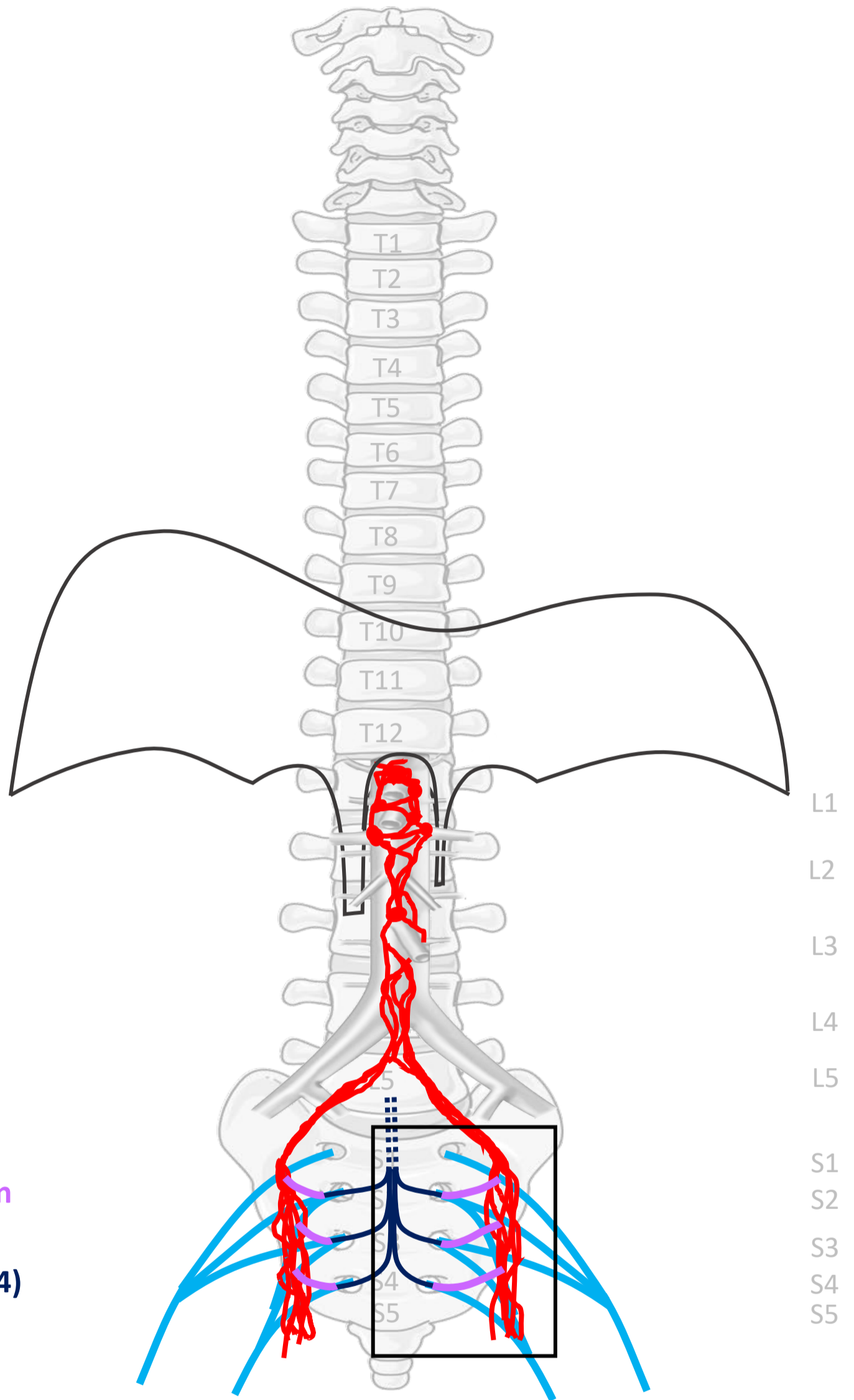
met

Plexus hypogastricus inferior



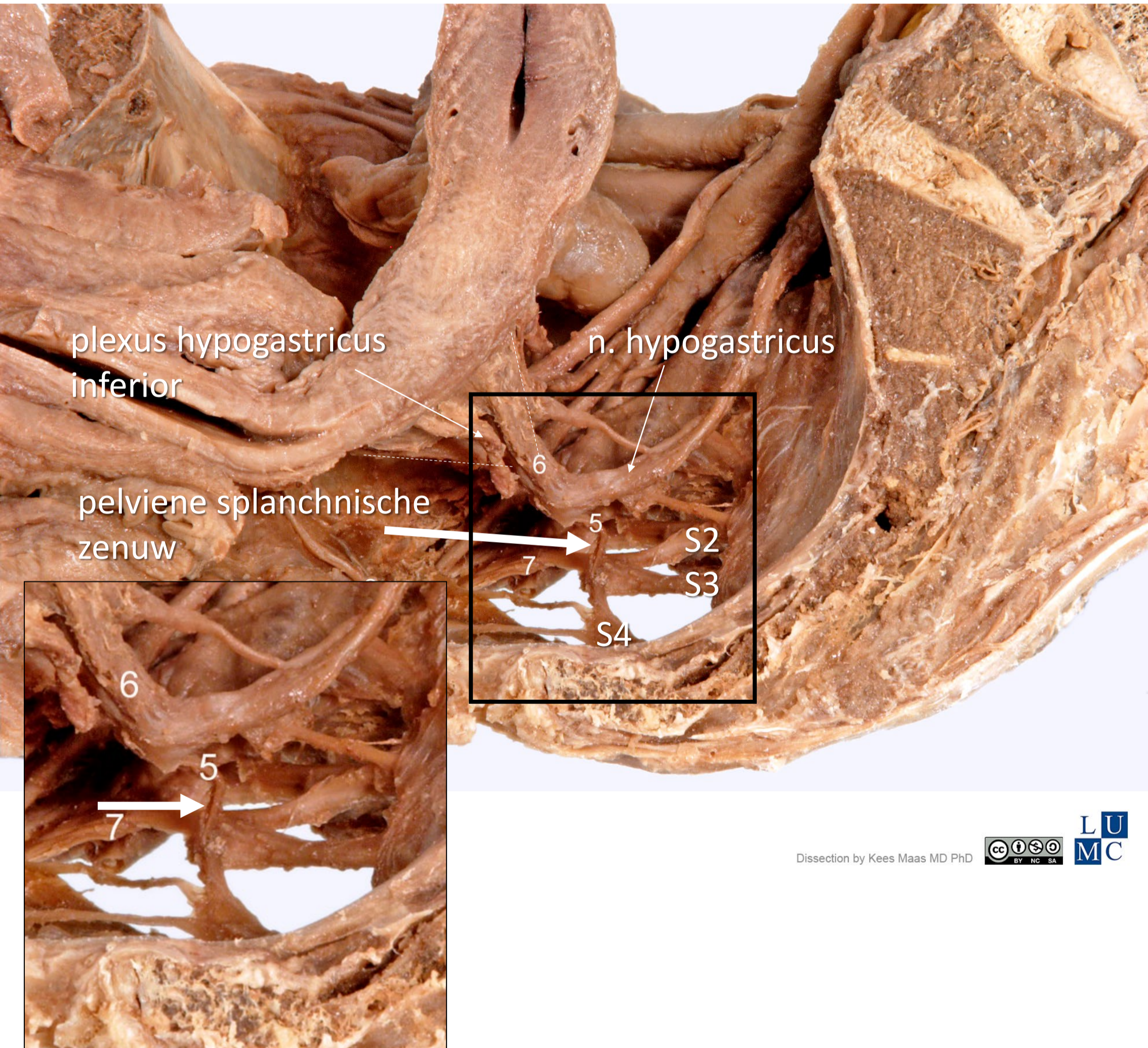
Pelviene splanchnische zenuwen

Verbinden
Sacrale parasymp. outflow (S2-S4)
met
Plexus hypogastr. inf.



Nn. sacrales, plexus sacralis (spinaal)

Pelviene splanchnische zenuw



Dissection by Kees Maas MD PhD



Zenuwstelsel in 5 onderdelen en 3 verbindingen

Onderdelen

1. Spinale zenuwen - **Somatisch**
2. Paravertebraal (truncus sympathicus)- **Sympathisch**
3. Prevertebraal/ preaortaal - **Sympathisch**
4. Nn. vagi - **Parasympathisch**
5. Sacraal - **Parasympathisch**

Verbindingen

1. Rami communicans (spinaal – **truncus symp.**)
2. Splanchnische zenuwen (**truncus symp. – preaortaal**)
3. Pelviene splanchnische zenuwen
(**parasymp S2-S4 – plexus hypogastricus inferior**)

Truncus sympathicus
(paravertebraal)

Nn. vagi, plexus oesophagealis,
truncus vagalis ant. & post.

Cardiopulmonale splanchnische
zenuwen

Nn. intercostales (spinaal)

Rami communicans

Thoracale splanchnische zenuwen:
N. splanchnicus major, minor, imus

Prevertebraal / preaortaal:
ganglion & plexus coeliacus, mesent. sup,
aorticorenalis, intermesentericus, mesent. inf.

Plexus lumbalis, achterste
buikwandzenuwen (spinaal)
Lumbale splanchnische zenuwen

Plexus hypogastr. sup.

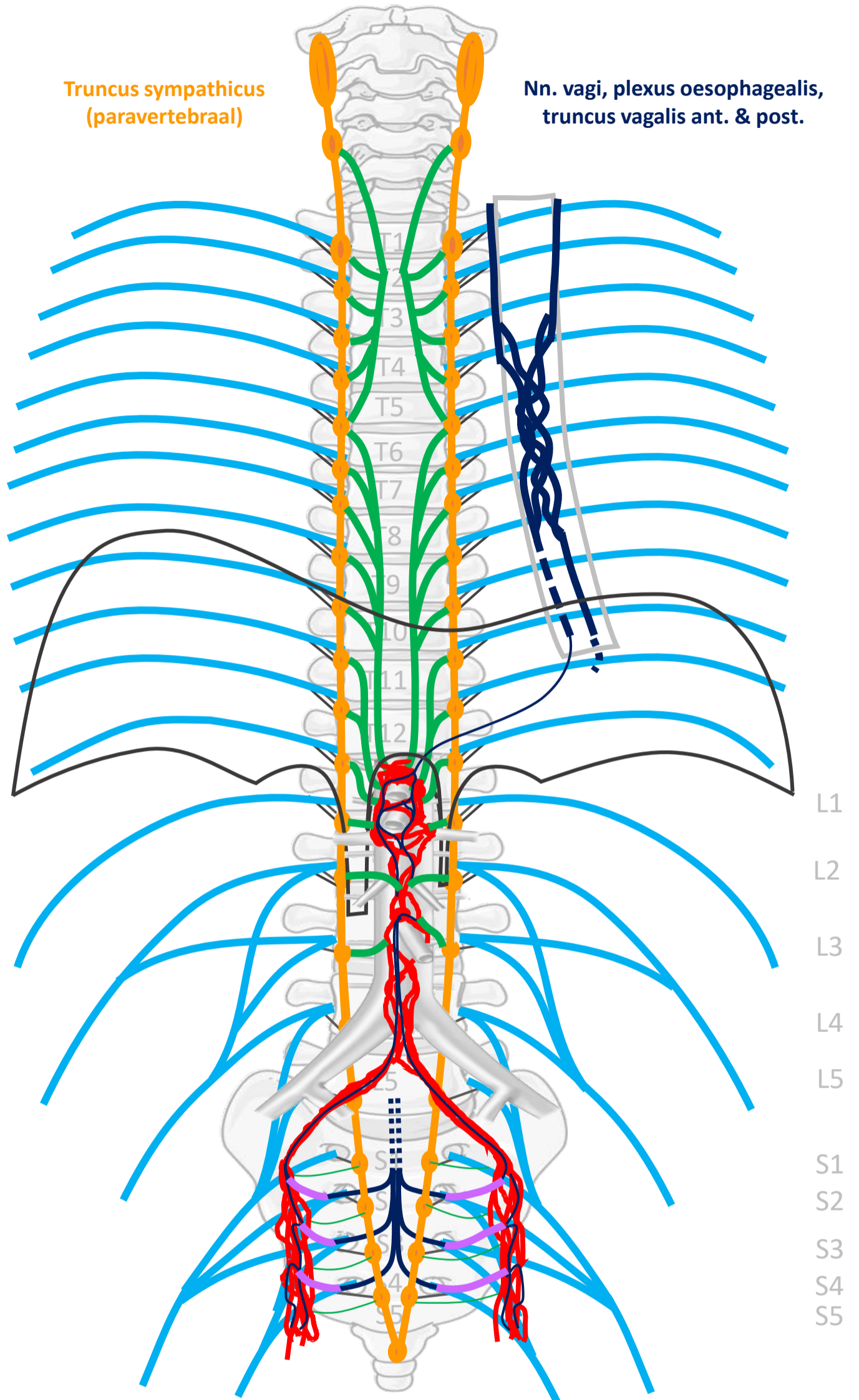
N. hypogastricus

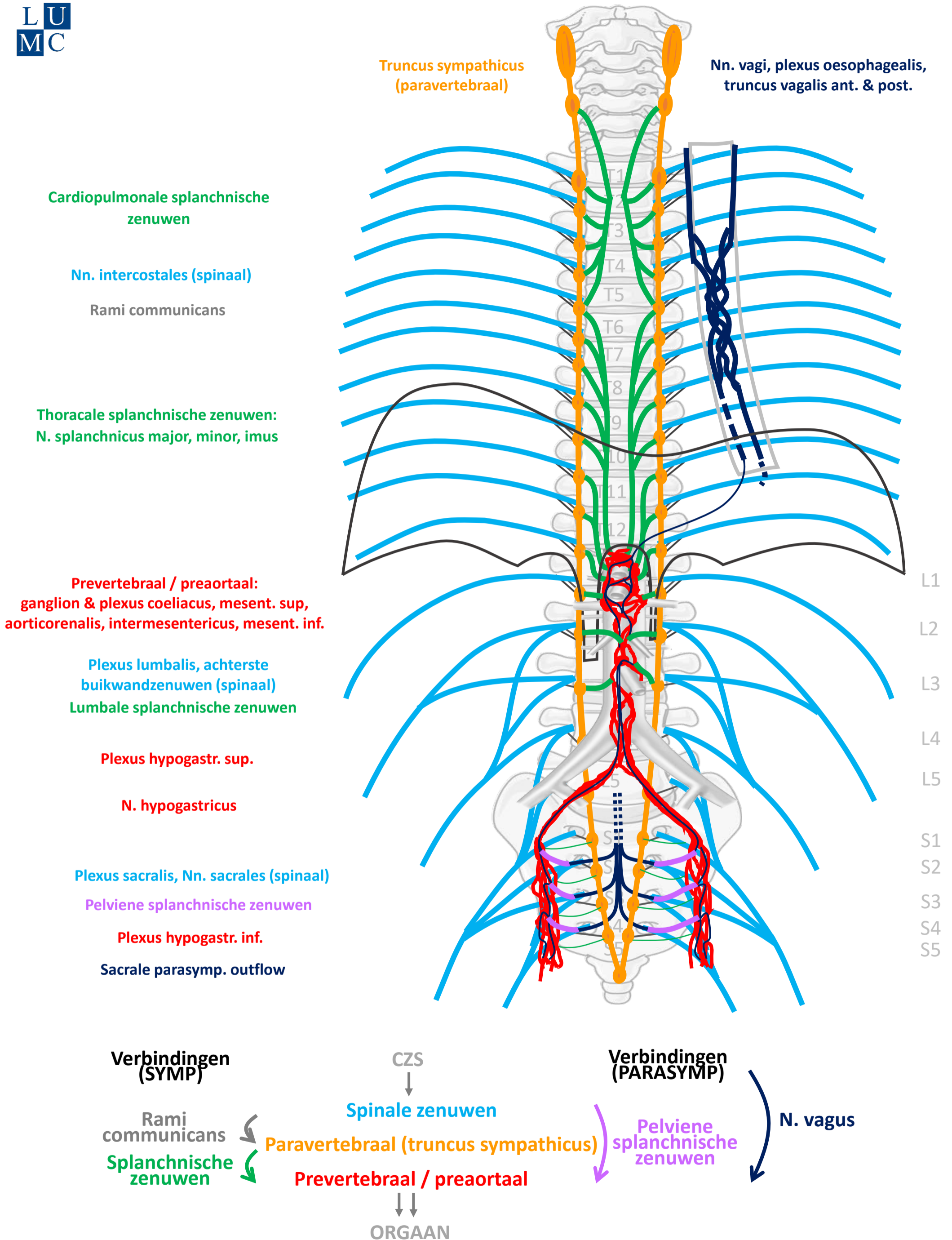
Plexus sacralis, Nn. sacrales (spinaal)

Pelviene splanchnische zenuwen

Plexus hypogastr. inf.

Sacrale parasymp. outflow





By Paul Gobée, dept. Anatomy & Embryology, LUMC license CC BY NC SA

Bronnen: Gray's Anatomy 41st ed., Moore K et al, Clin. Oriented Anatomy, 8th ed.

"Servier - Drawing Vertebral column anterior view - no labels" by Servier Medical Art, license: CC BY

"Branches of the abdominal aorta - English labels" by Open Learning Initiative, license: CC BY-NC-SA

