

Autonome Zenuwstelsel Sympathische & parasympathische routes

Paul Gobée, dept. Anatomy & Embryology,
LUMC

license CC BY NC SA

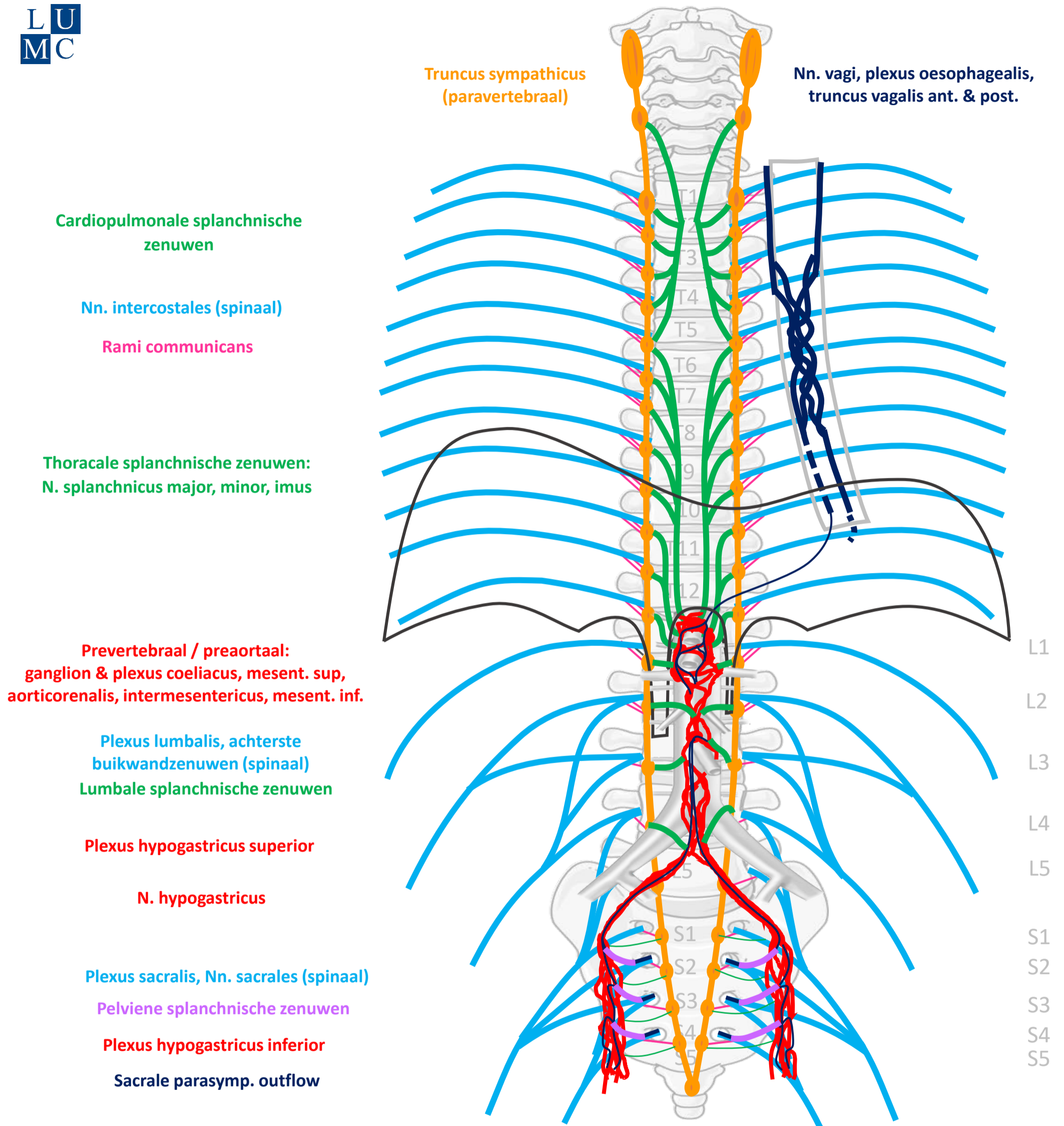


v4, Maart 2024

Vooraf...

- Deze presentatie bouwt voort op het schema uit presentatie 'Autonome Zenuwstelsel Schematisch opgebouwd'.
- Het is aan te raden deze eerst te bestuderen.

Schema Autonome Zenuwstelsel



SYMP

CZS

PARASYMP

Rami communicans
Splanchnische zenuwen

Spinale zenuwen

Paravertebraal (truncus sympathicus)

Pelviene splanchnische zenuwen

Prevertebraal / preaortaal

N. vagus

ORGAAN

Download dit schema



v. 3, March 2024

By Paul Gobée, dept. Anatomy & Embryology, LUMC license CC BY NC SA

Bronnen: Gray's Anatomy 41st ed., Moore K et al, Clin. Oriented Anatomy, 8th ed.

"Servier - Drawing Vertebral column anterior view - no labels" by Servier Medical Art, license: CC BY

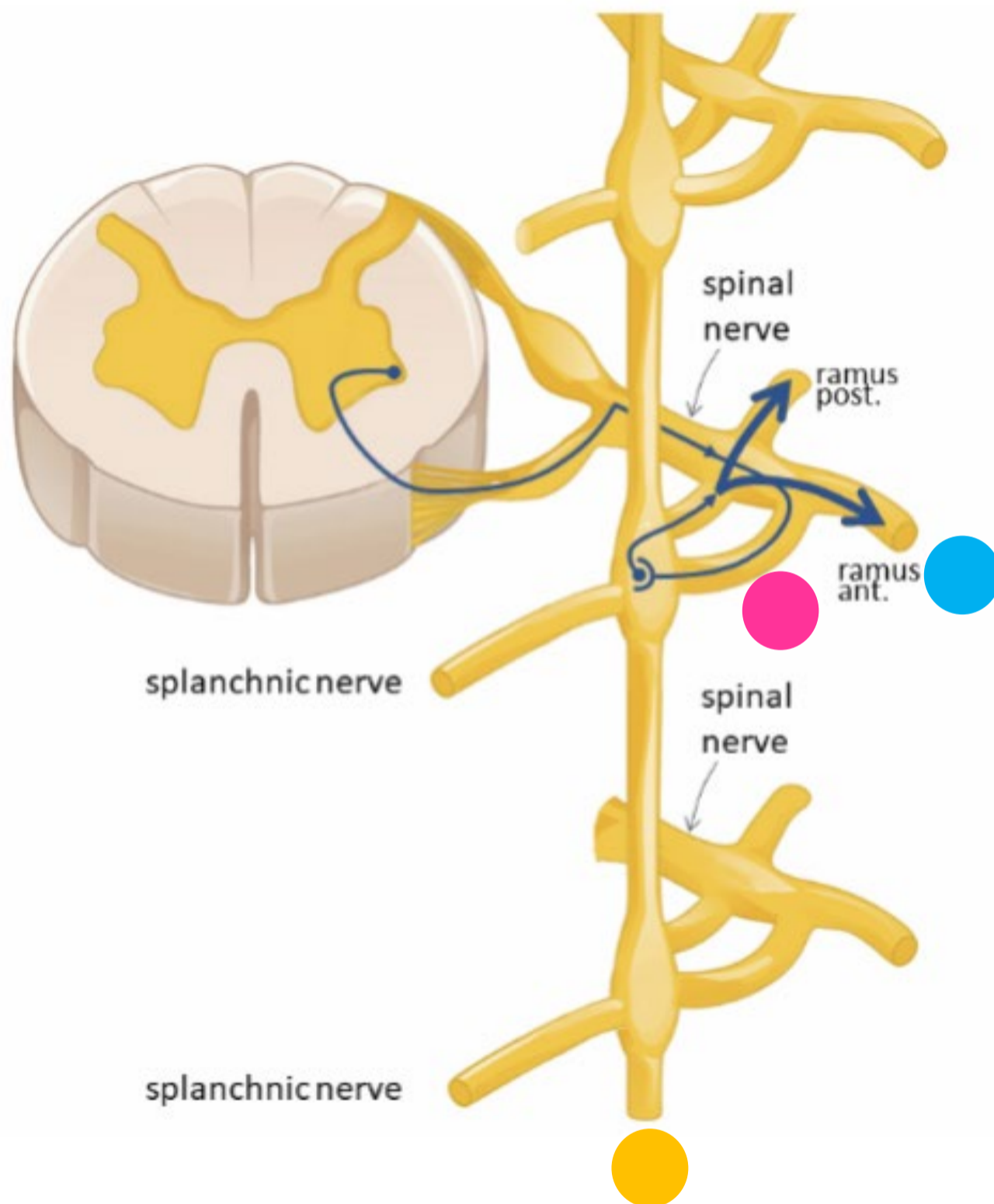
"Branches of the abdominal aorta - English labels" by Open Learning Initiative, license: CC BY-NC-SA



Sympathisch naar rompwand

- Zweten
- Kippevel
- Perifere vaatvernauwing

Sympathisch naar rompwand



Spinale zenuw

Ramus communicans albus

Paravertebraal (truncus sympathicus) *SYNAPS*

Ramus communicans griseus

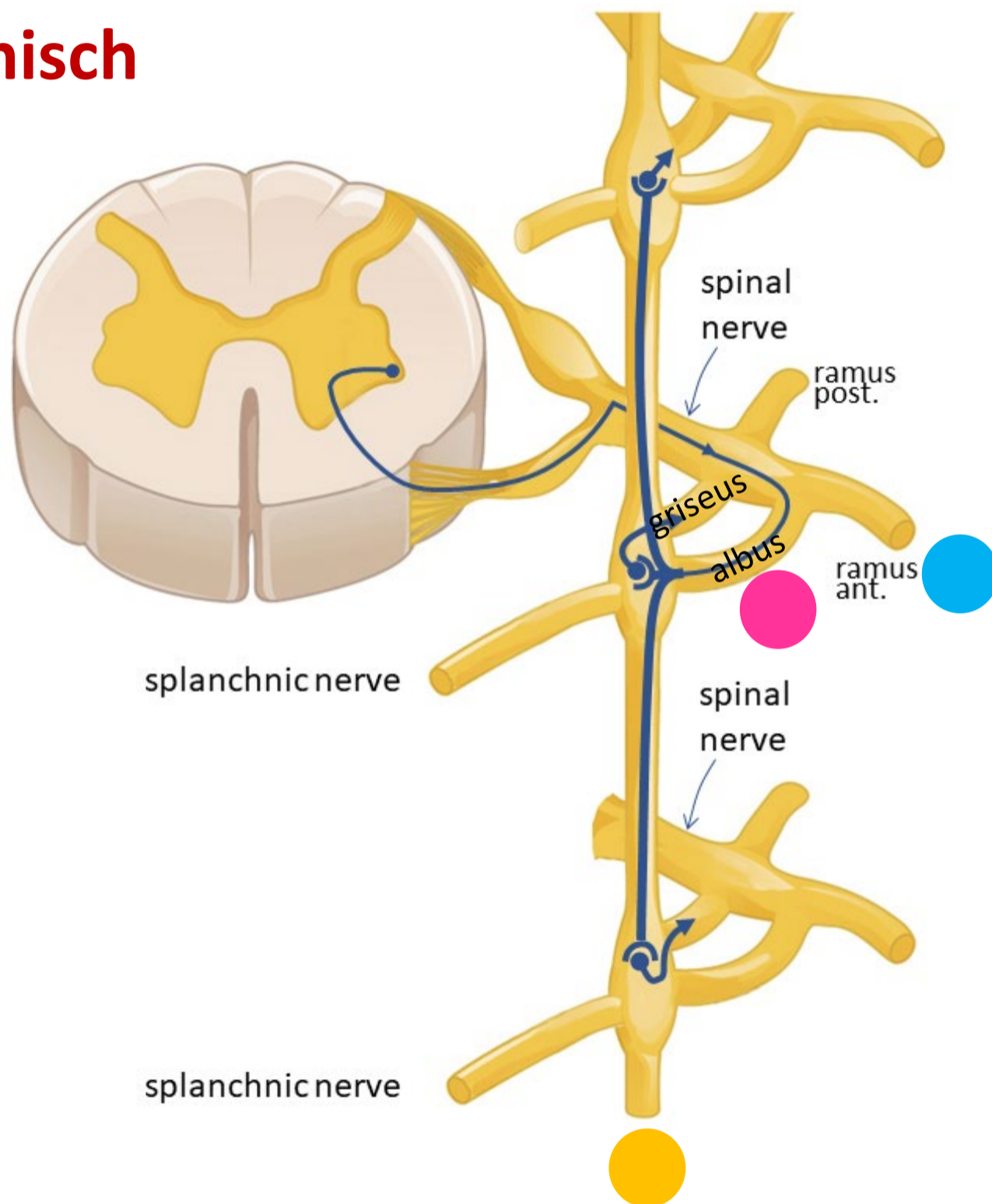
Spinale zenuw

Rompwand – zweetklieren, haarfollikels, bloedvaten



Sympathisch naar rompwand

Sympathisch



Spinale zenuw

Ramus communicans albus

Paravertebraal (truncus sympathicus) *SYNAPS*

OMHOOG / ZELFDE NIVEAU / OMLAAG

Ramus communicans griseus

Spinale zenuw

Rompwand – zweetklieren, haarfollikels, bloedvaten





Sympathisch

OP ALLE NIVEAUS

Nn. intercostales
(spinaal)

Rami communicans

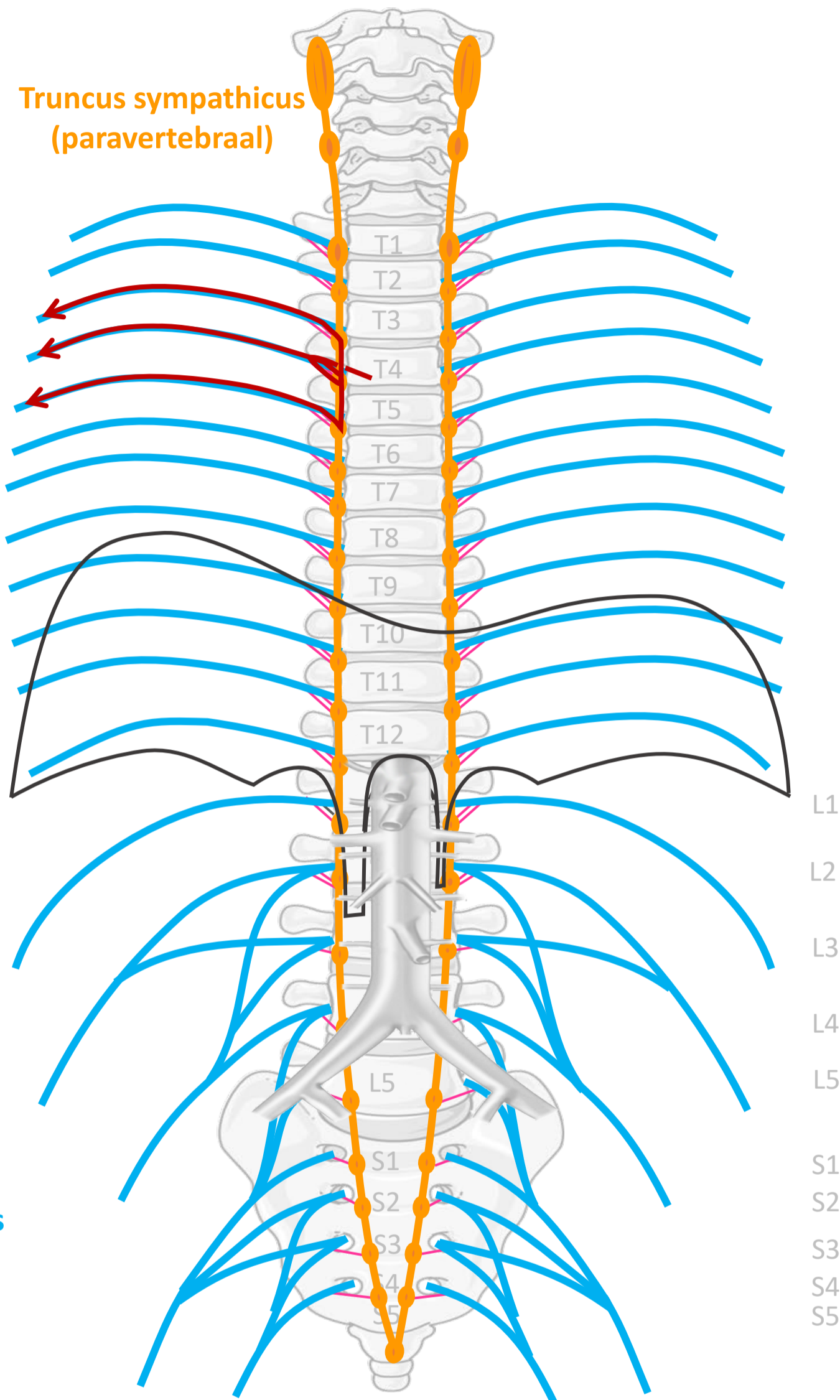
Plexus lumbalis, achterste
buikwandzenuwen
(spinaal)

Rami communicans

Plexus sacralis, Nn. sacrales
(spinaal)

Rami communicans

Truncus sympathicus
(paravertebraal)



SYMP

CZS

PARASYMP

Rami communicans
albus

Rami communicans
griseus



Spinale zenuwen

Paravertebraal (truncus sympathicus)

Spinale zenuwen

ORGAAN

Download dit schema



v. 3, March 2024

By Paul Gobée, dept. Anatomy & Embryology, LUMC license CC BY NC SA

Bronnen: Gray's Anatomy 41st ed., Moore K et al, Clin. Oriented Anatomy, 8th ed.

"Servier - Drawing Vertebral column anterior view - no labels" by Servier Medical Art, license: CC BY

"Branches of the abdominal aorta - English labels" by Open Learning Initiative, license: CC BY-NC-SA

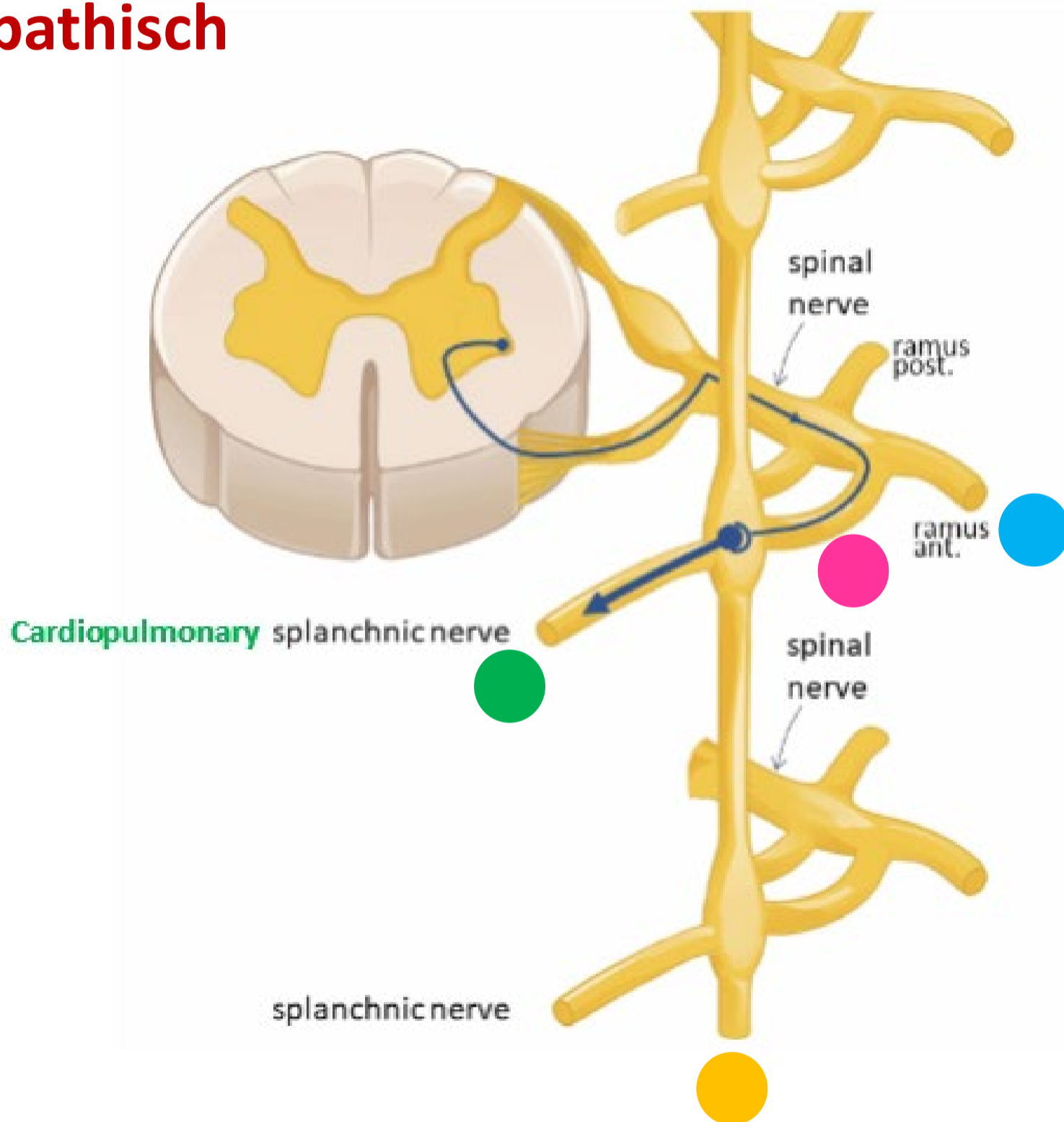


Sympathisch naar hart, long, oesophagus

- Snellere, krachtigere hartslag
- Verwijding luchtwegen

Sympathisch naar hart, long, oesophagus

Sympathisch



Spinale zenuw

Ramus communicans albus

Paravertebraal (truncus sympathicus) *SYNAPS*

OMHOOG / ZELFDE NIVEAU / OMLAAG

Cardiopulmonale splanchnische zenuwen

Hart, longen, oesophagus

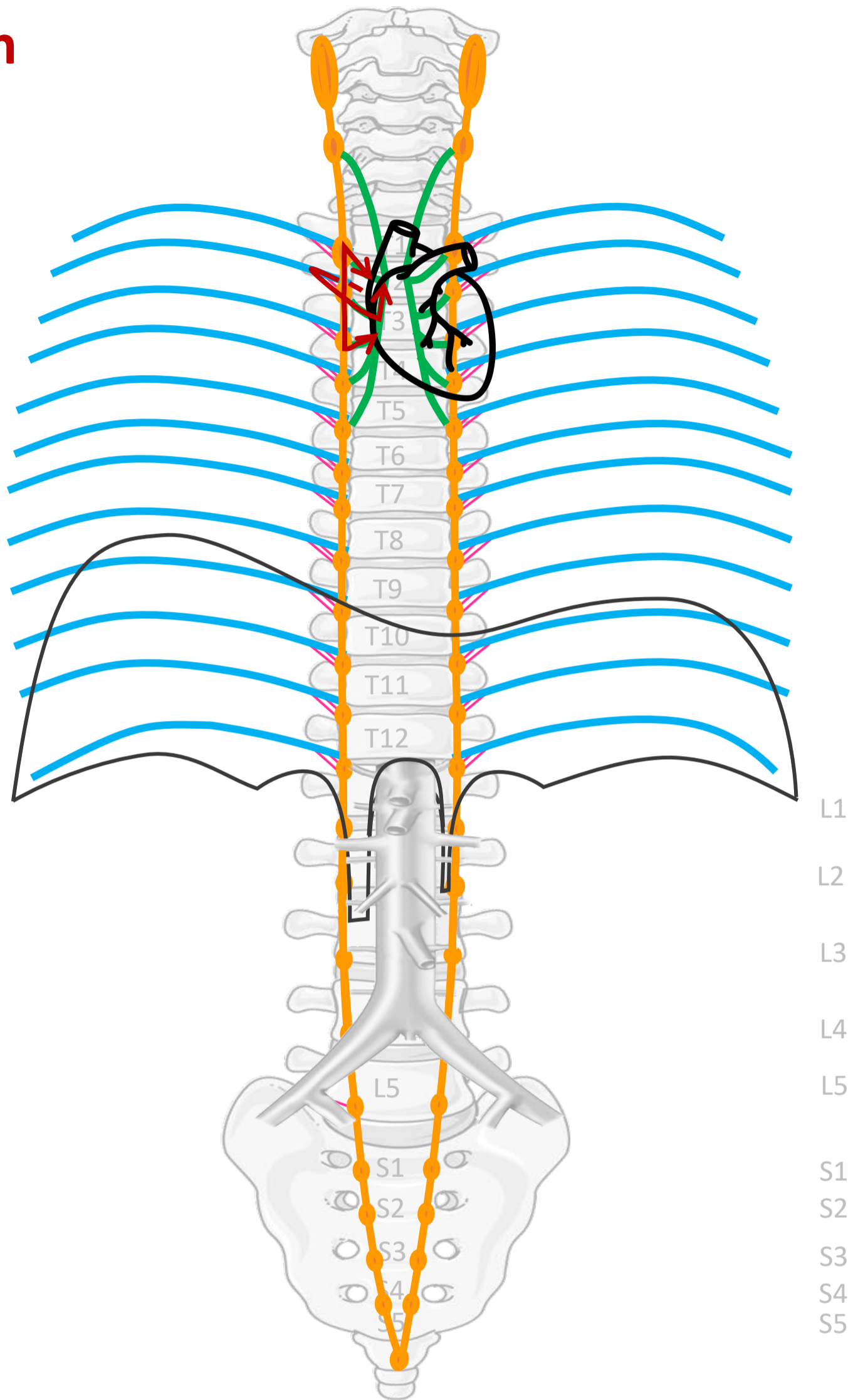
Sympathisch

Nn. intercostales (spinaal)

Rami communicans

Truncus sympathicus
(paravertebraal)

Cardiopulmonale
splanchnische zenuwen



Verbindingen
(SYMP)

Rami
communicans

Cardiopulmonale
Splanchnische
zenuwen

CZS

Spinale zenuwen

Paravertebraal (truncus sympathicus)

ORGAAN

By Paul Gobée, dept. Anatomy & Embryology, LUMC license CC BY NC SA

Sources: Gray's Anatomy 41st ed., Moore K et al, Clin. Oriented Anatomy, 8th ed.

"Servier - Drawing Vertebral column anterior view - no labels" by Servier Medical Art, license: CC BY

"Branches of the abdominal aorta - English labels" by Open Learning Initiative, license: CC BY-NC-SA

Heart icon by Nick Bluth at <https://thenounproject.com/icon/heart-659096/> license CC BY

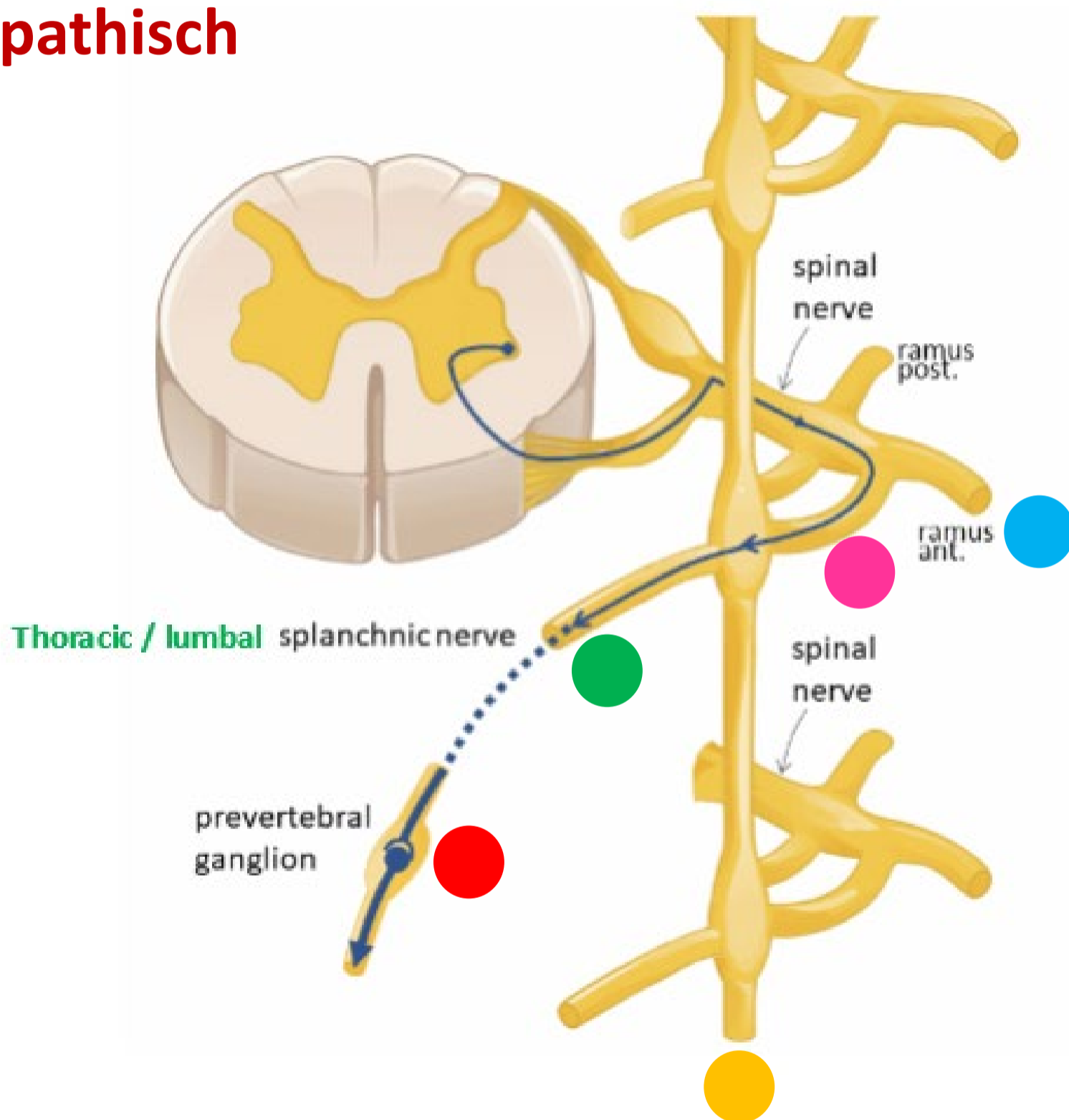


Sympathisch naar buik- en bekkenorganen

- Remming peristaltiek
- Vasoconstrictie in tractus digestivus
- Omzetting glycogeen naar glucose
- Continentie - constrictie blaas- en anale- interne sphincters

Sympathisch naar buik- en bekkenorganen

Sympathisch



Spinale zenuw

Ramus communicans albus

Paravertebraal (truncus sympathicus) *GÉÉN SYNAPS*

Thoracale /lumbale splanchnische zenuwen

Prevertebraal / preaortaal ganglion/ plexus *SYNAPS*

Met bloedvaten mee naar organen





Sympathisch

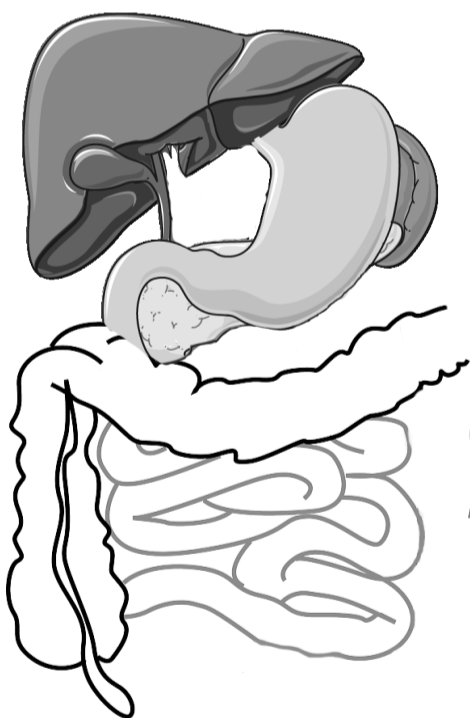
**Nn. intercostales
(spinaal)**

Rami communicans

Truncus sympathicus
(paravertebraal)

**Thoracale
splanchnische
zenuwen:**
N. splanchnicus major, minor,
imus

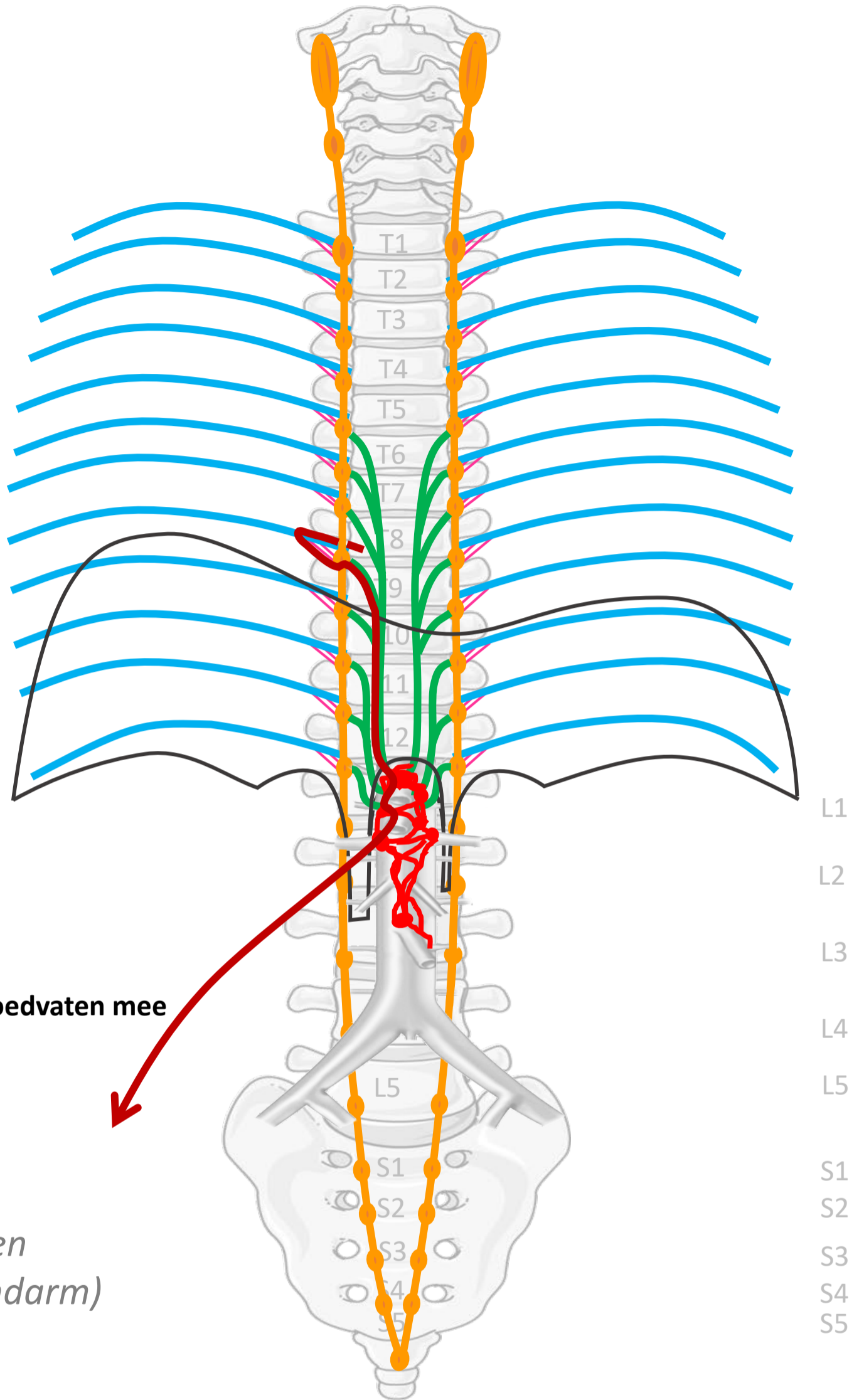
**Prevertebrale / preaortale
ganglia & plexi:**
ganglia & plexus coeliacus,
ganglion & plexus mesent. sup,
ganglia aorticorenalia,
plexus intermesentericus,
plexus mesent. inf.



(voor- en
middendarm)

Verbindingen
(SYMP)

Rami communicans
Thoracale
splanchnische zenuwen
Met bloedvaten mee



Met bloedvaten mee

CZS
↓
Spinale zenuwen

Paravertebraal (truncus sympathicus)

Prevertebraal / preaortaal

↓
ORGAAN

By Paul Gobée, dept. Anatomy & Embryology, LUMC license CC BY NC SA

Sources: Gray's Anatomy 41st ed., Moore K et al, Clin. Oriented Anatomy, 8th ed.

"Servier - Drawing Vertebral column anterior view - no labels" by Servier Medical Art, license: CC BY

"Branches of the abdominal aorta - English labels" by Open Learning Initiative, license: CC BY-NC-SA

Clker-Free-Vector-Images <https://pixabay.com/vectors/intestines-bowel-guts-intestinal-293929/> License: Pixabay

"Servier - Drawing Overview digestive tract - no labels" by Servier Medical Art, license: CC BY



Sympathisch

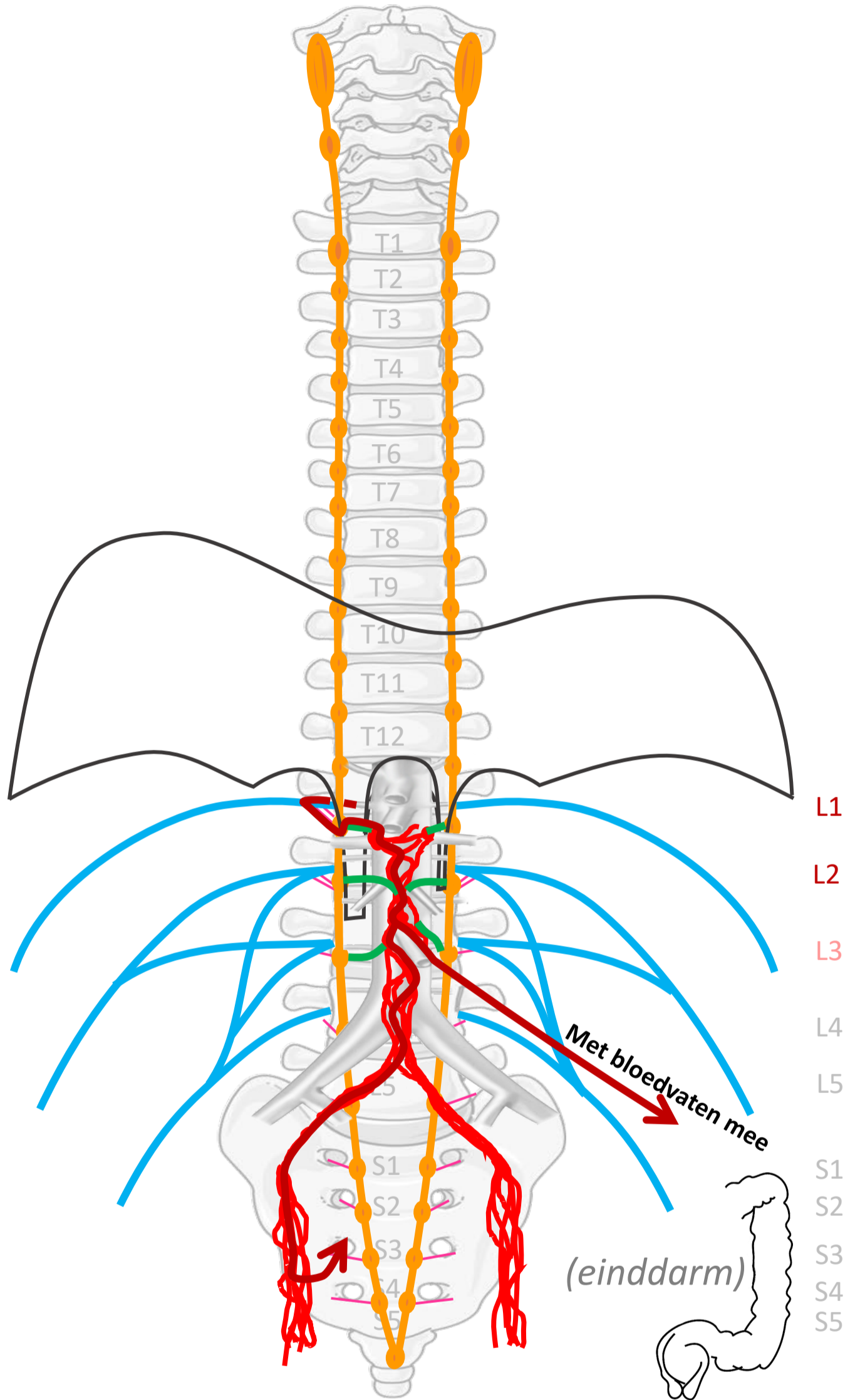
**Plexus lumbalis,
achterste
buikwandzenuwen
(spinaal)**

Rami communicans

Truncus sympathicus (paravertebraal)

**Lumbale splanchnische
zenuwen**

**Prevertebrale / preaortale
ganglia & plexi:**
plexus intermesentericus,
ganglia & plexus mesent. inf.,
plexus hypogastricus sup.,
n. hypogastricus,
plexus hypogastricus inf.



**Verbindingen
(SYMP)**

Rami communicans

Lumbale
splanchnische zenuwen

Met bloedvaten mee of
via plexus hypogastr. inf.

CZS

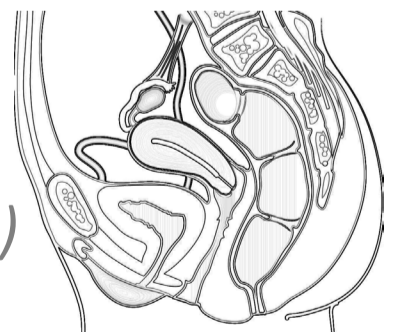
Spinale zenuwen

Paravertebraal (truncus sympathicus)

Prevertebraal / preaortaal

ORGAAN

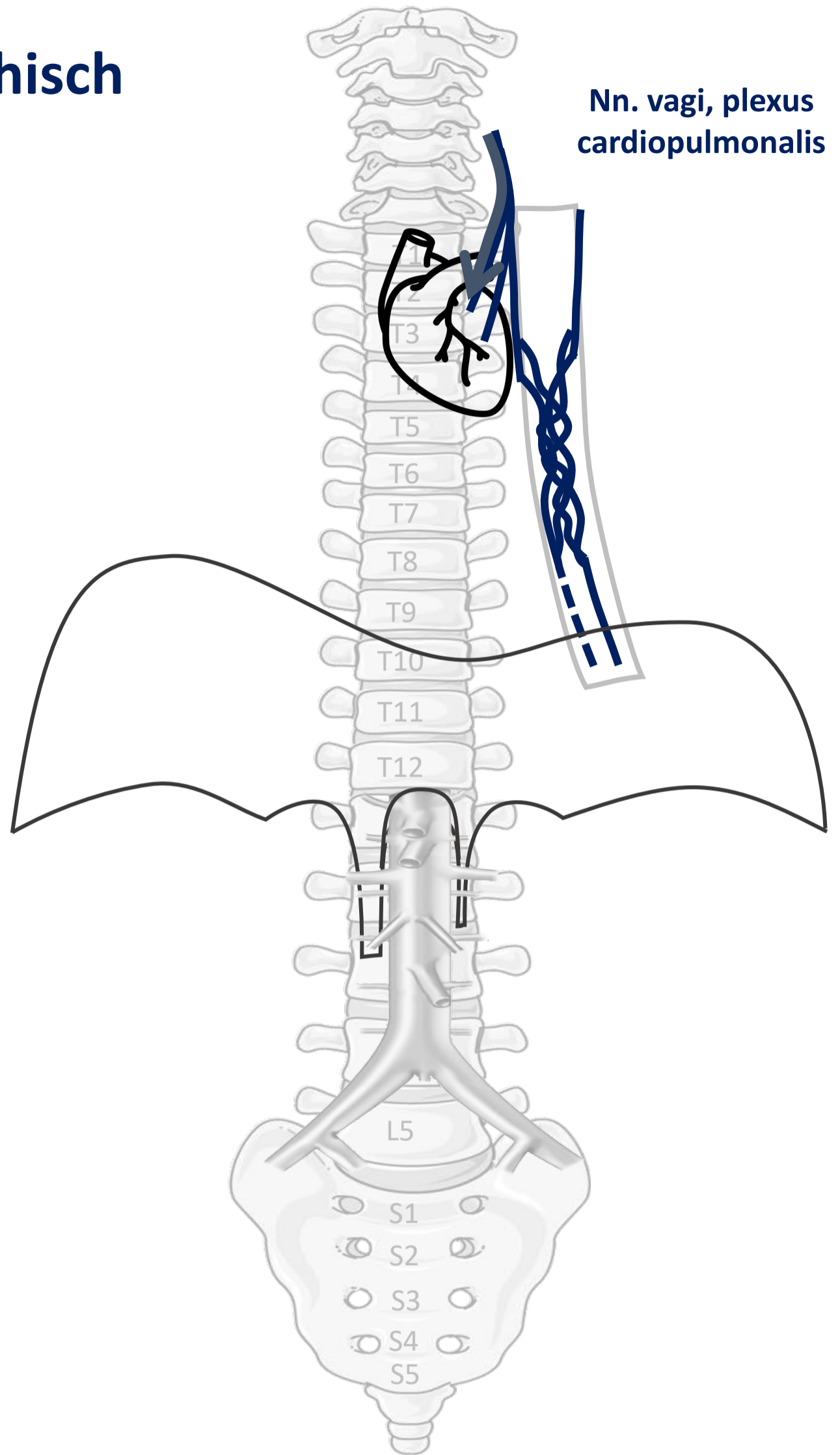
(bekken
organen)



Parasympathisch naar hart, long, oesophagus

- Vertraging, minder krachtige hartslag
- Vernauwing luchtwegen
- Toename bronchus-secretie

Parasympathisch



CZS



ORGAAN

PARASYMP

N. vagus



By Paul Gobée, dept. Anatomy & Embryology, LUMC license CC BY NC SA

Sources: Gray's Anatomy 41st ed., Moore K et al, Clin. Oriented Anatomy, 8th ed.

"Servier - Drawing Vertebral column anterior view - no labels" by Servier Medical Art, license: CC BY

"Branches of the abdominal aorta - English labels" by Open Learning Initiative, license: CC BY-NC-SA

Heart icon by Nick Bluth at <https://thenounproject.com/icon/heart-659096/> license CC BY

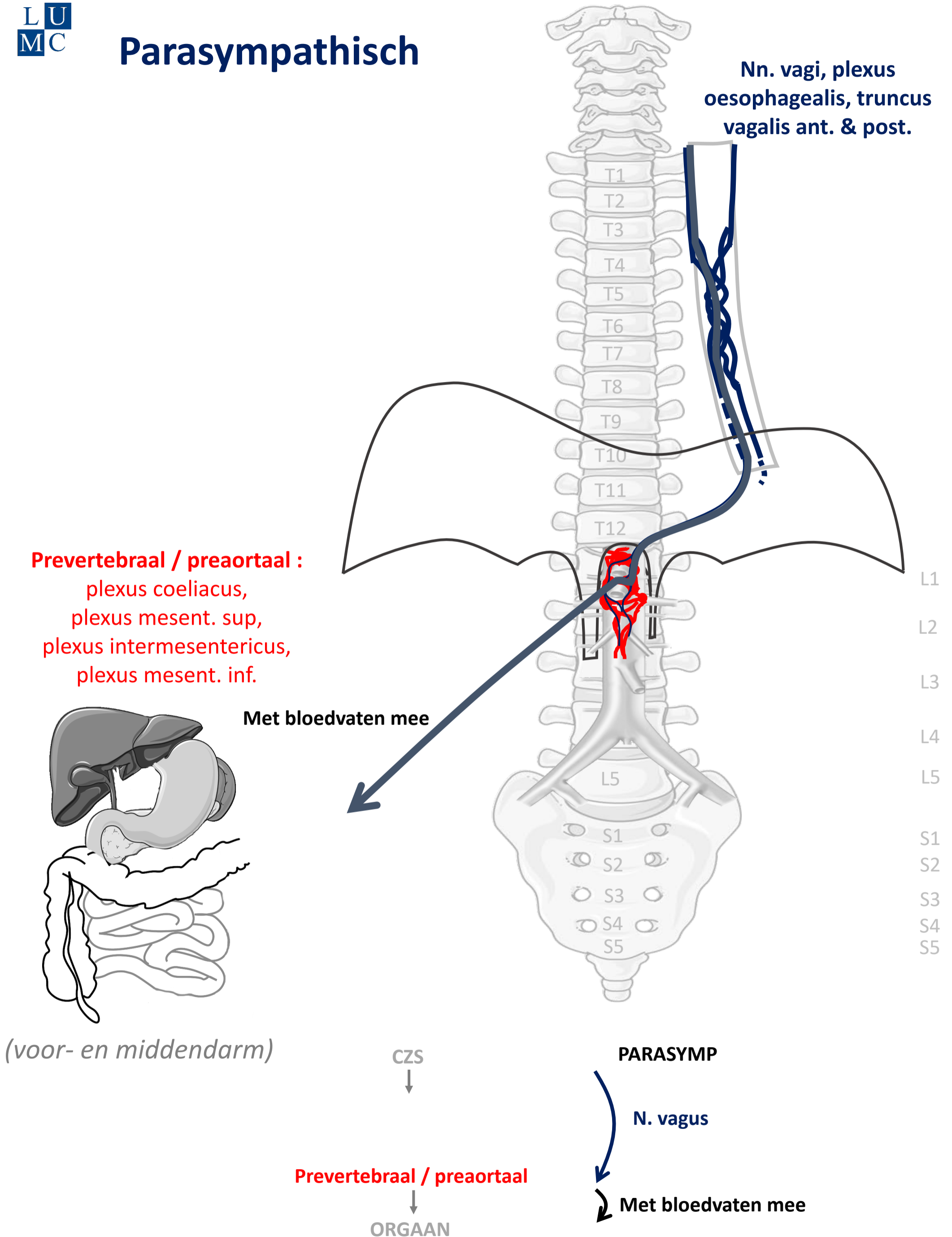


Parasympathisch naar buikorganen

(t/m middendarm – colon transversum)

- Stimulering peristaltiek
- Stimulering secretie spijsverteringssappen
- Omzetting glucose naar glycogeen

Parasympathisch



By Paul Gobée, dept. Anatomy & Embryology, LUMC license CC BY NC SA

Sources: Gray's Anatomy 41st ed., Moore K et al, Clin. Oriented Anatomy, 8th ed.

"Servier - Drawing Vertebral column anterior view - no labels" by Servier Medical Art, license: CC BY

"Branches of the abdominal aorta - English labels" by Open Learning Initiative, license: CC BY-NC-SA

Clker-Free-Vector-Images <https://pixabay.com/vectors/intestines-bowel-guts-intestinal-293929/> License: Pixabay

"Servier - Drawing Overview digestive tract - no labels" by Servier Medical Art, license: CC BY

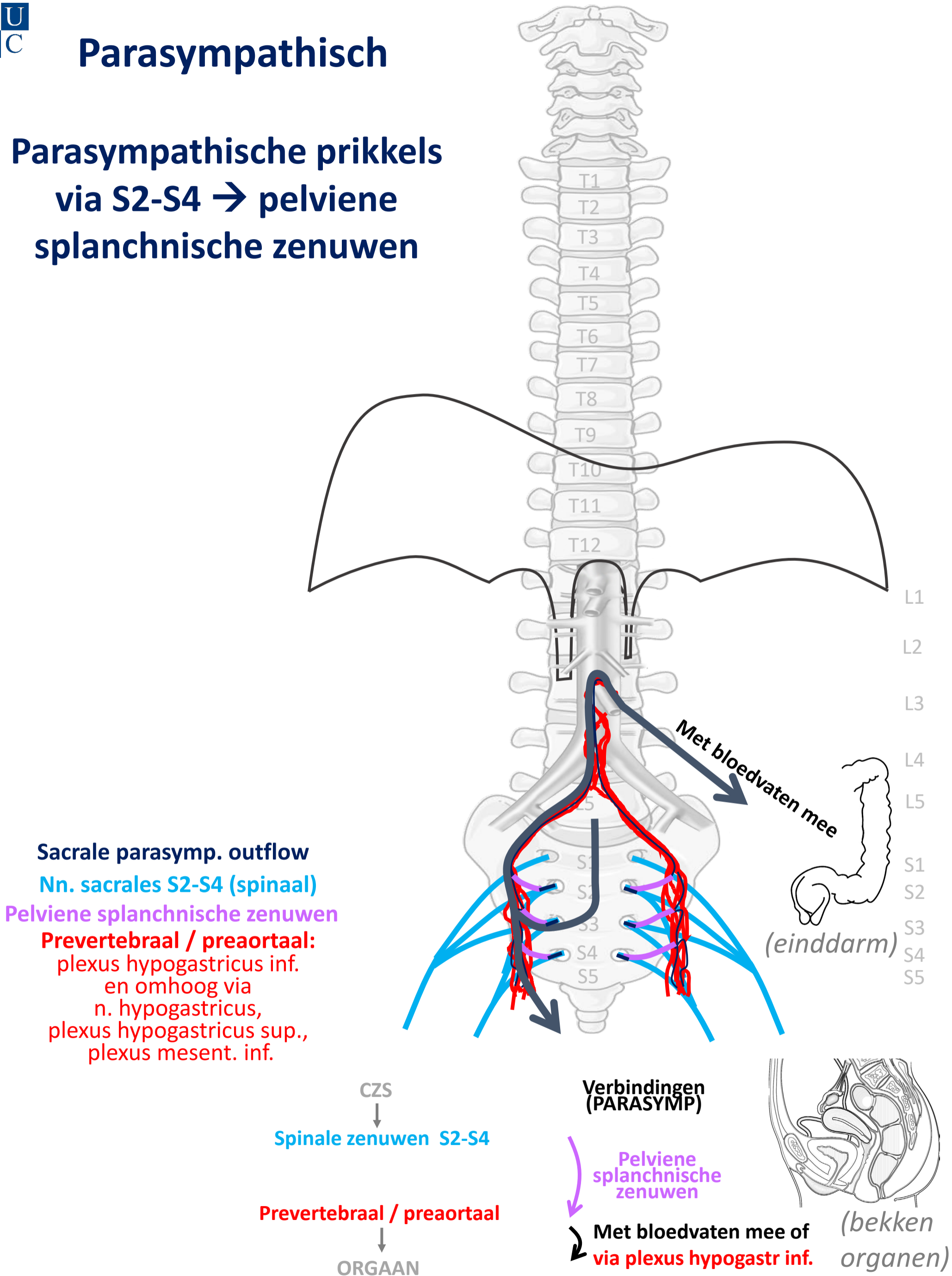


Parasympathisch naar einddarm (colon desc/sigmoid/rectum) en bekkenorganen

- Stimulering peristaltiek
- Defaecatie, mictie
- Erectie genitalia

Parasympathisch

Parasympathische prikkels
via S2-S4 → pelviene
splanchnische zenuwen



By Paul Gobée, dept. Anatomy & Embryology, LUMC license CC BY NC SA

Sources: Gray's Anatomy 41st ed., Moore K et al, Clin. Oriented Anatomy, 8th ed.

"Servier - Drawing Vertebral column anterior view - no labels" by Servier Medical Art, license: CC BY

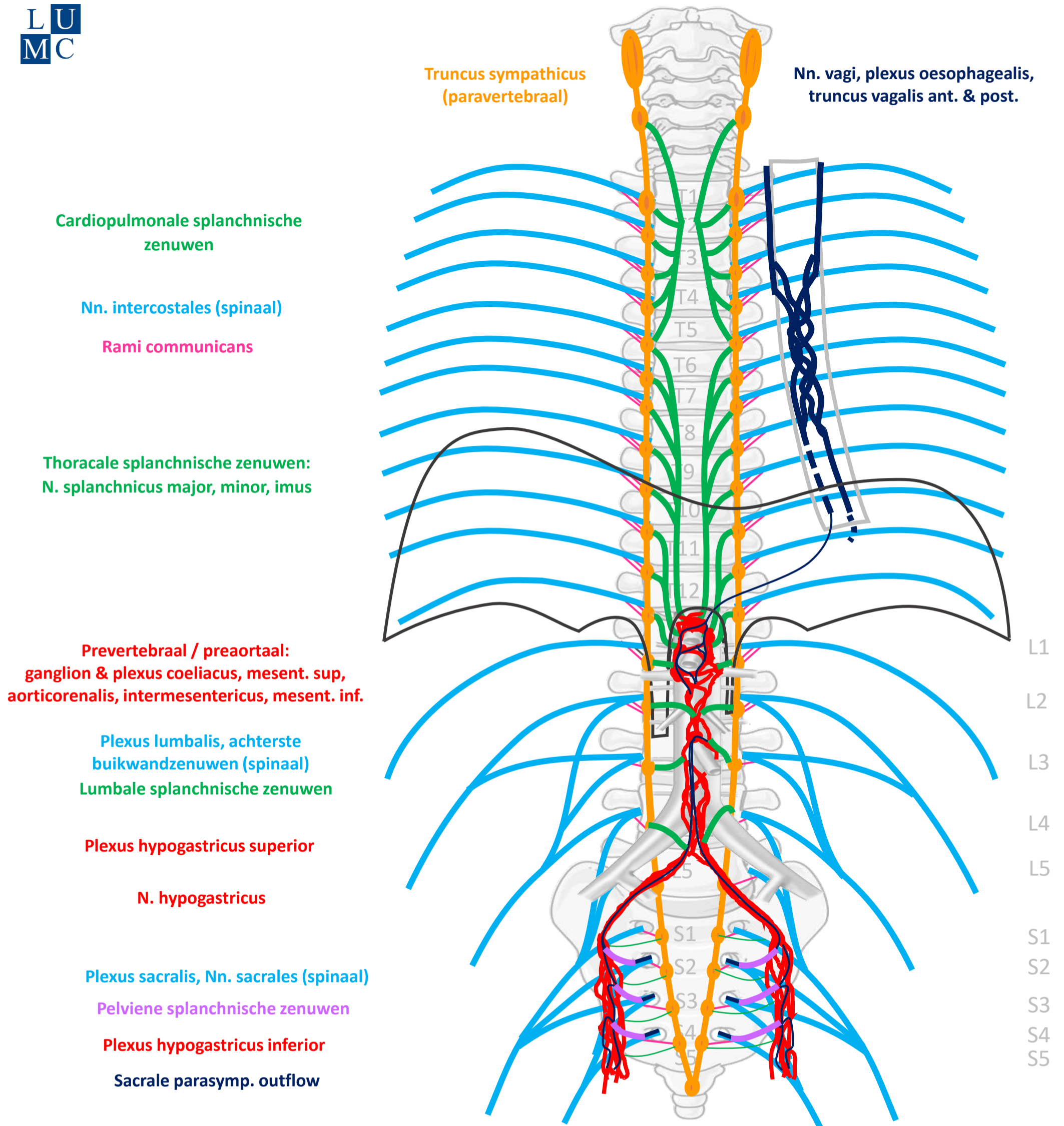
"Branches of the abdominal aorta - English labels" by Open Learning Initiative, license: CC BY-NC-SA

Clker-Free-Vector-Images <https://pixabay.com/vectors/intestines-bowel-guts-intestinal-293929/> License: Pixabay

"Slagter - Drawing Female pelvis in sagittal section - no labels" by Ron Slagter, license: CC BY-NC-SA



Schema Autonome Zenuwstelsel



SYMP

CZS

PARASYMP

Rami communicans
Splanchnische zenuwen

Spinale zenuwen

Paravertebraal (truncus sympathicus)

Pelviene splanchnische zenuwen

Prevertebraal / preaortaal

N. vagus

ORGAAN

Download dit schema



v. 3, March 2024

By Paul Gobée, dept. Anatomy & Embryology, LUMC license CC BY NC SA

Bronnen: Gray's Anatomy 41st ed., Moore K et al, Clin. Oriented Anatomy, 8th ed.

"Servier - Drawing Vertebral column anterior view - no labels" by Servier Medical Art, license: CC BY

"Branches of the abdominal aorta - English labels" by Open Learning Initiative, license: CC BY-NC-SA

