

Schema Autonome zenuwstelsel



Truncus sympathicus (paravertebraal)

Nn. vagi, plexus oesophagealis, truncus vagalis ant. & post.

Cardiopulmonale splanchnische zenuwen

Nn. intercostales (spinaal)

Rami communicans

Thoracale splanchnische zenuwen: N. splanchnicus major, minor, imus

Prevertebraal / preaortaal: ganglion & plexus coeliacus, mesent. sup, aorticorenalis, intermesentericus, mesent. inf.

Plexus lumbalis, achterste buikwandzenuwen (spinaal)
Lumbale splanchnische zenuwen

Plexus hypogastricus superior

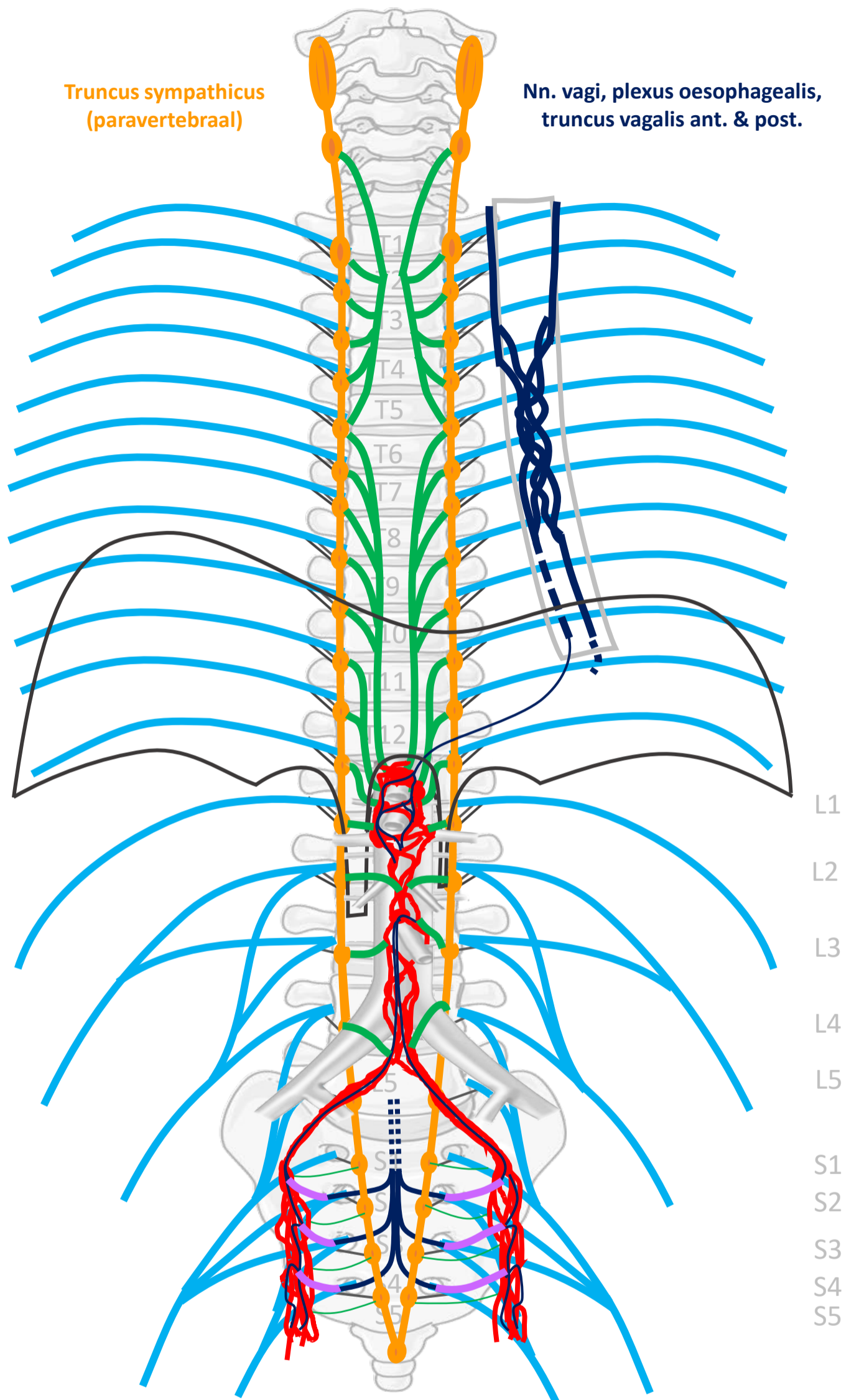
N. hypogastricus

Plexus sacralis, Nn. sacrales (spinaal)

Pelviene splanchnische zenuwen

Plexus hypogastricus inferior

Sacrale parasymp. outflow



SYMP

CZS

PARASYMP

Rami communicans
Splanchnische zenuwen

Spinale zenuwen

Paravertebraal (truncus sympathicus)

Pelviene splanchnische zenuwen

Prevertebraal / preaortaal

N. vagus

ORGAAN

Download dit schema



v. 2, oct 2022

By Paul Gobée, dept. Anatomy & Embryology, LUMC license CC BY NC SA

Bronnen: Gray's Anatomy 41st ed., Moore K et al, Clin. Oriented Anatomy, 8th ed.

"Servier - Drawing Vertebral column anterior view - no labels" by Servier Medical Art, license: CC BY

"Branches of the abdominal aorta - English labels" by Open Learning Initiative, license: CC BY-NC-SA

