



Leids Universitair
Medisch Centrum

Pelvis - pelvic floor

O. Paul Gobée, M.D.

Dept. Anatomy & Embryology

LEIDEN UNIVERSITY MEDICAL CENTER



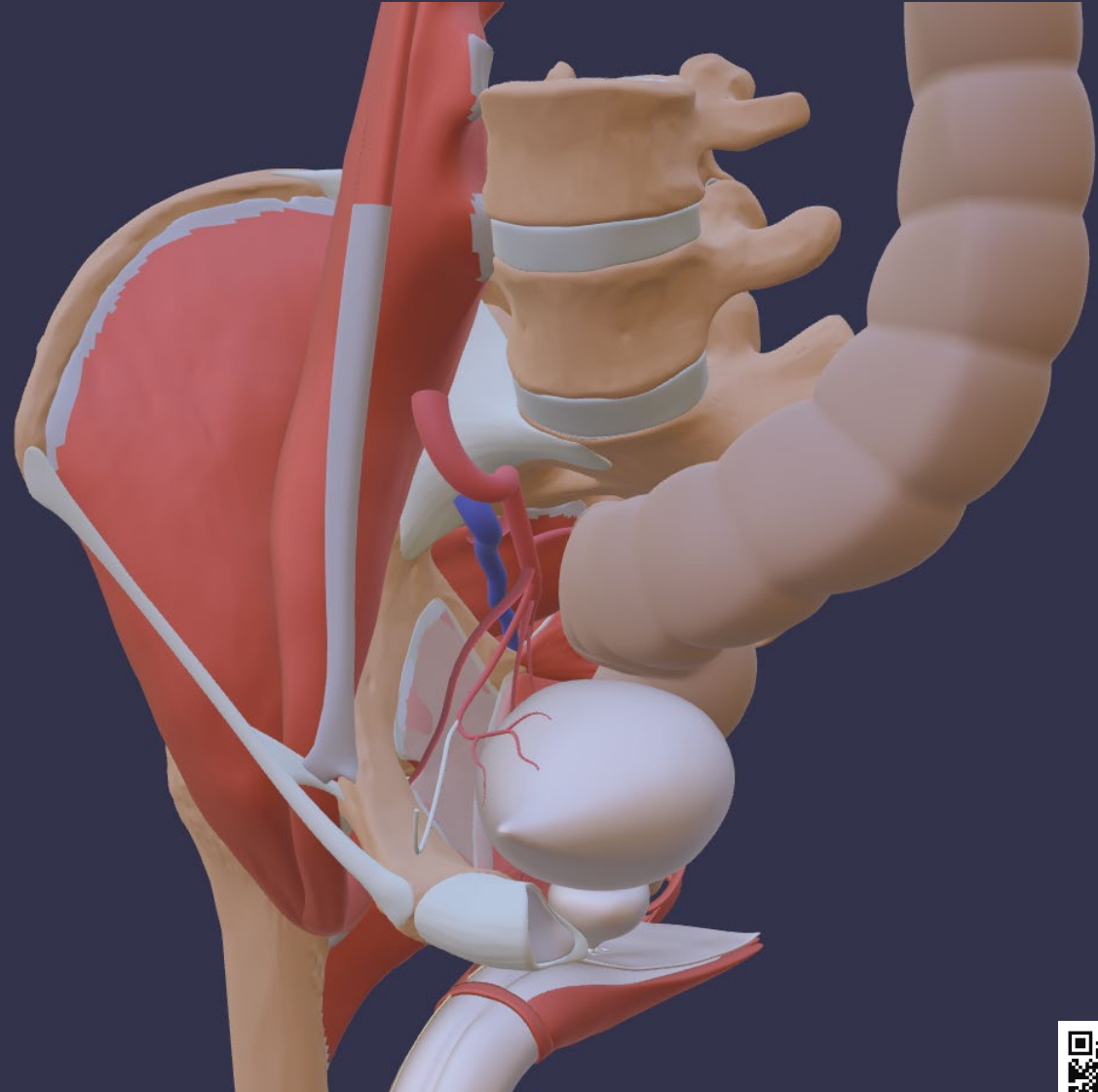
Open anatomical 3D model

Images in this presentation are retrieved from the *Sub model 'Pelvic floor and perineum' (untextured)* by Marco C. DeRuiter, Eungyeol Lee, Daniël Jansma and Paul Gobée (all at LUMC). It is licensed under Creative Commons Attribution ShareAlike (CC BY SA).

<https://anatomytool.org/content/open3danatomy-3d-model-pelvic-floor-and-perineum-english-labels>



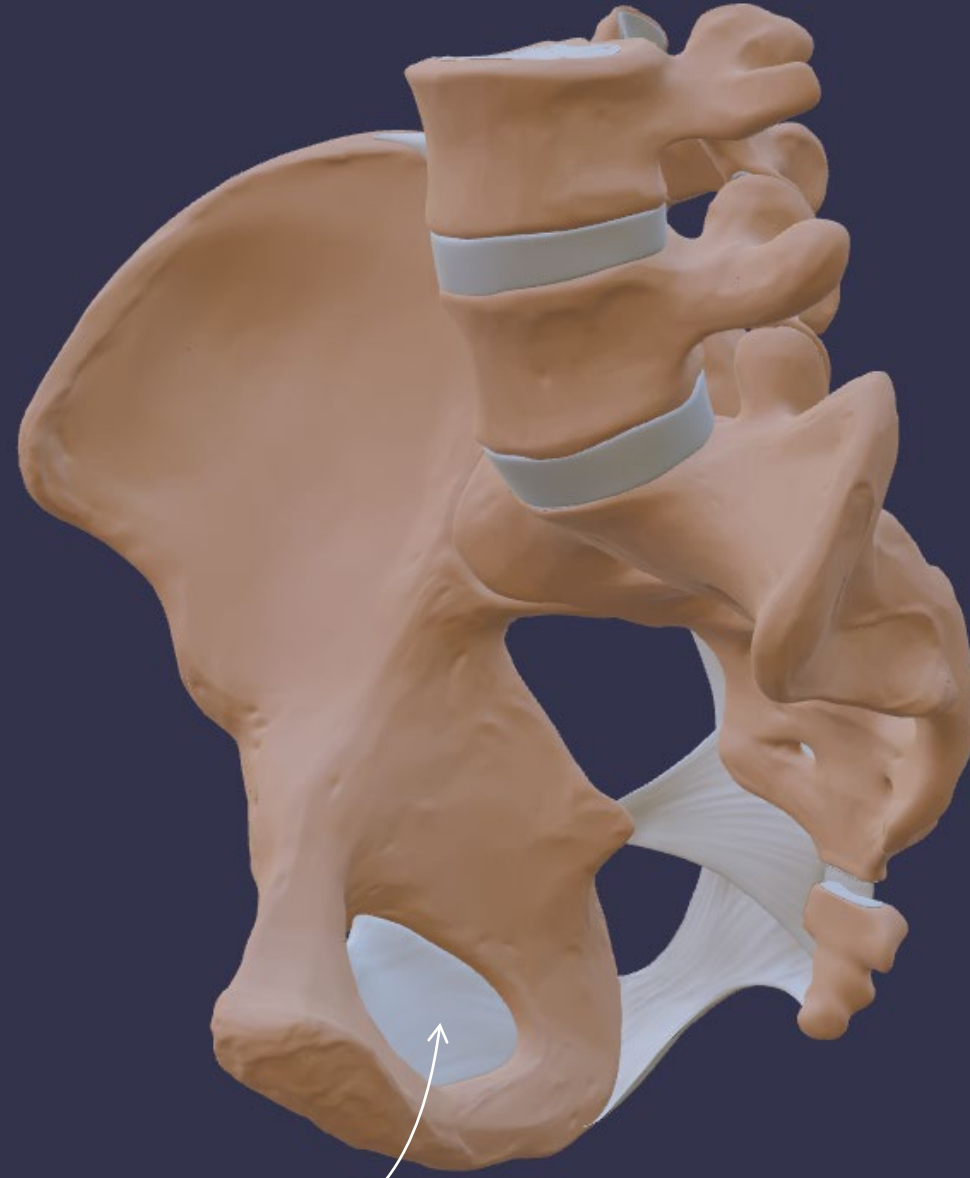This is a sub model of the ***Open Anatomical 3D model***, which was developed by LUMC, UMCU, UM and KU Leuven, with an initial grant of the Dutch Ministry of Education, Culture & Science. It was based on predecessor models BodyParts and Z-Anatomy, which are licensed under Creative Commons Attribution ShareAlike (CC BY SA).



Muscles, Pelvic Floor

Muscles

(medial view)

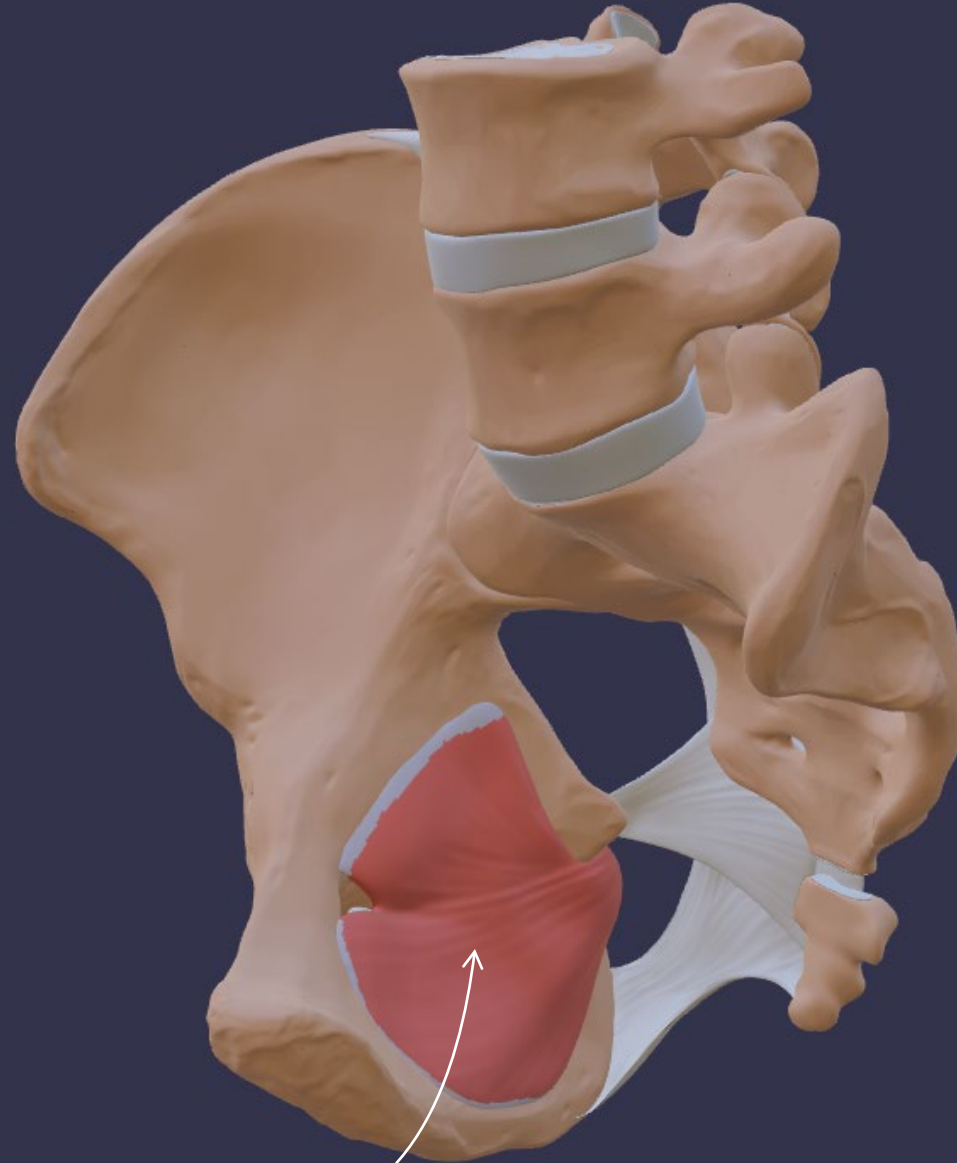


Obturator membrane
Membrana obturatorium



Muscles

(medial view)

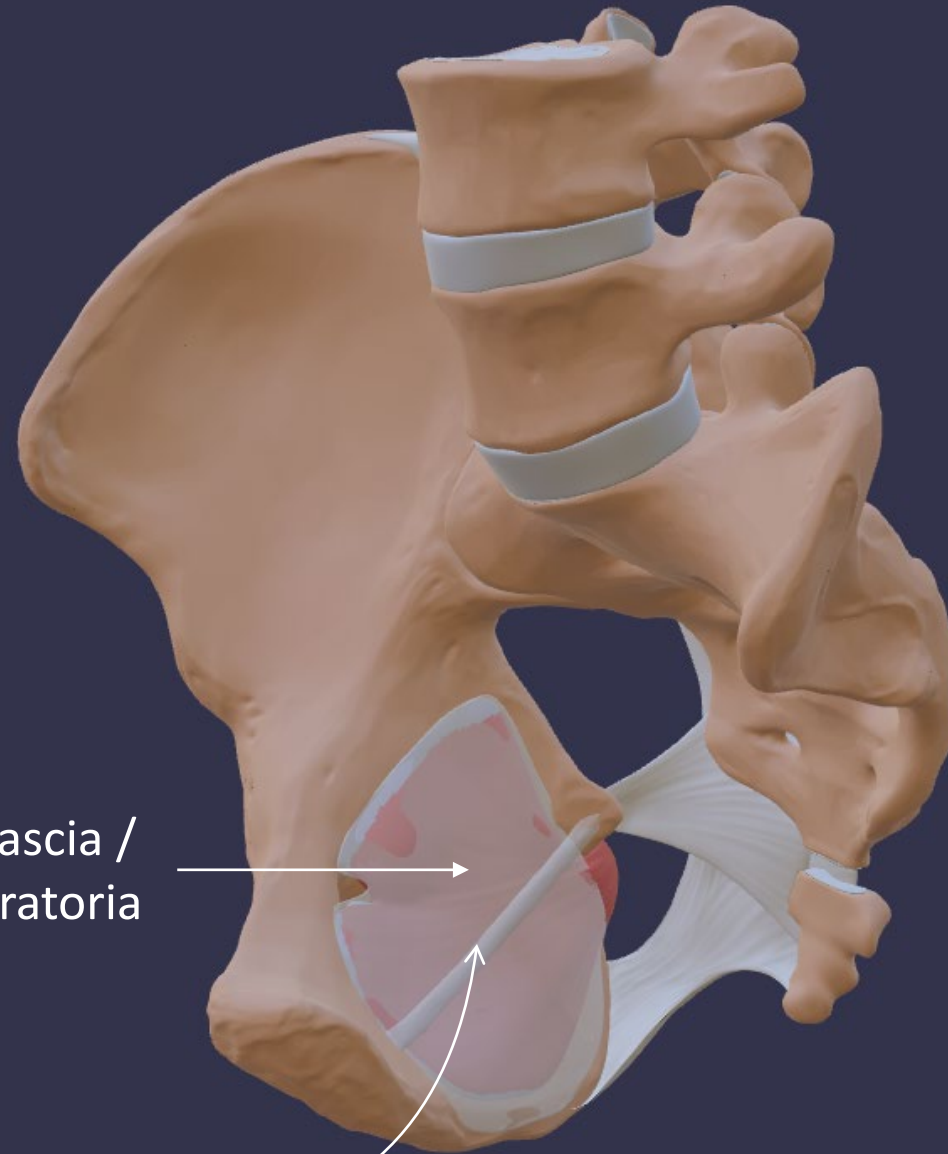


Obturator internus /
M. obturatorius internus



Muscles

(medial view)



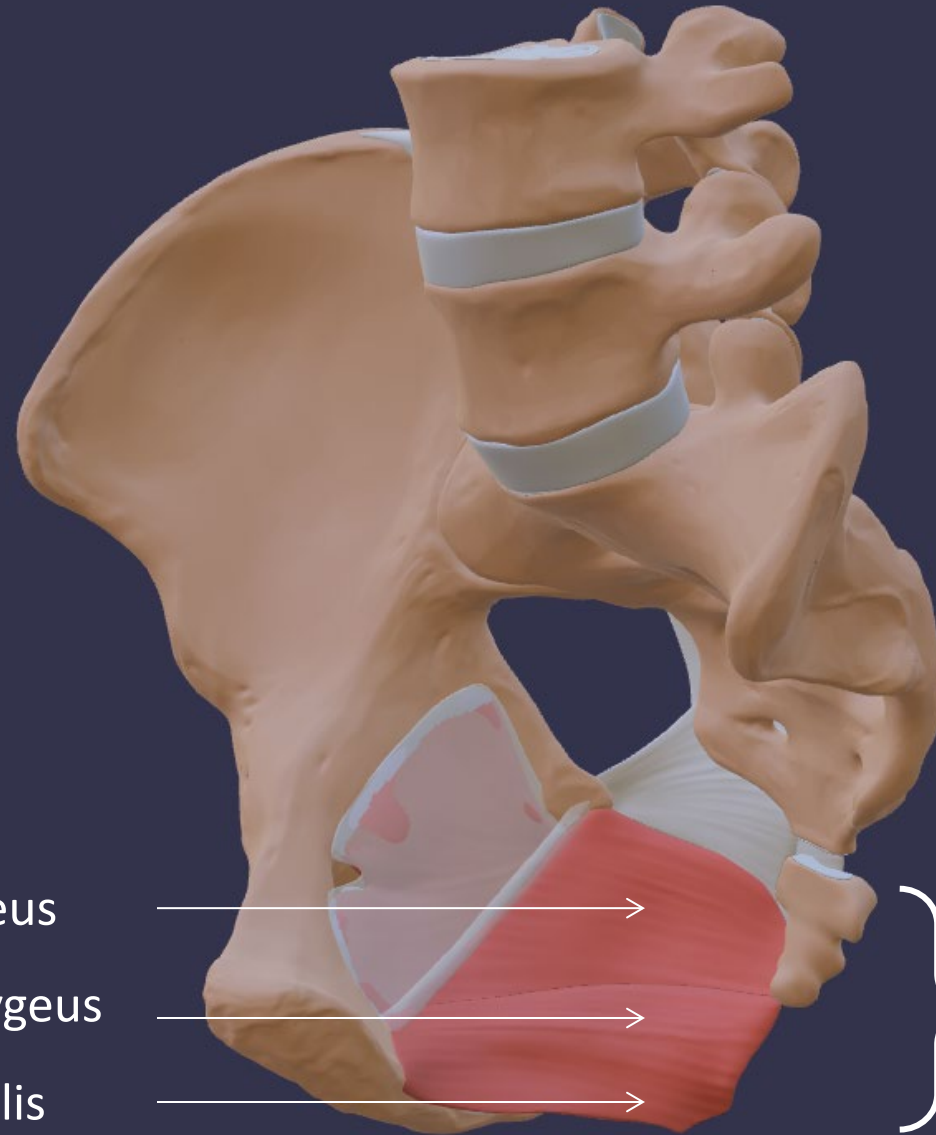
Obturator fascia /
Fascia obturatoria

Tendinous arch /
Arcus tendineus



Muscles

(medial view)



Iliococcygeus / m. iliococcygeus

Pubococcygeus / m. pubococcygeus

Puborectalis / m. puborectalis

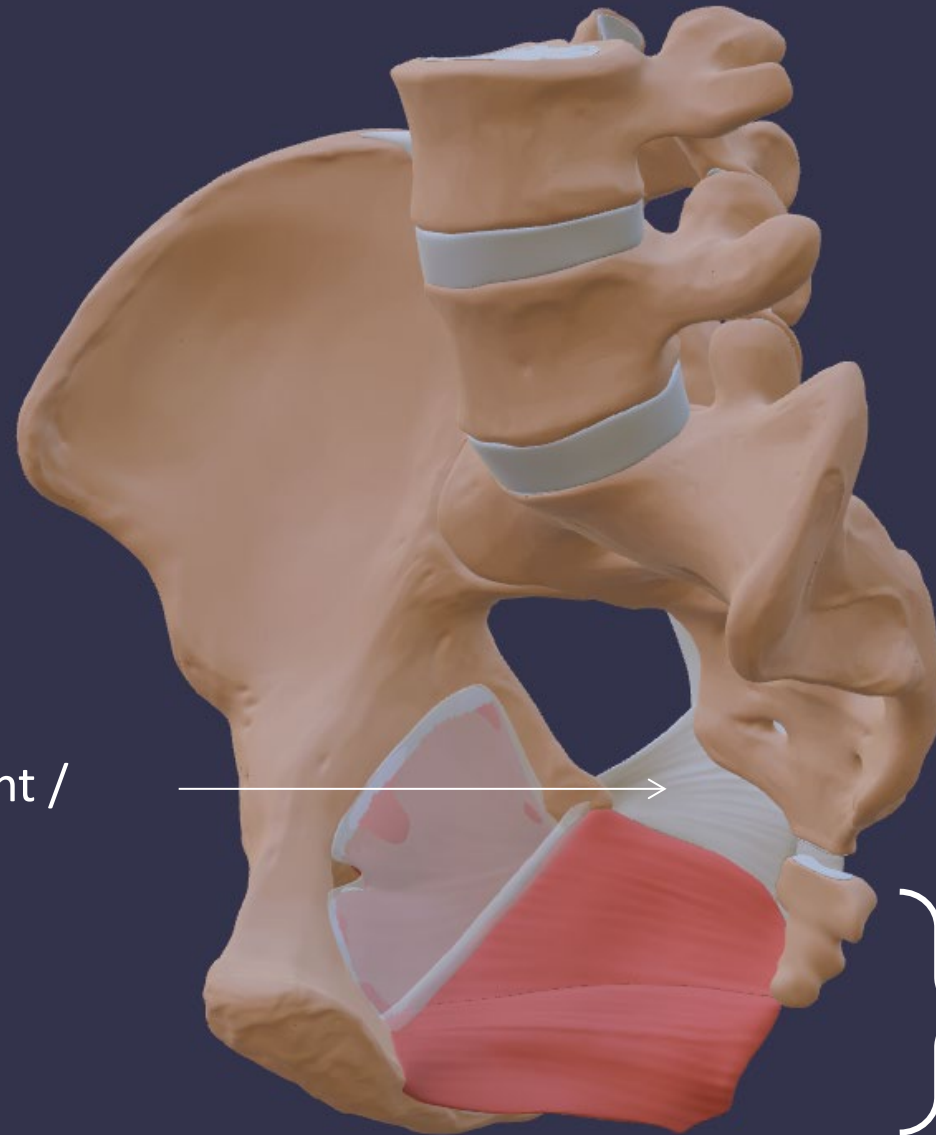
Levator ani /
m. levator ani



Muscles

(medial view)

Sacrospinal ligament /
lig. sacrospinale

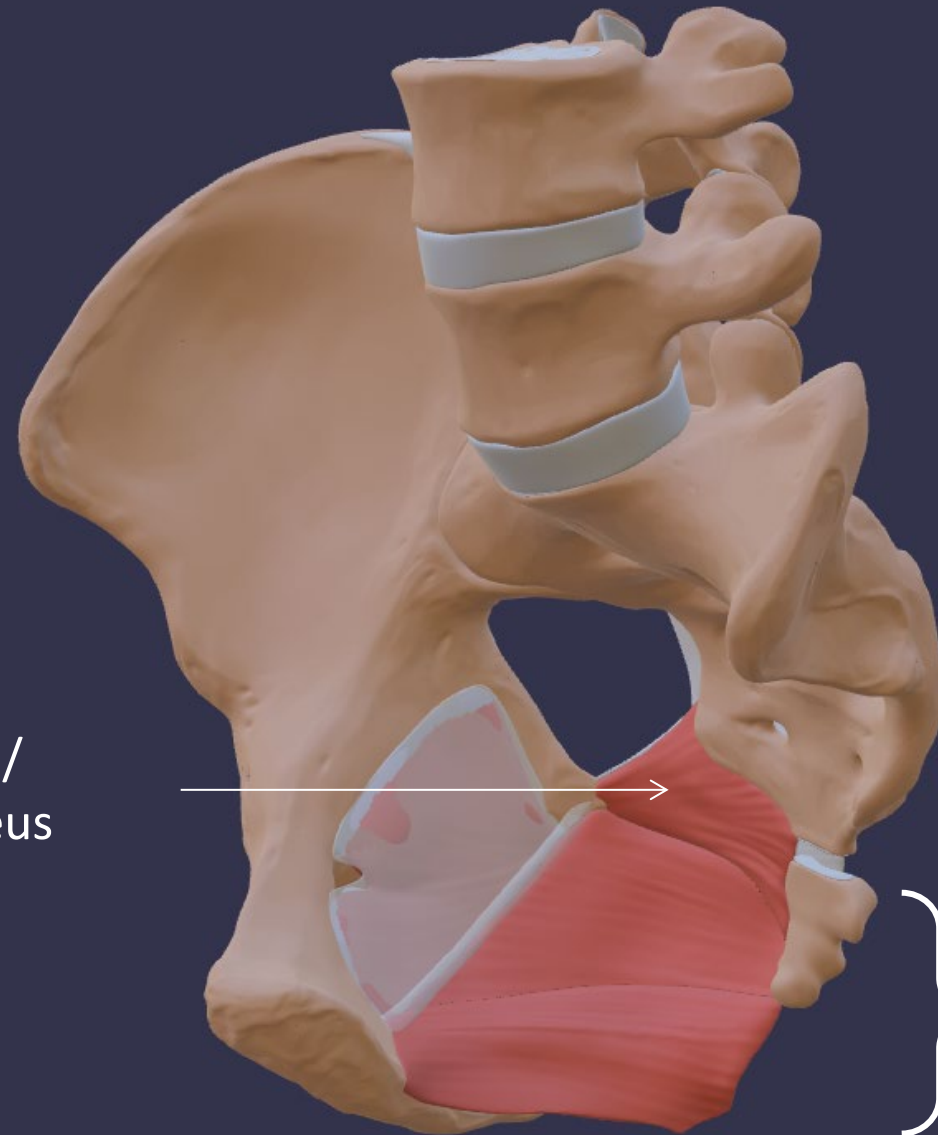


Levator ani /
m. levator ani



Muscles

(medial view)



Coccygeus /
m. coccygeus

Levator ani /
m. levator ani

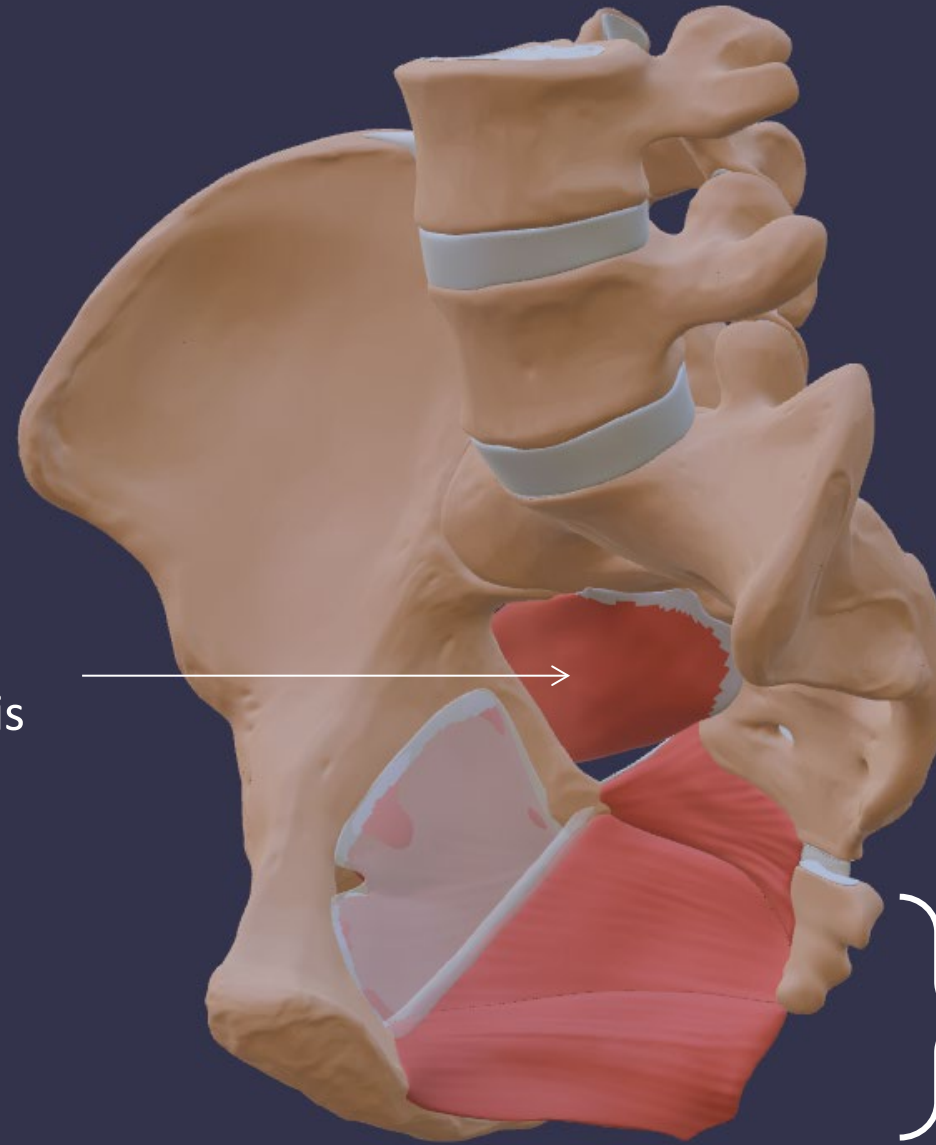
Pelvic
diaphragm /
Diafragma
pelvis /
Bekken
bodem



Muscles

(medial view)

Piriformis /
m. piriformis



Levator ani /
m. levator ani

Pelvic
diaphragm /
Diafragma
pelvis /
Bekken
bodem



Muscles

- Piriformis / m. Traverses greater foramen ischiadicum
- Obturator internus / m. obturator internus Traverses lesser foramen ischiadicum
- Both attach to lesser trochanter / trochanter of femur
- Exorotate lower limb
- Keep femoral head in acetabulum
- Piriformis / m. also abducts lower limb

Video at <https://anatomyopen.org/video-pelvis-obturator-muscles-rotating>

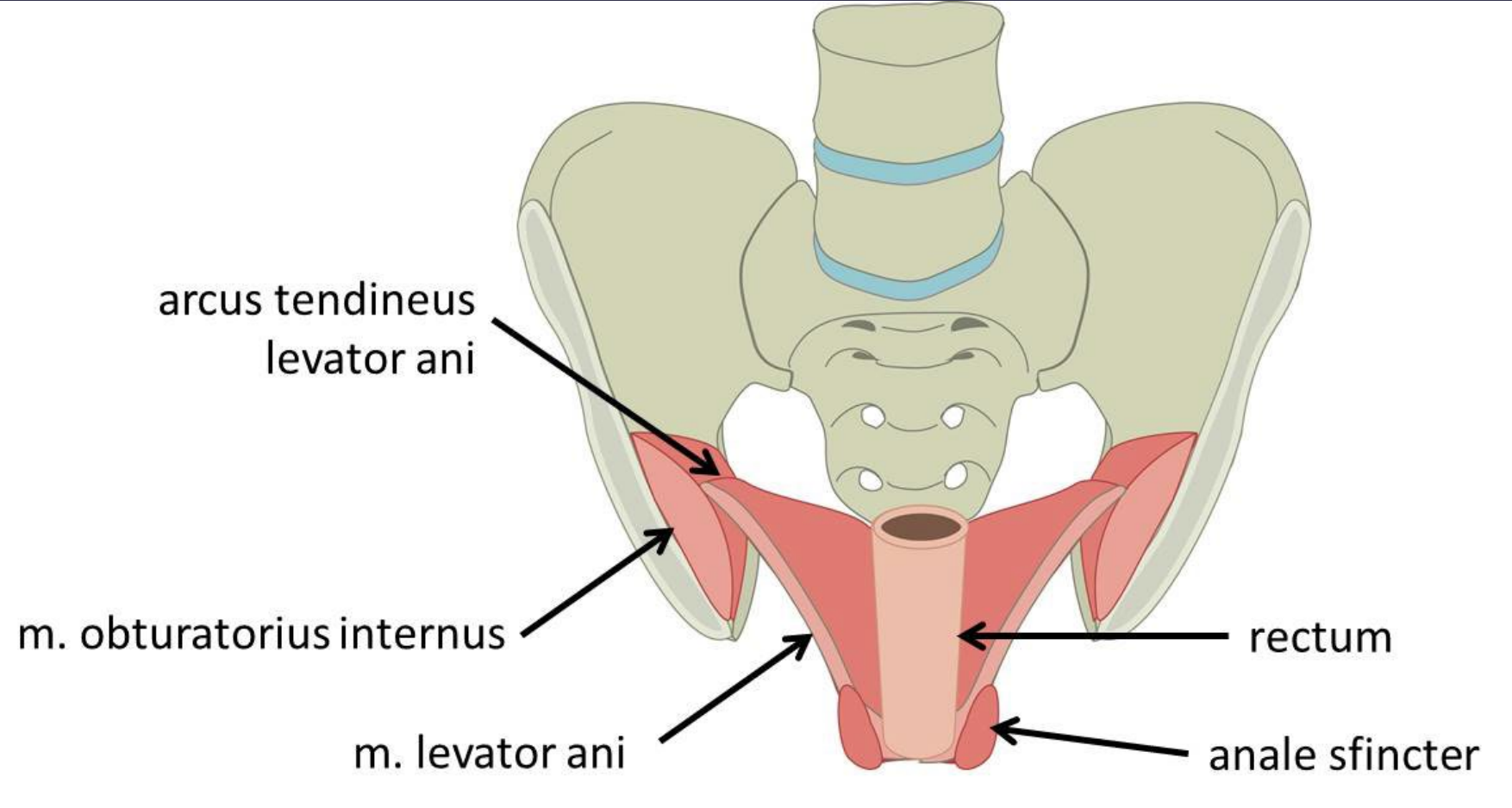




*Levator ani / M.
Obturator internus
Viewed from above*

Video at:
<https://anatomytool.org/content/pelvis-pelvic-floor-seen-above-pudendal-canal>





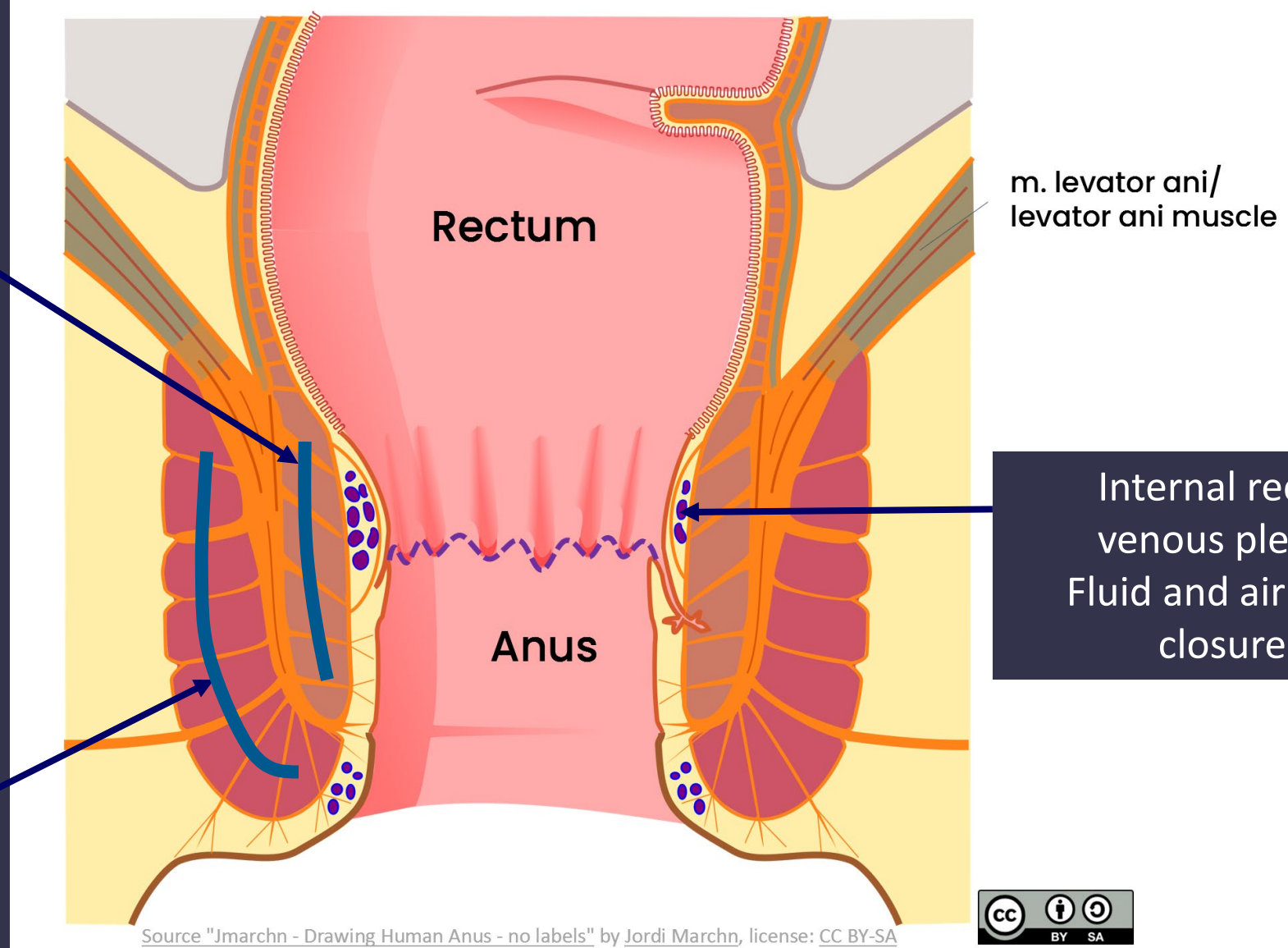
Fecal continence

Which muscles contract and which muscles relax during defaecation?



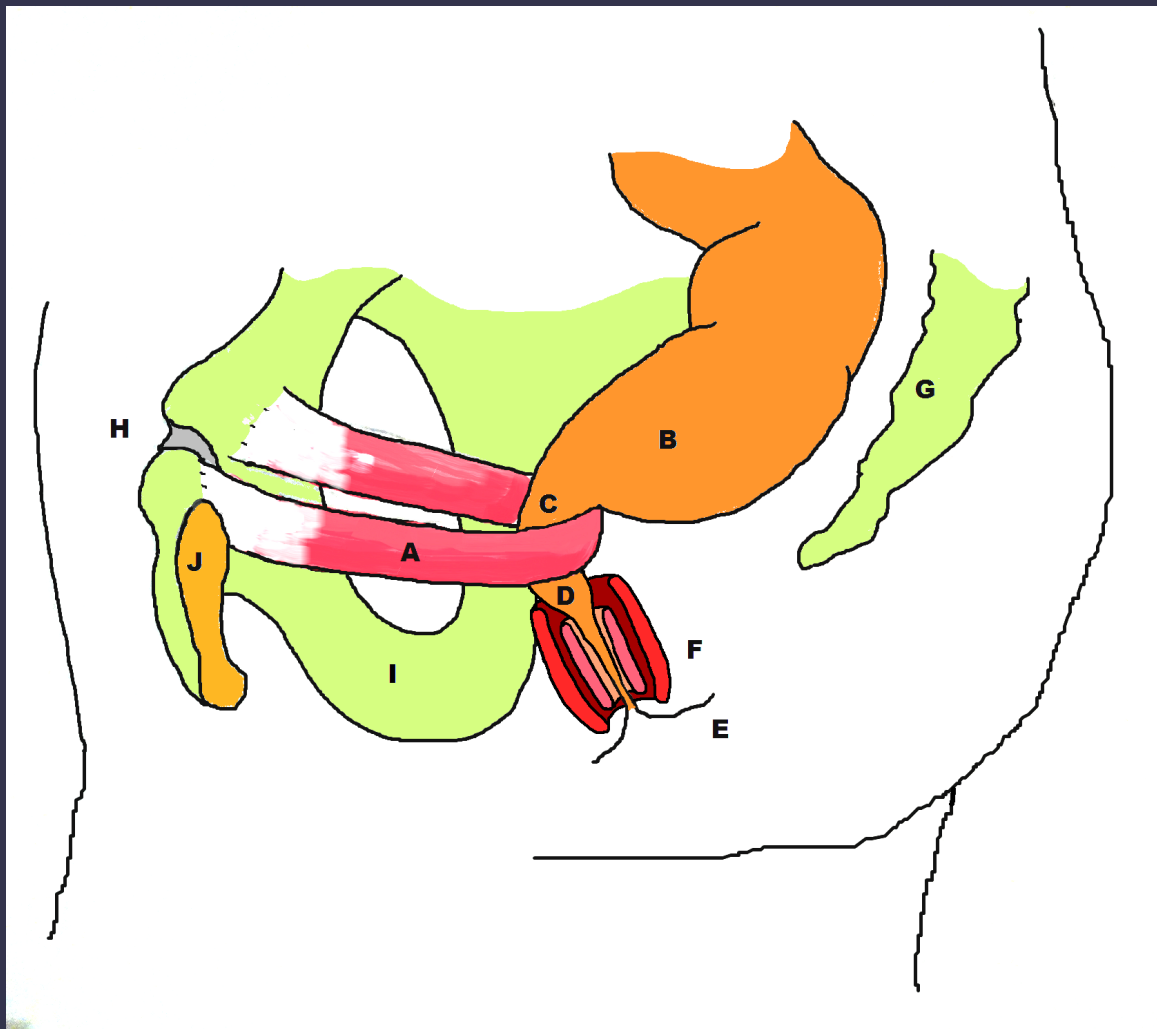
Internal anal sphincter /
m. sphincter ani internus
Continuous tone,
unconscious

External anal sphincter /
m. sphincter ani externus
Intentional contraction



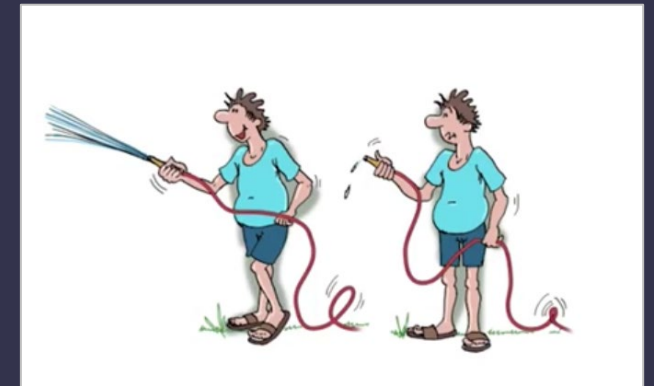
m. levator ani/
levator ani muscle

Internal rectal
venous plexus
Fluid and air tight
closure



Puborectalis / m. puborectalis (part of levator ani):
Continuous tone; draws recto-anal junction anteriorly,
kinking the recto-anal 'route': adds to continence

Compare with kinking of garden hose

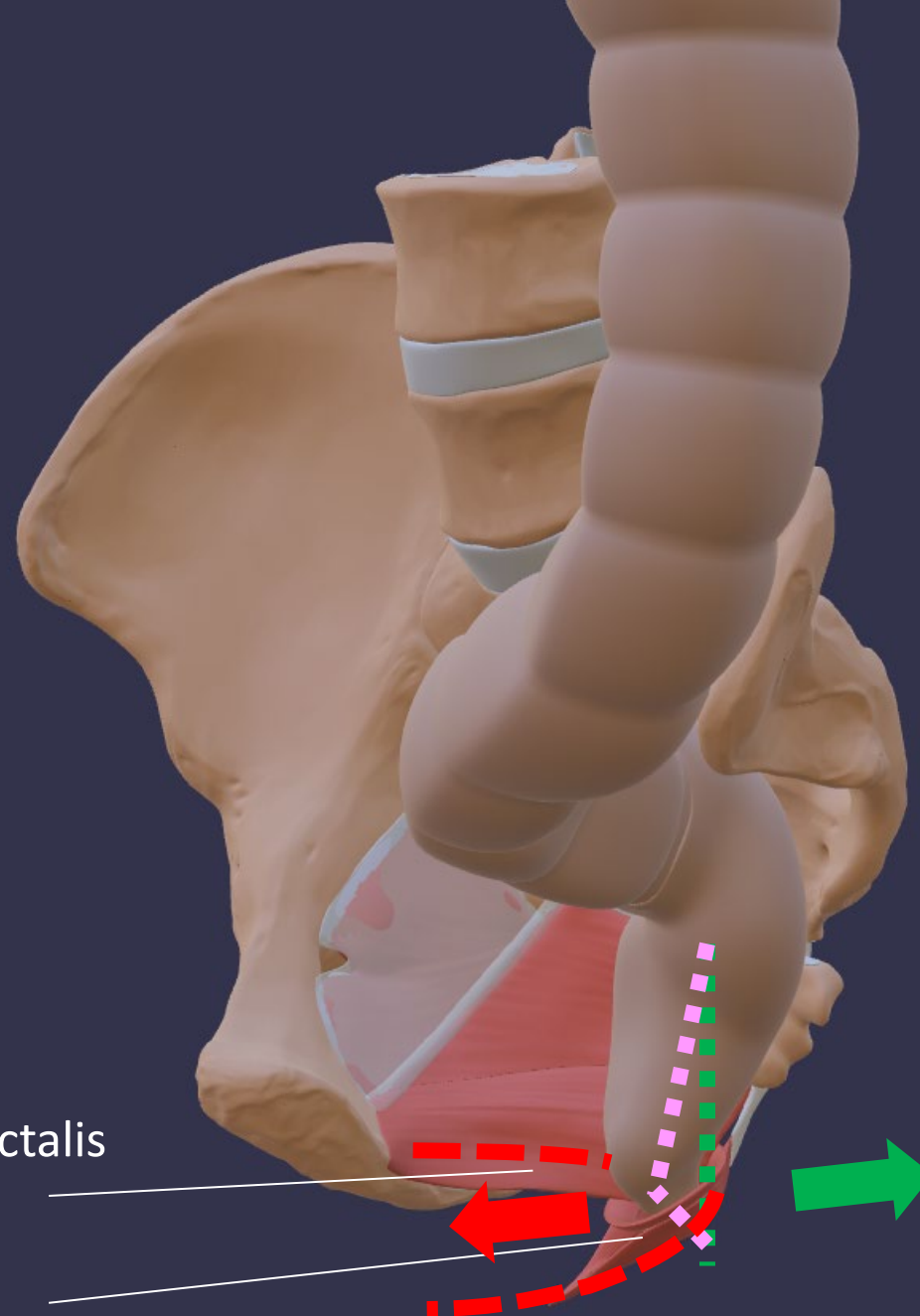


Continenence

(medial view)

Puborectalis / levator ani and external anal sphincter can be intentionally (but short-lasting) contracted to maintain continence.

Puborectalis / levator ani and external anal sphincter must be relaxed to defaecate.



Puborectalis / m. puborectalis
(part of levator ani)

External anal sphincter /
externe anale sphincter

