

# Schema Autonome zenuwstelsel



Truncus sympathicus  
(paravertebraal)

Nn. vagi, plexus oesophagealis,  
truncus vagalis ant. & post.

Cardiopulmonale splanchnische  
zenuwen

Nn. intercostales (spinaal)

Rami communicans

Thoracale splanchnische zenuwen:  
N. splanchnicus major, minor, imus

Prevertebraal / preaortaal:  
ganglion & plexus coeliacus, mesent. sup,  
aorticorenalis, intermesentericus, mesent. inf.

Plexus lumbalis, achterste  
buikwandzenuwen (spinaal)  
Lumbale splanchnische zenuwen

Plexus hypogastricus superior

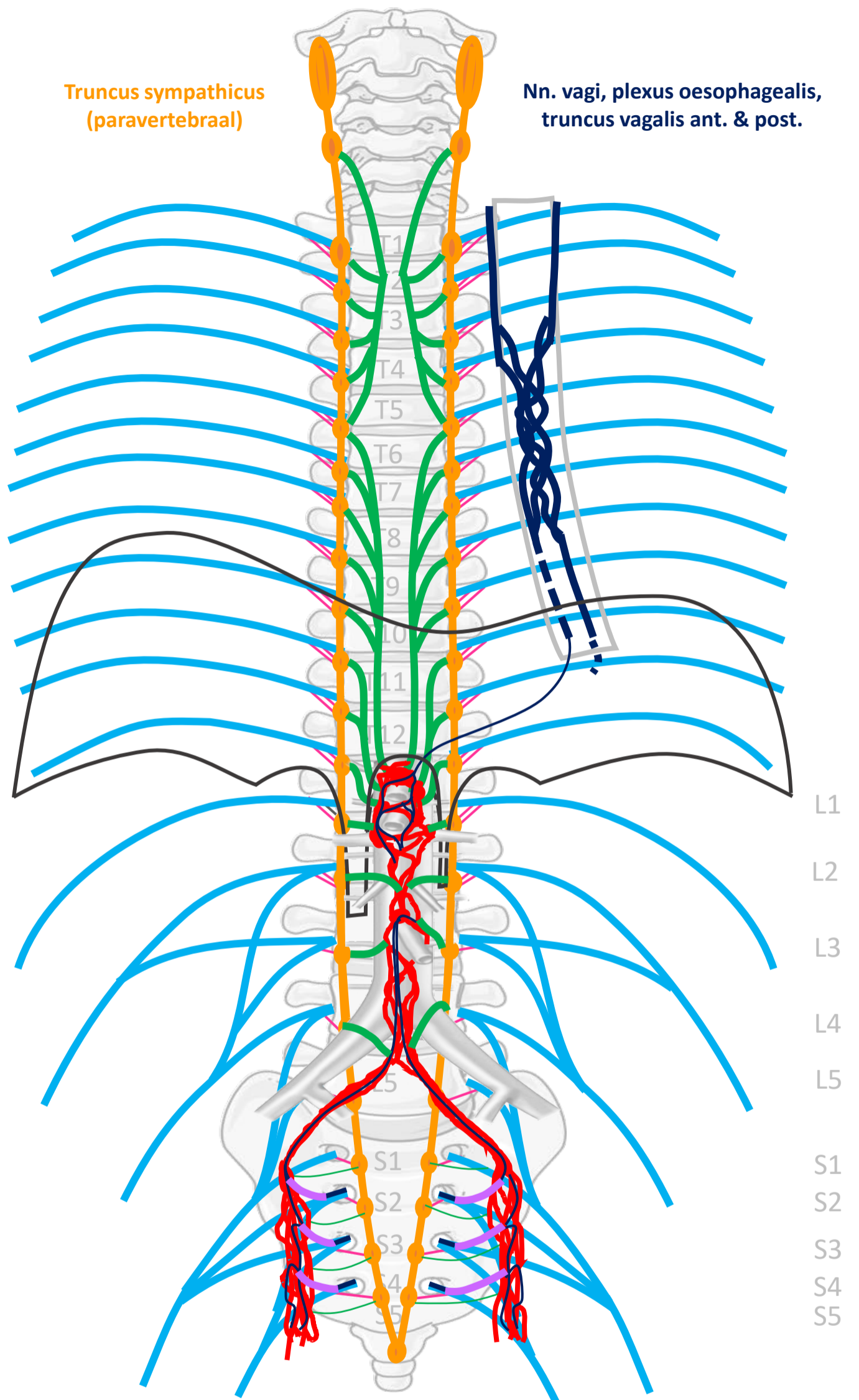
N. hypogastricus

Plexus sacralis, Nn. sacrales (spinaal)

Pelviene splanchnische zenuwen

Plexus hypogastricus inferior

Sacrale parasymp. outflow



SYMP

CZS

PARASYMP

Rami  
communicans  
Splanchnische  
zenuwen

Spinale zenuwen

Paravertebraal (truncus sympathicus)

Pelviene  
splanchnische  
zenuwen

N. vagus

Prevertebraal / preaortaal

ORGAAN

Download dit schema



v. 3, March 2024

By Paul Gobée, dept. Anatomy & Embryology, LUMC license CC BY NC SA

Bronnen: Gray's Anatomy 41<sup>st</sup> ed., Moore K et al, Clin. Oriented Anatomy, 8<sup>th</sup> ed.

"Servier - Drawing Vertebral column anterior view - no labels" by Servier Medical Art, license: CC BY

"Branches of the abdominal aorta - English labels" by Open Learning Initiative, license: CC BY-NC-SA

